

## Effect of Cefotaxime Administration on the kidney, liver and Lung of Swiss white Mice (mus musculus)

Asraa Abed Jazaa

Department of Biology ,College of Education for pure sciences, Tikrit University Tikrit , Iraq  
esraa.abed@tu.edu.iq

### Abstract

The present study was designed to monitor the impact a drug such as cefotaxime has on the histological architecture of the kidney, liver and Lung on Swiss white mice.

The experiment was designed by using 30 Swiss white mice from both sexes.

- Mice were classified randomly into three groups:

**Group A:** Control Group, injected intramuscularly with 0.5ml distilled water daily for 6 days.

**Group B:** Therapeutical Dose, Injected intramuscularly with 0.1 ml cefotaxime daily for 6 days.

**Group C:** Extra Therapeutical Dose, Injected with 0.2 ml cefotaxime daily for 6 days.

At the end of the experimental period, the kidney, liver and lung of the mice were taken and processed for histological study.

The behavioral results showed a lower appetite and decrease in weight in the mice present in Group C.

Histologically, the kidney and liver showed numerous abnormalities at the end of the treatment period compared to that of the control group.

Pyknosis, Karyohyxis and Karyolysis were found in the liver cell nuclei.

While infiltration of the lymphocytes was present. Necrosis of the hepatocytes were observed clearly throughout the tissue present in the lung.

Renal convoluted tubules show atrophy and necrosis of cell with hypertrophy of glomeruli.

Degeneration and shrinkage of the renal tubule cells with the appearance of pyknosis of nuclei was also found.

Due to these destructive results on the liver and kidney cells it was concluded that cefotaxime caused many cell abnormalities and dysfunction in general.

**Key words:** claforan, Cefotaxime, Histology, Therapeutical Dose, Extra Therapeutical Dose, Kidney, Liver, Lung, Lymphocytes, Hepatocytes

### 1. Introduction

CLAFORAN (cefotaxime) is a semi-synthetic antibiotic widely used for different types of inflammation. CLAFORAN solutions range from very pale yellow to light amber which depends on the concentration and the diluent used. The pH of Cefotaxime solutions ranges from 5.0-7.5 slightly acidic to neutral composition (1).

Claforan is supplied as a dry powder in appearance . It is a broad-spectrum antibiotic with activity against numerous gram-positive and gram-negative bacteria in the body and comes as a solution for injection to be administered by a healthcare provider into the vein or muscle. Hoechst-Roussel was the Pharmaceuticals that developed this drug in the late 1980s, It is on the World Health Organization's List of Essential Medicines, the most important medications needed in a basic health system (2).

A variety of infections are treated with Cefotaxime such as:

- Lower respiratory tract infections
- urinary tract infections
- Gynecologic infections
- Bacteremia/septicemia
- Intra-abdominal infections
- Bone and joint infections
- Central Nervous System Infections
- Skin Infections (3)(1)

Cefotaxime antibiotic is active against many Gram-positive and Gram-negative bacteria. Cefotaxime typically is effective against these organisms (in

addition to many other). (4)As many drugs common side effects or reactions experienced can be found such as:

- Pain and inflammation at the site of injection (4.3%)
- Rash, pruritus, or fever (2.4%)
- Colitis, diarrhea, nausea, vomiting (1.4%)(5)

Cefotaxime, such as other anti-infective drugs, may cause irritation to tissues, It could result in tissue damage and require surgery to treat its effect. Leukopenia, neutropenia, granulocytopenia and even other rare affects such as pancytopenia, or agranulocytosis may develop during treatment with injected Cefotaxime. (6)

Physicians and veterinarian should be aware to the alterations caused by these drugs while treating infections such as changes in some biochemical parameters, to avoid incorrect diagnosis. This study in addition to other Studies mentioned in this research has shown that chronic administration of cefotaxime in high doses may cause severe damage to the kidney, Liver and Lung.

### 2. Aim

The aims of this study are:

1. To observe and show the histological changes on certain tissues and cells in specific organs such as the Kidney, Liver and Lung of mice treated with Cefotaxime.

2. To compare the drug dose on the tissue of Kidney, Liver and Lung, Therapeutically and Extra Therapeutically.

### 3. Material & Methods

#### Experimental Design

The mice were divided randomly into three groups, two groups were injected intramuscularly in the thigh with Cefotaxime powder dissolved in distilled water to be injected directly.

Mice were injected daily for 6 days in a row at 4 pm.

**Table(1): The experimental design**

Group	Dose (mg/kg)	Duration	No. of Mice
A	D.W	6 Days	10 mice
B	0.1 ml	6 Days	10 mice
C	0.2 ml	6 Days	10 mice

Group A mice were injected with 0.5 ml of distilled water in the same manner, while Group B were injected with 0.1 ml and Group C with 0.2 ml (7).

#### Histological technique

The mice were killed using chloroform in a closed glass box to insure no ventilation. Kidney, Liver and Lung were obtained after dissecting the animal under aseptic conditions.

**Histological technique carried out according to Bancroft & Stevens (1987) method as following:**

#### 1. Fixation

Organs after removal were fixed in 10% neutral buffered formalin solution (10ml of 40% formaldehyde + 90 ml tap water) for 22 hours at room temperature.

#### 2. Dehydration

Organs were removed from the formalin and washed under running tap water for about 30 min. Then passed through progressively graded concentrations of alcohol baths (50%-70%-80%-90 and 100%). 1 hour in both 80% and 90% whilst 1/2 hour in two changes of absolute alcohol.

#### 3. Clearing

Two changes of Xylene for 30 min. each, to insure the removal of any traces of alcohol. This led to some degree of transparency.

#### 4. Infiltration and Embedding

Tissues were passed a mixture of xylene and molten paraffin wax (58°C) for 30min. Later stainless steel containers were used for creating labeled blocks.

#### 5. Tissue Sectioning

Rotary Microtome (LKB-U.K.) with 6 micrometer thickness ( $\mu\text{m}$ ). ribbons were put in a warm bath 44 °C (Ahmed, 2010).

#### 6. Tissue Attachment

Mayer's glycerol-albumin was smeared over the slides this mixture was used as a preservative agent.

#### 7. De-waxing and Hydrating

De-waxing was made by two changes of Xylene for 20min.each and oven. Hydration in descending concentrations of alcohol baths (100%-90%-80%-70%-50%) for 1-2 min. each and washed in distilled water.

#### 8. Staining

Slides were stained with Heamatoxylin for about 10 min. then washed with running tap water then transferred into Eosin Stain for 1 min.

Dehydration in ascending concentrations of 5min. alcohol baths (50%-70%-80%-90%-100%-100%). Slides were finally cleared with xylene.

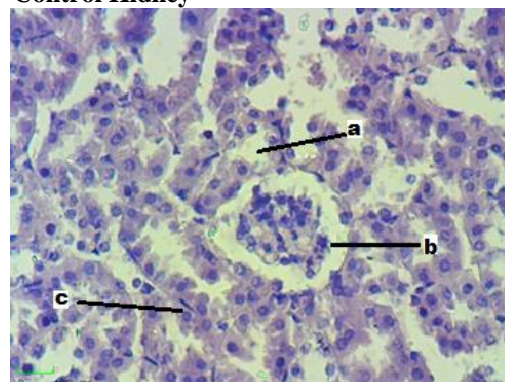
#### 9. Mounting

DPX was used as a mounting agent, and then covered with cover slips.

#### 4. Results

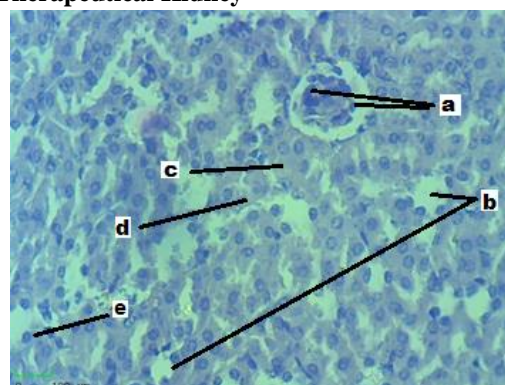
##### 1) Kidney

##### - Control Kidney

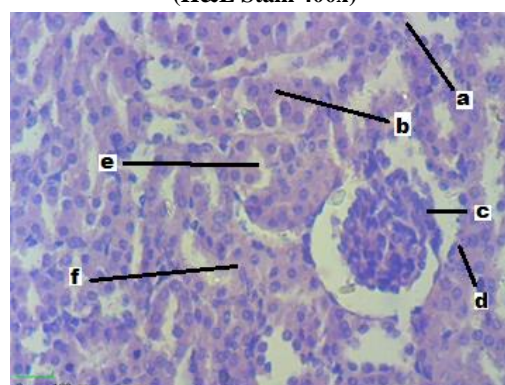


**Fig.(1) Group A, Control Kidney. Proximal Convoluted Tubule (a), Glomerulus (b), Fibrocyte (c). (H&E Stain 400x)**

##### - Therapeutical Kidney



**Fig.(2) Group B, Therapeutical Kidney. Glomerulus Atrophy (a), Urinary Tubule (b), Eosinophilic Substance (c), Necrosis(d), Pyknosis(e). (H&E Stain 400x)**

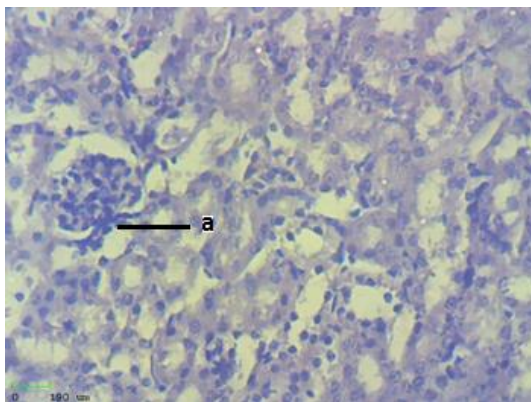


**Fig.(3) Group B, Therapeutical Kidney. Karyolysis(a), Karyorrhexis (b), Glomerulus (c), Capsule(d), Lumen of Urinary Tubule(e), Damaged Tubule (f). (H&E Stain 400x)**

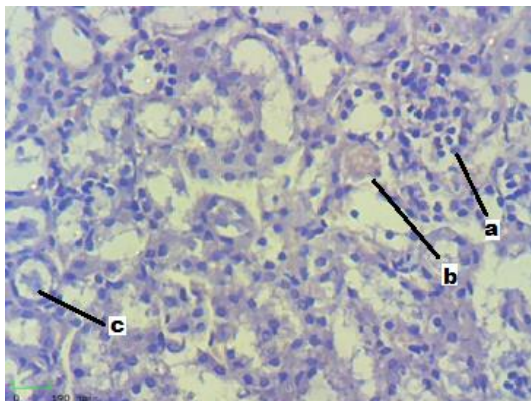


The glomerulus because small in size and the space between the glomerulus and the capsule was very wide, this indication referred to atrophy of glomerulus as in Fig (3), in some regions the glomerulus are segmented as in Fig (3). Many alterations happened to urinary tubules in both proximal and distal tubules including unclear cells arrangement that line the tubules which usually are cuboidal in shape, but here the cells appeared with necrotic cytoplasm and degenerated nucleus (pyknosis, karyorrhexis and karyolysis) in addition to broken of urinary tubules and desquamation of epithelial from the basement membrane and pushed towards the lumen of the tubules with formation of cast in some urinary tubule lumen most epithelial cells become short columnar or columnar causing reducing the lumen of the urinary tubules.

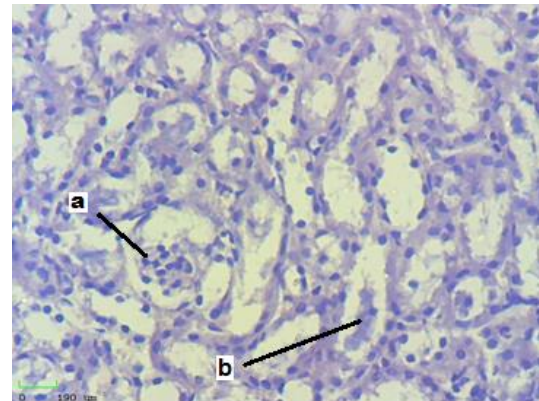
#### - Extra Therapeutical Dose for Kidney



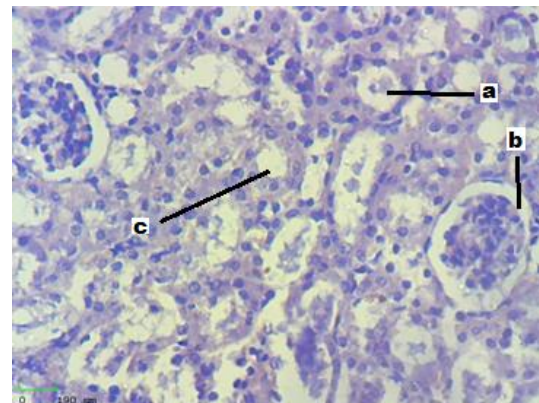
**Fig.(4) Group C, Extra Therapeutical Dose for Kidney. Glomerulus (a). (H&E Stain 400x)**



**Fig.(5) Group C, Extra Therapeutical Dose for Kidney. Glomerulus(a), Cast(b), Cast (c), (H&E Stain 400x)**



**Fig.(6) Group C, Extra Therapeutical Dose for Kidney. Segmented (atrophy) Glomerulosa(a), Cast (b). (H&E Stain 400x)**

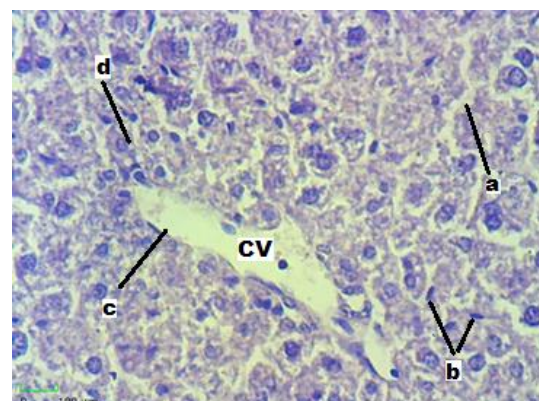


**Fig.(7) Group C, Extra Therapeutical Dose for Kidney. Cast (a), Glomerulus (b), Urinary Tubule (c). (H&E Stain 400x)**

Most tubules epithelial cells got damaged with the formation of cast present in the lumen of some tubules. Very few tubules are in normal size and composition. Glomerulus is segmented with atrophy of its structures.

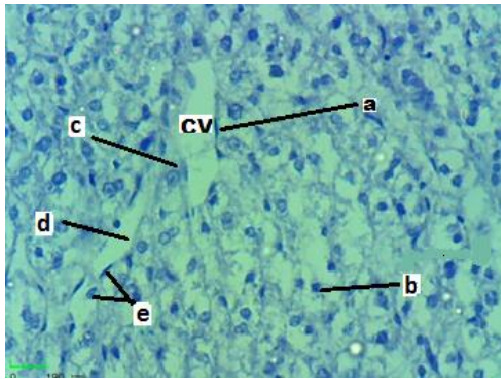
## 2- Liver

### - Control Liver

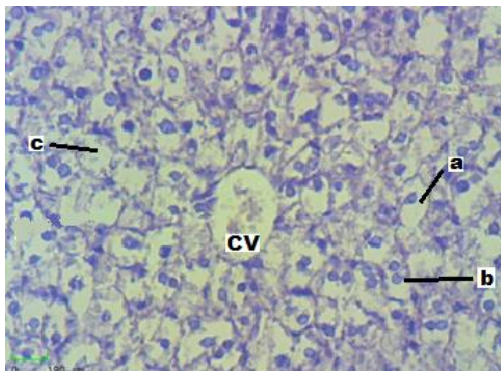


**Fig.(8) Group A, Control Liver. Sinusoid(a), Kupffer cell (b), Hepatocyte (c), Endothelium(d), Central Vein (CV). (H&E Stain 400x)**





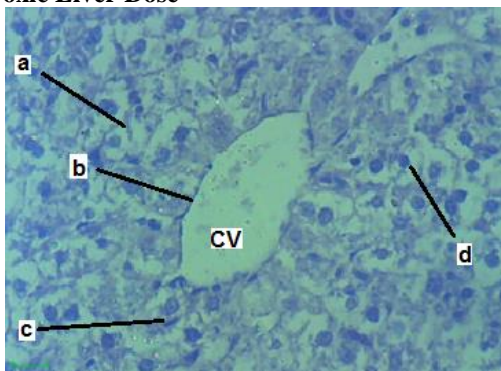
**Fig.(9) Group B, Therapeutical dose for Liver.**  
Endothelium (a), Pyknosis (b), Karyolysis(c),  
Sinusoid(d), Kupffer Cells(e). (H&E Stain 400x)



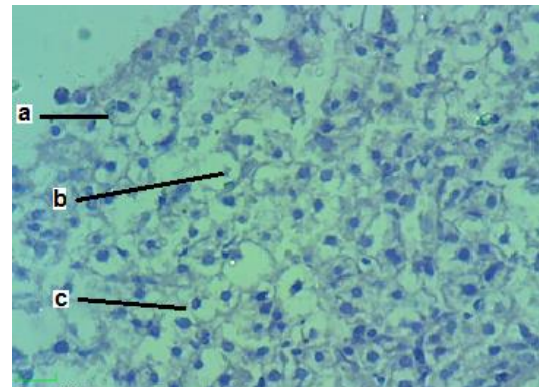
**Fig.(10) Group B, Therapeutical dose for Liver.**  
Necrosis(a), Pyknosis (b), Apoptosis (c).  
(H&E Stain 400x)

Hepatocytes lost their radial arrangement in formation of hepatic cords, so the sinusoids between the hepatic cords did not differentiate and was unclear, most of the cells are swollen due to the absorption of the fluid surrounding it. Large number of cells had suffered from necrotic cytoplasm and apoptosis. The nucleus appeared to go through different stages of degeneration (Pyknosis, Karyorrhexis, Karyolysis). The plasma membranes of most cells are obvious, infiltration of lymphocytes in different liver stroma are seen. Kupffer cells are large in size and in certain places we can see that the sinusoids did not recognize due to the enlargement of hepatic cells, and kupffer cells are limited by two hepatic cord cells.

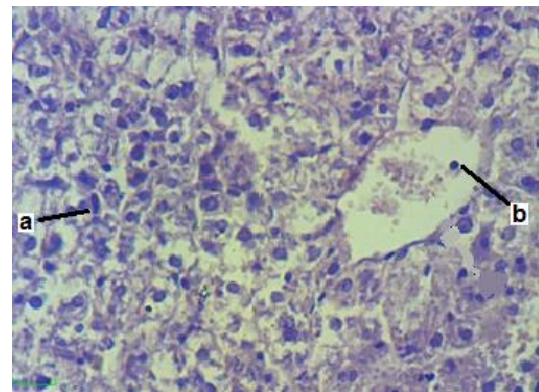
#### - Toxic Liver Dose



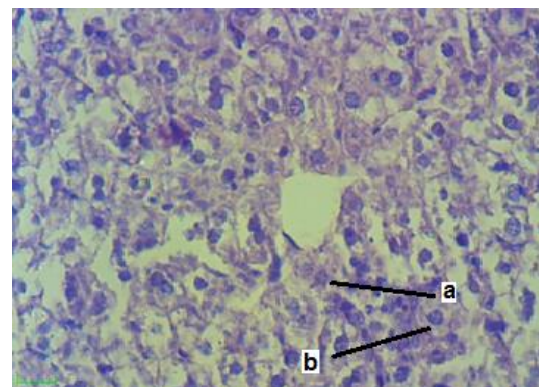
**Fig.(11) Group C, Extra Therapeutical Dose for Liver.**  
Necrosis (a), Endothelium of C.V(b), Kupffer Cells (c),  
Pyknosis (d). (H&E Stain 400x)



**Fig.(12) Group C, Extra Therapeutical Dose for Liver.**  
Plasma Membrane (a), Apoptosis (b), Pyknosis of  
Nucleus (c). (H&E Stain 400x)



**Fig.(13) Group C, Extra Therapeutical Dose for Liver.**  
Kupffer Cells (a)m Infiltration of Lymphocyte (b).  
(H&E Stain 400x)



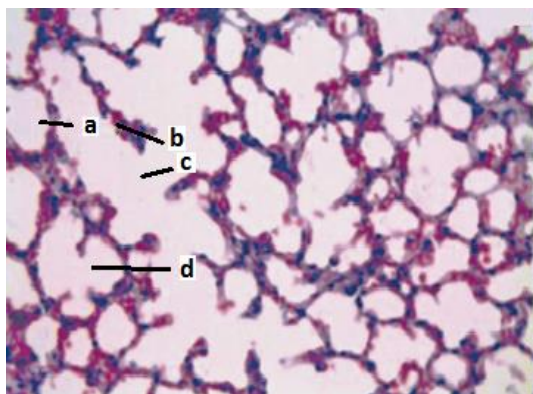
**Fig.(14) Group C, Extra Therapeutical Dose for Liver.**  
Karyolysis (a), Karyorrhexis (b).  
(H&E Stain 400x)

Most of the cells enlarged in size, different stages of degeneration in the nucleus (Pyknosis, Karyorrhexis, Karyolysis).

#### 3- Lung

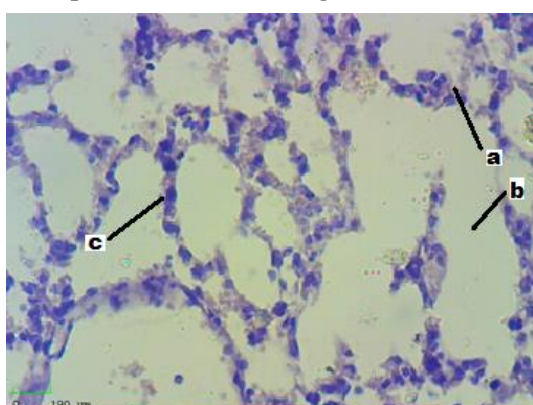
##### - Control Lung



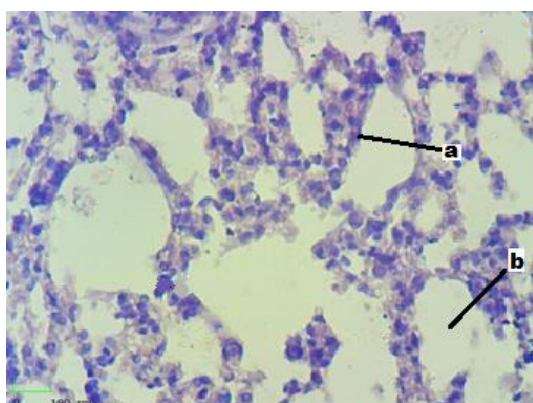


**Fig.(15) Group A, Control Lung. Alveoli (a), Alveolar Wall (b), Alveolar Duct (c), Alveolar Sac (d). (H&E Stain 400x)**

#### - Therapeutical Dose for Lung



**Fig.(16) Group B, Therapeutical Dose for Lung. Hyperplasia(a), Alveoli(b), Wall of Alveoli(c). (H&E Stain 400x)**

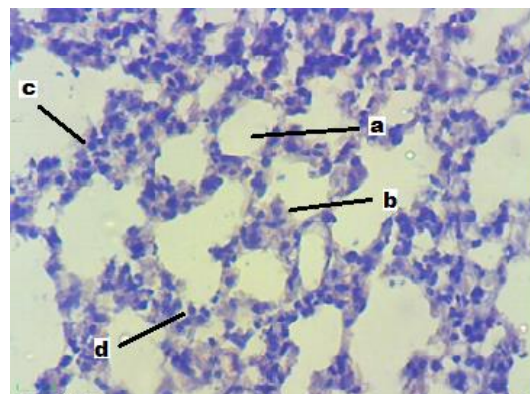


**Fig.(17) Group B, Therapeutical Dose for Lung. Hyperplasia(a), Alveoli (b). (H&E Stain 400x)**

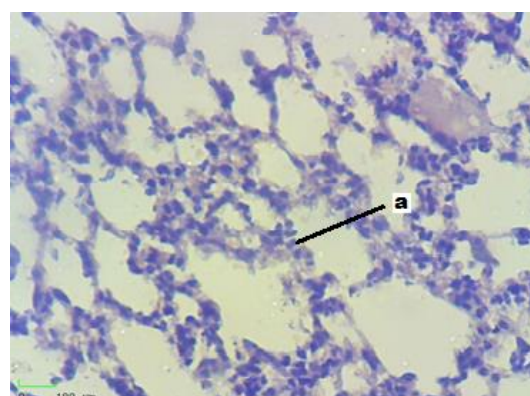
The presence of hyperplasia can be recognized in this dose, which caused thickening of the alveolar wall that composed simple squamous epithelia at normal conditions.

This thickening caused a reduction of the alveoli lumen and caused also accumulation of mucous material on the surface of the cells of the alveoli. Sometimes hemorrhage can be seen in certain places in the lung but other parts showed normal cell shape.

#### - Extra Therapeutical Dose for Lung



**Fig.(18) Group C, Extra Therapeutical Dose for Lung. Alveoli(a), Eosinophilic Substance (b), Hyperplasia (c), Inflammatory Cells (Lymphocyte) (d). (H&E Stain 400x)**



**Fig.(19) Group C, Extra Therapeutical Dose for Lung. Inflammatory Lymphocyte (a). (H&E Stain 400x)**

The increase and thickening of the wall was noticed and additional cells (epithelial cells), hyperplasia and infiltration of lymphocytes that formed a thick wall in the stroma on the lung.

### 5. Discussion

Claforans antibacterial action results from inhibition of cell wall synthesis. It is stable against the action of most  $\beta$ -lactamases. Due to its attack mechanism on bacterial cell wall synthesis,  $\beta$ -lactams are considered to be bactericidal. (1)(4)

Cefotaxime could be intramuscular injected (IM) or intravenous infused (IV). Doses should be adjusted according to the patient's renal or hepatic impairment due to cefotaxime metabolism to active and inactive metabolites by the liver and excreted in the urine in very high levels.(8)

This is an indication to the high impact this drug has on both kidney and liver in the body and an explanation for its huge effect on their cells.

Cefotaximes histopathological effects on the kidney, Lung and liver were shown in the Results. The liver and kidney showed vacuolar degeneration of the hepatocytes with the appearance of infiltration of the lymphocytes and necrosis of the hepatocytes. The kidney showed inter-tubular hemorrhage with necrosis of some renal tubules, this was in correlation to a study (11) showing similar results found in both the kidney and liver of adult rats treated with

Cefotaxime over 7 days. Other studies (12)(13) also found that ceftriaxone therapy associated with elevated liver enzymes in rats after IM injections and obtained biochemical changes attributed to damage to hepatocytes and renal tubule cells, these biochemical changes and results obtained was in agreement with this study.

The histopathological findings in kidneys of cefotaxime treated mice obtained in this study were consistent with those obtained in a study (14) that observed cephaloridine administration to rats caused degeneration and necrosis of the renal proximal tubular epithelia. Finally another study (15) observed the drugs alteration on the renal proximal tubular causing changes such as necrosis, hyaline cast and calcification, suggesting renal disorders, this was in correlation with the present study as well and shows

## 7. References

1. Renaud, (2014). CLAFORAN, Version 6.0. Sanofi-aventis Canada Inc. 2905 Place Louis-R. Renaud, Laval, Quebec H7V 0A3
2. "WHO Model List of Essential Medicines" (PDF). World Health Organization. October 2013.
3. Scriabine A. (1999). Pharmaceutical Innovation: Revolutionizing Human Health. Pennsylvania: Chemical Heritage Foundation. p. 169.
4. Simmons BP, Gelfand MS, Grogan J. (1995). *Cefotaxime twice daily versus ceftriaxone once daily. A randomized controlled study in patients with serious infections. Diag. Microb. & Inf. Dis.* 22 (1–2): 155–7.
5. U.S. Food and Drug Administration. U.S. Department of Health and Human Services. Claforan Sterile (cefotaxime for injection, USP) and Injection (cefotaxime injection, USP). 19 June 2009.
6. Peker E, Cagan E, Dogan M. Ceftriaxone-induced toxic hepatitis. *World J Gastroenterol* 2009;15:2669–71.
7. Riviere J., Papich M. & Adams H., (2011). *Veterinary Pharmacology and Therapeutics*. (9<sup>th</sup> ed.) Wiley-Blackwell, A John Wiley & Sons Inc., Publication. USA.
8. Scholz H., Hofmann T., Noack R. (1998). *Prospective comparison of ceftriaxone and cefotaxime for the short-term treatment of bacterial meningitis in children*. US National Library of Medicine Microbiology and Hygiene, Berlin, Germany.
9. Woodfield JC, Van Rij AM, Pettigrew RA, (2003). *A comparison of the prophylactic efficacy of*

the great impact of Cefotaxime on a cellular level or organization.

## 6. Conclusion

In conclusion, drug utilization such as cefotaxime has a great impact on the cells of liver, kidney and Lung causing cells and tissue structure to be altered severely.

Cetotaxime showed its effect on many body organs and tissue so it should be taken in consideration that such drug should be taken according to age and type of inflammation in the body to protect them from its significant impact. Cefotaxime had caused hepatic and renal histopathological cellular alterations; hence Cefotaxime should not be taken by choice whether used on animals or patients suffering from hepatic and renal disorders.

*ceftriaxone and cefotaxime in abdominal surgery. Amer. J. Surg.* 185 (1)

10. Gums JG, Boatwright DW, Camblin M, (2008). *Differences between ceftriaxone and cefotaxime: microbiological inconsistencies. The Annals of Pharmacotherapy* 42 (1): 71–9. Coombes JD (1982). "Metabolism of cefotaxime in animals and humans". *Reviews of Infectious Diseases* 4 (Suppl 2): S325–32.
11. Ahmed T.S. (2010). Histological characteristics of thyroid gland induced by carbimazole in albino mice *Mus musculus* and their pups. Tikrit, Iraq. pp:83-89
12. Eroschenko V., (2005). *Atlas of Histology*. 10<sup>th</sup> Edition, Lippincott Williams & Wilkins. USA.
13. Elsayed MG, Elkomy AA, Aboubakr MH. Hepatotoxicity evaluation in albino rats exposed to ceftriaxone. *Asian J Pharm Biol Res* 2011;1:145-50
14. Peker E, Cagan E, Dogan M. Ceftriaxone-induced toxic hepatitis. *World J Gastroenterol* 2009;15:2669–71.
15. Soliman A. Hepato-renal effect of cefotaxime in albino rats. Department of Pharmacology, Faculty of Veterinary Medicine, Cairo University, Cairo, science Journal. 2015.
16. Hayashi T, Maruden A, Irimura K. Nephrotoxicity of cefodizime sodium in rats-single and 14-day repeated intravenous administration. *J Toxicol Sci* 1988;13:285-327. 36.
17. Effect of cefodizime sodium on the kidney function in male rabbits single and 7-day repeated intravenous administration. *J Toxicol Sci* 1988;13: 329-60.

## تأثير تناول عقار السيفوتوكسيم على أنسجة الكلية، الكبد، والرئة في الفئران البيض السويسرية

إسراء عبد ذياب

قسم علوم الحياة ، كلية التربية للعلوم الصرفة ، جامعة تكريت ، تكريت ، العراق

[esraa.abed@tu.edu.iq](mailto:esraa.abed@tu.edu.iq)

### الملخص

صمم هذا البحث لدراسة تأثير دواء السيفوتوكسيم على أنسجة أعضاء الفئران البيضاء السويسرية كالكلية، الكبد والرئة. صممت التجربة باستخدام 30 فأر أبيض اللون من كلا الجنسين حيث تم تصنيفهم عشوائياً إلى ثلاثة مجاميع رئيسية:

- المجموعة A: (مجموعة السيطرة) حقنت في داخل العضلة بجرعة 0.5 مل من الماء مرة واحدة يومياً وعلى مدة 6 أيام.
- المجموعة B: (الجرعة العلاجية) حقنت في داخل العضلة بجرعة 0.1 مل من السيفوتوكسيم يومياً وعلى مدار 6 أيام.
- المجموعة C: (الجرعة العلاجية الزائدة) حقنت في داخل العضلة بـ 0.2 مل من السيفوتوكسيم وعلى مدار 6 أيام.

في نهاية الفترة المخصصة للتجربة تم تشريح الفئران لاستخلاص الأعضاء ودراستها بعد إجراء التقنية النسيجية عليها. كان هناك تغيرات سلوكية أظهرت فقدان الشهية ونقص في الوزن للفئران الموجودة في المجموعة العلاجية الزائدة. نسيجياً أظهرت الكلية والكبد والرئة عدة تغيرات غير طبيعية مقارنة مع مجموعة السيطرة وعلى ضوء هذه النتائج لوحظ التأثير الكبير لهذا العقار على الخلايا المختلفة وما أدى إليه من اختلالات غير طبيعية في الأعضاء بشكل عام.