



The effectiveness of the protective role of beetroot juice for the male reproductive system of albino rats against the toxicity of cadmium chloride

Qasim Azeez Razooqi AL-Janabi, Rashid Khamees Shaban, Noor Ibrahim Hasan AL-Kraie

College of Education for Pure Sciences, Tikrit University, Tikrit, Iraq

<https://doi.org/10.25130/tjps.v24i1.328>

ARTICLE INFO.

Article history:

-Received: 6 / 8 / 2018

-Accepted: 30 / 9 / 2018

-Available online: / / 2019

Keywords: Sperms, Cadmium chloride, Beetroot juice

Corresponding Author:

Name: Qasim Azeez Razooqi

E-mail:

Qasimrazooqe80@yahoo.com

Tel:

ABSTRACT

This study was designed to evaluate the protective role of beetroot juice against the toxicity of cadmium chloride (CdCl_2) in male albino rats.

The study included 20 male albino rats ages ranged between (2-3 months) and weights ranged between (220-260g), which were randomly distributed into 4 groups, the first group that has been promised to control group was given distilled water, the second group was given beetroot juice 10 ml/kg b.w., group third was given at a dose of cadmium chloride 5 mg/kg b.w. for 30 days, which promised an infected control, and the fourth group were treated beetroot juice 10 ml/kg b. w. with cadmium chloride.

The results showed that the treatment of animals cadmium chloride led group to a significant decrease ($P \leq 0.05$) in the hormonal serum, to negative effects on of the natural shape of the sperm and to negative effects cleared on histological in testes tissues compared with the control group, In general has dosage rats treatment cadmium chloride juice of beetroot, to the positive improvement for most of the values of previous indicators has led to increase significantly, the concentration of the LH, FSH and Testosterone hormone, to an improvement in the natural shape of the sperm, decreased significantly in the form abnormal sperm, led to an improvement cleared tissue in these totals became approach with what has been observed in the control group.

1-Introduction

Recently, the reproductive toxicity caused by heavy metal pollution has been a matter of increasing concern. Cadmium, which is one of the most common environmental and occupational metallic toxicants, has also been demonstrated to potentially threaten human health [1-2]. Cadmium is a potent heavy metal carcinogenic to animals[3] and humans[4]. The gonads, ventral prostate, liver and kidney are target sites for cadmium toxicity in rodents[5-6]. It has been reported to exert its genotoxicity via the production of reactive oxygen species and by inhibiting cell proliferation and DNA replication[7].

However, previous studies on cadmium-induced toxicity in the male reproductive system focused more on the interference with spermatogenesis [8], damage to nuclear DNA [9], and causes of apoptosis [10], while the toxicity and mechanisms of cadmium in mature spermatozoa are still unclear.

Beetroots contain a biologically active betalains: Betacyanins and betaxanthins. Betacyanins are red-violet pigments: betanin, isobetanin, neobetainin, betanidin, and isobetanidin, while betaxanthins (red pigments) are represented by vulgaxanthin I and vulgaxanthin II. Rich sources of betacyanins are such plants as beetroot (*Beta vulgaris* L. ssp. *vulgaris*), cactuses of genera *Hylocereus* and *Opuntia*, and many flowering plant species of the family *Amaranthaceae* [11,12].

In addition diverse polyphenols red beetroot contain betalains, a family of non-phenolic and water-soluble anti-oxidants which comprise red betacyanins and yellow betaxanthins [13], other active chemicals, beetroots contain a unique class of water-soluble, nonphenolic antioxidants, the betalains, including two classes of compounds, red betacyanins (principally betanin) and yellow

betaxanthines. The antioxidant effects of betalains have been demonstrated mainly in various in vitro experiments [13].

The beetroot has a role against the toxicity of chemicals that it function induced by carbon tetrachloride (CCl₄) and reduced plasma protein carbonyls and DNA damage in blood leukocytes [14]. Beetroot contains a large amount of pigments such as betaxanthins and betacyanin of the betalain family, a group of water-soluble nitrogen containing pigments derived from betalamic acid and most studies indicate betalains as health protective molecules in beetroots. Betalains are related to anti-oxidative stress, anti-inflammation and antitumor effects of beetroots [15].

2-Material and Methods

2-1-Experimental Design:

Animals were randomly distributed into four groups as follows:

Group 1 –Animals were given distilled water and kept as control.

Group 2 – Animals were given beetroot juice 10 ml / kg b.w. for 30 days[16].

Group 3- Albino rats were treated at a dose of cadmium chloride 5 mg/kg b.w for 30 days, which promised an infected control [17].

Group 4 – Animals were given beetroot juice 10 ml / kg b.w. with cadmium chloride 5 mg/kg b.w for 30 days .

2-2-Preparation Beetroot Juice:

The beetroots were washed with tap water, cut into small pieces. The juice of the freshly chopped beetroots were prepared by an electric blender and then filtered through a stainless steel strainer by sterile gauze, then kept at 4 ° C until use without dilution or addition[16].

2-3-Blood Collection

At the end of each experiment, animals have been fasted for 8 hrs and sacrificed after chloroform

anesthesia . Blood samples have been taken by Heart puncture and allowed to clot. Serum was separated by centrifuging at 2500 rpm for 15 min by using Centrifuge and micropipette then serum were stored in the deep freeze (-45C°).

2-4-Sperm Preparation and Staining

After cutting his right epididymis in alflsli salt (0.9%) waltsbigh A drop of semen solution was taken on a clean, dry glass slide. A similar amount of eosin-necrosin dye was added and then mixed well and spread on the slide to make a small swab to observe the shape of the sperm and its vitality by means of a light microscope .[18]

2-5-Assays for Serum FSH, LH and Testosterone

Serum level of FSH , LH and Total Testosterone have been measured by VIDAS technique using the ELFA technique (Enzyme Linked Fluorescent Assay) The assay principle combines an enzyme immunoassay sandwich method with a final fluorescent detection (ELFA) by using a Biomerieux kit for all of the three hormones [19].

2-6-Histological examination

The tissues for histological examination were fixed in 10% formalin since 24 hours, dehydration by ethyl alcohol in increasing concentrations (70%, 80%, 95%, 100% and 100%), clearing with xylene and then embedded with paraffin. When analyzed, all paraffin-embedded tissue was sectioned at 5 µm ,and stained with Hematoxylin and eosin. These specimens were examined under a light microscope at 40X magnification power. Corresponding digital images were captured for later analysis [20].

2-7-Statistical Analysis

The statistical analysis of the results was carried out by the ANOVA Analysis of Variance. The differences were determined by Duncan's multiple ranges and at a significant level (P≤ 0.05) .

3. Results

3-1 Hormonal variables

parameters Group	LH (mIU/ml)	FSH (mIU/ml)	Testosterone (ng/ml)
Control	3.68 ± 0.22 a	1.82 ± 0.15 a	2.52 ± 0.21 a
beetroot juice	3.36 ± 0.12 a	1.48 ± 0.18 a	2.42 ± 0.14 a
Cdcl2	2.28 ± 0.12 b	0.8 ± 0.14 b	1.32 ± 0.12 b
Cdcl2 + beetroot juice	3.24 ± 0.9 a	1.64 ± 0.16 a	2.64 ± 0.16 a

- Values represent the arithmetic average ± standard error.
- The vertically different letters mean a significant difference at a significant level (P ≤ 0.05).
- Number of animals 5 per group.

3-2- Histological

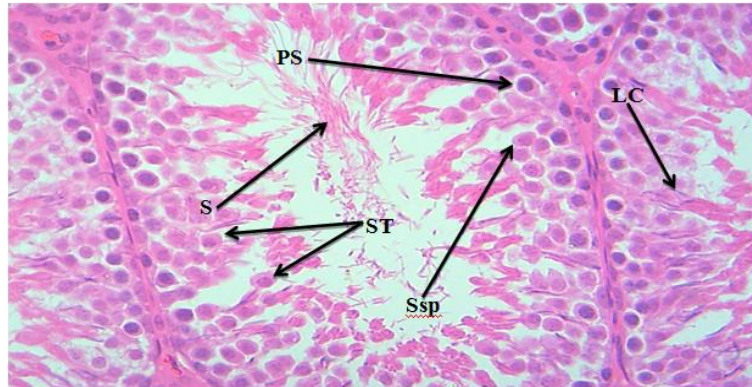


Fig (1) A section in the rat testicle, The control group shows the sperm formation stages within the seminal tubules. The primary spermatocyte (PS), the secondary spermatocyte (Ssp) and the spermatid (ST) appear as the mature sperm (S) And the possibility of observing the Leydig cells (LC) H & E 400X.

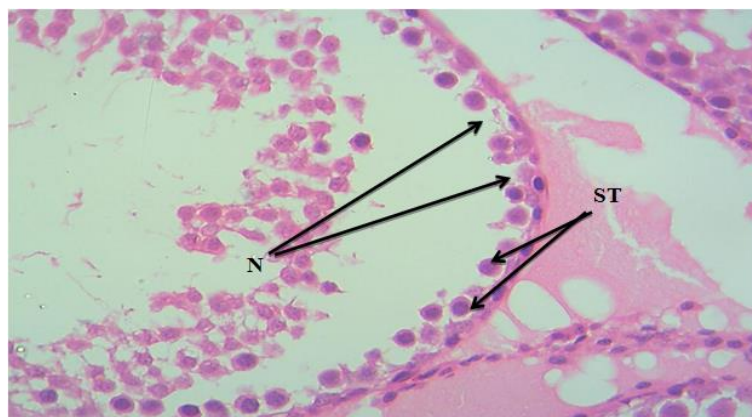


Fig (2) A Section in the rats testicle The cadmium chloride treatment group shows necrosis (N) within the seminal tubule wall and the appearance of the primary spermatocyte (PS) only with the absence of the mature sperms. H & E 400x.

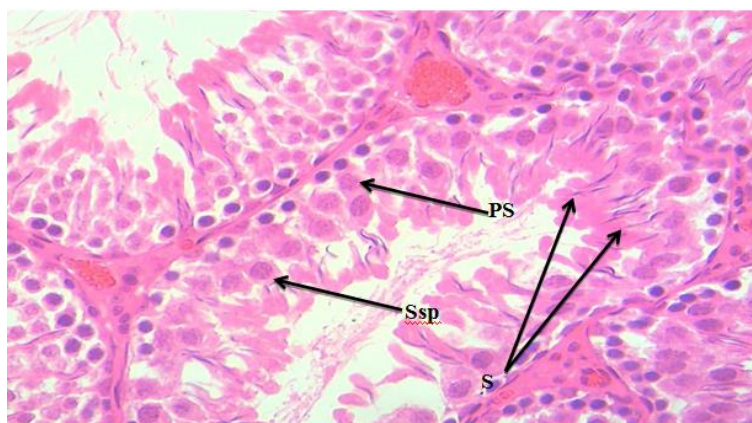


Fig (3) A section in the rats testicle The beetroot juice treatment group shows the sperm formation stages within the seminal tubules as the primary spermatocyte (Ps) and the secondary spermatocyte (Ssp) appear as the mature sperms (S) H & E 400X.

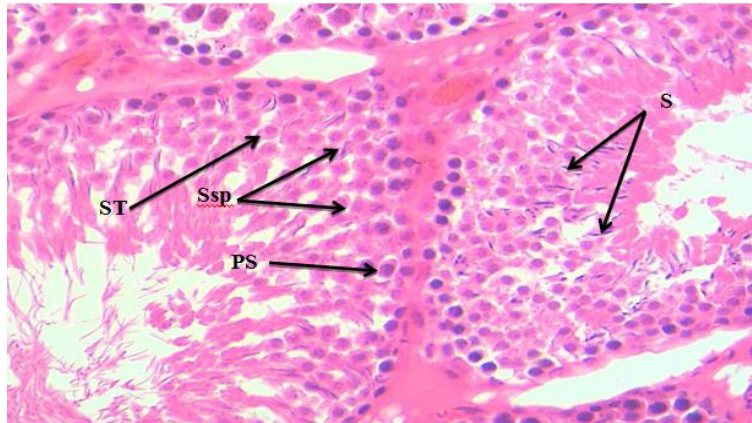


Fig (4) A section segment in the testis of the rats The treatment of cadmium chloride and beetroot juice shows the stages of sperms formation within the seminal tubules as the primary spermatocyte (PS), the secondary spermatocyte (Ssp) and the spermatids (ST) appear as mature sperms (S) H & E 400X.

3-3- sperms parameters




Fig (5) The control group shows :.A -sperm without a tail, B-normal sperm. E & N 400X

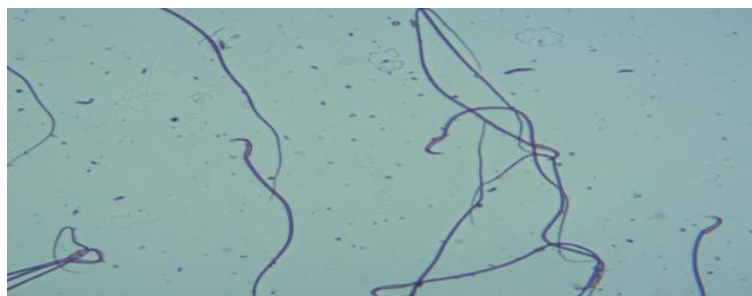

Fig (6) The beetroot juice treatment group shows : Normal sperm . E & N 400X

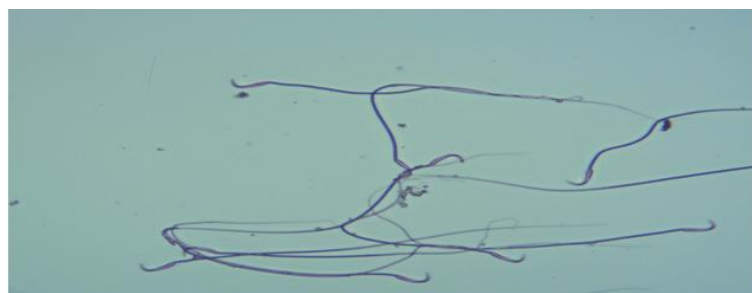


Fig (7) The beetroot juice treatment group shows Normal sperm . E & N 400X

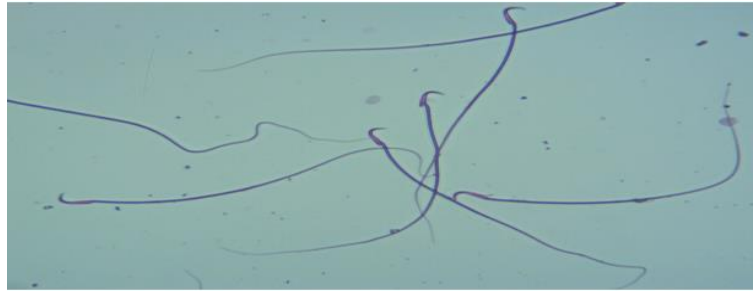


Fig (8) The treatment of cadmium chloride and beetroot juice shows: Normal sperm . E & N 400X

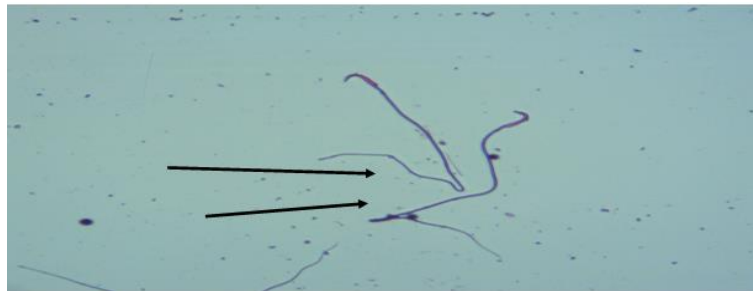


Fig (9) The CdCl₂ treatment group shows defective and cured tail sperm. E & N 400X

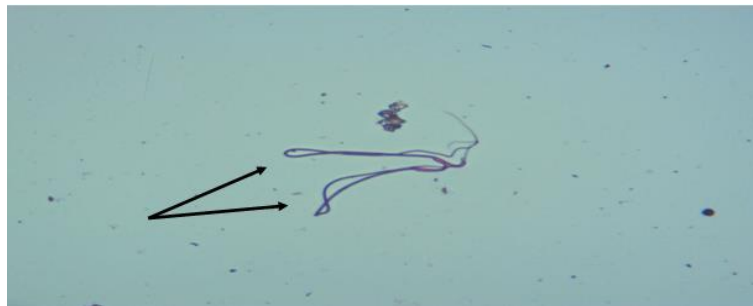

Fig (10) The CdCl₂ treatment group shows Sperm cured with tail. E & N 400X

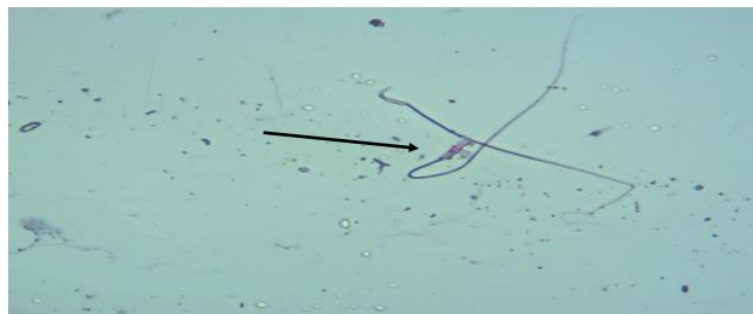


Fig (11) The CdCl₂ treatment group shows defective head sperm. E & N 400X

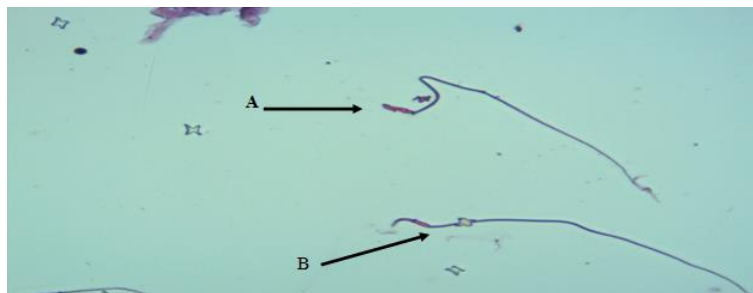

Fig (12) The CdCl₂ treatment group shows A- defective head sperm and B- defective tail sperm. E & N 400X

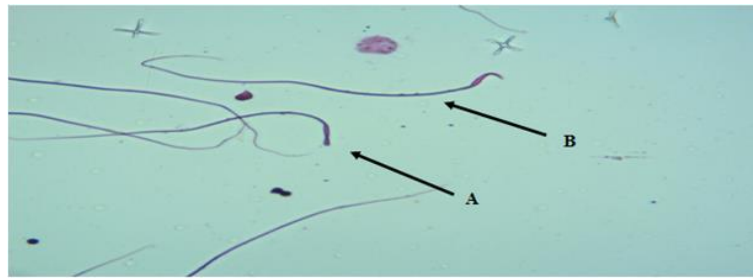


Fig (13) The CdCl₂ treatment group shows A- defective head sperm and B-normal sperm. E & N 400X

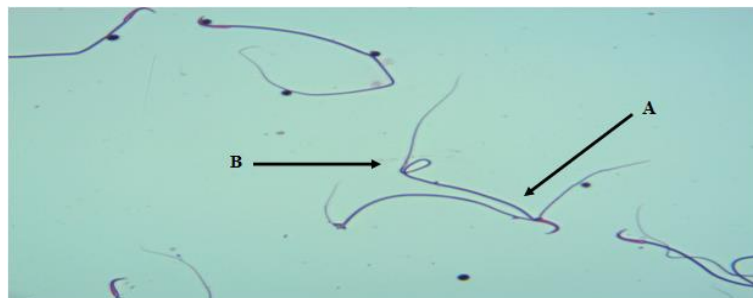


Fig (14) The CdCl₂ treatment group shows A- Sperm poly tail and B- defect tail . E & N 400X

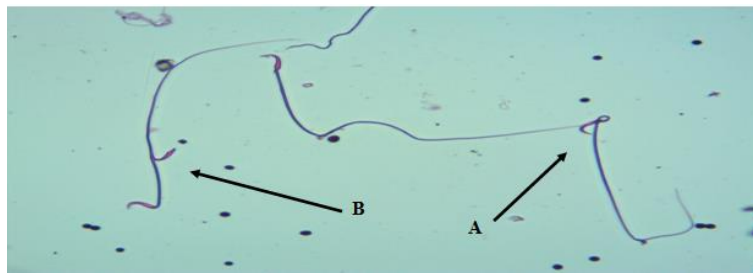


Fig (15) The CdCl₂ treatment group shows A- curved neck sperm and B- sperm tail head . E & N 400X

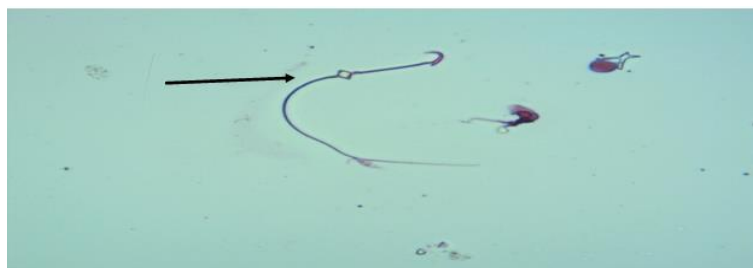


Fig (16) The CdCl₂ treatment group shows sperm with abnormal tail. E & N 400X

4-Discussion

The present study was devised to assess the effect of CdCl₂ toxicity on certain andrological, endocrinological and biochemical parameters of adult male rats.[21]

Exposure to environmental pollutants has been shown to adversely affect testicular function by affecting the pituitary gland to reduce the secretion of LH hormone while reducing the susceptibility of Leydig cells to the production of testosterone . [22,23],or may be due to the effect of cadmium on the pituitary gland, which affects the cells producing secretion of LH hormone and FSH and then decrease their level in the blood. [24].

The increase in oxidation of fat due to free radical reaction and the lack of antioxidants lead to tissue

breakdown leading to oxidative damage. The effective oxygen varieties produced by cadmium toxicity break down Leydig cells, responsible for the secretion of testosterone . [25].

The histological examination of the males of the rats showed the control group and the range of the beetroot juice, the normal shape of the spermatozoa and the regularity of its forms and the presence of the basic stages of sperm generation, known as Spermatogenesis, with the link between the tubules and the cells of Leydig and Sertoli responsible for the natural development of healthy sperm.

While the tissue test showed significant changes in the testicular tissue of the male group of rats treated with cadmium chloride, which leads to the occurrence of oxidative stress, cadmium shows the tissue

necrosis (N) within the spermicidal wall and the appearance of primary sperm cells (PS) only with the formation of mature sperm. With very few sperm cells and loss of most sperm formation.

Cadmium can cause a significant increase in the reactive oxygen species (ROS) in the semen, causing subversion of the DNA and activation of the peroxidation of unsaturated fatty acids in the membranes of sperm cells lining the spermatozoa (Sertoli and Spermatogenesis), destroying them or leading to death of sperm through changes in the nature of proteins in the plasma membrane of the sperm. [26,27]

In addition, increasing the number of reactive oxygen species (ROS) in the semen, which leads to DNA damage to the energy houses, causing genetic mutations leading to a defect in the construction of proteins and then lead to a defect in the transmission chain of electrons and thus decrease in production of Energy (ATP). This affects the bacterial cells which in turn affect the process of sperm origination [28].

Treatment of male rats treated with cadmium chloride at a dose of 5 mg / kg bw resulted in significantly significant changes in $P \leq 0.05$ in sperm parameters compared to control group. Heavy metals, including cadmium, were shown to cause oxidative stress by generating active oxygen species [29].

Effective oxygen species destroy the fat structure of the plasma membrane, which is accompanied by loss of mobility and deformation of the midwives. [30,27]. The cause of deformity in the midwifery is due to the low level of fructose in semen. Fructose is produced in the seminal vesicles and its production is controlled by male hormones in the testicle. [31]

That Lack of hormones leads to fructose deficiency or even disappearance of semen, and the lack of male hormones is associated with increased production of

Reference

- [1] Cobbina, S.J. et al. (2015). Toxicity assessment due to sub-chronic exposure to individual and mixtures of four toxic heavy metals. *J of Hazardous Materials*; **294**:109-120.
- [2] Zhou, Z. et al. (2016). Cadmium Exposure is Associated with the Prevalence of Dyslipidemia. *Cell Physiol Biochem*; **40**:633-643.
- [3] Karimi, O.S.H. and. Mortazavi, S.P. (2014). Toxic effects of cadmium in Japanese quail (*Coturnix japonica*): Assessment of body weight and histopathology of liver and kidneys. *Adv. Environ. Biol.*, **8**: 288-294.
- [4] Odewumi, C.O.; Latinwo, L.M.; Ruden, M.L.; Badisa, V.L.D.; Fils-Aime, S. and Badisa, R.B. (2015). Modulation of cytokines and chemokines expression by NAC in cadmium chloride treated human lung cells. *Environ. Toxicol., (In Press)*. **10**.1002/tox.22165.
- [5] Haidry, M.T. and Malik, A. (2014). Hepatoprotective and antioxidative effects of terminalia arjuna against cadmium provoked toxicity

effective oxygen species that cause tissue damage to the test result of exposure to cadmium. [25]

The decrease in the number of sperm and the increase in the number of mutated sperm in animals treated with cadmium chloride may be due to several changes in the testis tissue such as the destruction of the vascular epithelium and its damage. Which lead to an interruption of blood supply and the incidence of degeneration and testicular degeneration. [32]

Beetroot pomace showed the antiradical activity towards DPPH and hydroxyl radicals, beetroot juice has a protective role against the toxicity of harmful chemicals such as protected male rats from oxidative stress induced by carbon tetrachloride (CCl₄) and reduced plasma protein carbonyls and DNA damage in blood leukocytes. [14]

Beetroot contain potent antioxidants to protect the rat's male organ from the toxicity of cadmium chloride, beetroot is a rich source of potent nutrients including magnesium, sodium, potassium, vitamin C and betaine. Results from several in vitro studies have demonstrated that betalains from beetroots possess powerful antiradical and antioxidant activity. [33]

Besides other active chemicals, beetroots contain a unique class of water-soluble, nonphenolic antioxidants, the betalains, including two classes of compounds, red betacyanins (principally betanin) and yellow betaxanthines. The antioxidant effects of betalains have been demonstrated mainly in various in vitro experiments [13].

5-Conclusions

The current study found that beetroot juice has a protective role in protecting the male reproductive system against the toxicity of cadmium chloride. So as to possess beetroot compounds, Flavonoids and total flavones, which promote reproductive function and increase antioxidant enzymes.

in albino rats (*Ratus norvigicus*). *Biochem. Pharmacol.* **10**.4172/2167.

[6] Liu, C.M. et al. (2010). Quercetin protects rat liver against lead-induced oxidative stress and apoptosis. *Environ. Toxicol. Pharmacol.*, **29**: 158-166.

[7] Nair, A.R. et al. (2015). Glutathione and mitochondria determine acute defense responses and adaptive processes in cadmium-induced oxidative stress and toxicity of the kidney. *Arch. Toxicol.*, **89**: 2273-2289.

[8] Yari, A. et al. (2016). Bahadoran H, Joghataei M, Asadi M, Shams A: Efficacy of *Crocus sativus* L. on reduction of cadmium-induced toxicity on spermatogenesis in adult rats. *Andrologia*; **10**.1111/and.12568.

[9] Liu, Q. et al. (2013). Effect of cadmium on rat Leydig cell testosterone production and DNA integrity in vitro. *Biomed Environ Sci*; **26**:769-773.

[10] Hu, K.H. et al. (2015). Cadmium Induced Apoptosis in MG63 Cells by Increasing ROS, Activation of p38 MAPK and Inhibition of ERK 1/2 Pathways. *Cell Physiol Biochem*, **36**:642-654.

- [11] Herbach, K.M.; Stintzing, F.C.; Carle, R.(2004). Thermal degradation of betacyanins in juices from purple pitaya [*Hylocereus polrhizus* (Weber) Britton & Rose] monitored by high-performance liquid chromatography-tandem mass spectrometric analyses. *Eur. Food Res. Technol.*, **219**:377–385.
- [12] Stintzing, F.C.; Schieber, A. and Carle, R. (2003). Evaluation of colour properties and chemical quality parameters of cactus juices. *Eur. Food Res. Technol.* **216**, 303–311.
- [13] Kanner, J.; Harel S. and Granit Betalains, R. (2001). A new class of dietary cationized antioxidants. *J. Agric. Food Chem.*, **49**: 5178-5185.
- [14] Kujawska, M. et al. (2009). Protective effect of red beetroot against carbon tetrachloride- and N-nitrosodiethylamine-induced oxidative stress in rats. *J Agric Food Chem.* **57**:2570–2575.
- [15] Ninfali P. and Angelino, D. (2013). Nutritional and functional potential of Beta vulgaris cicla and rubra. *Fitoterapia.* **89**:188–199.
- [16] Naeem, M. R.(2015). Effect of Red Beetroot (*Beta vulgaris L.*) And its Fresh Juice Against Carbon Tetrachloride Induced Hepatotoxicity in Rats . *World Applied Scien.J.* **33 (6)**: 931-938.
- [17] Adnaik, R.S.; Gavarkar, P.S. and Mohite, S.K. (2015). Evaluation of antioxidant effect of *Citrullus vulgaris* against cadmium-induced neurotoxicity in Mice brain .*Inter. J. Pharm. Scien. Res.* P-ISSN: 2320-5148.
- [18] Zeneveld, L. and Polakoski, K. (1977). Collection and physical examination of the ejaculate . In: Techniques of human Andrology. Hafez, E.S.E. (eds). Elsevier /North Holland Biochem press
- [19] Bardin, C.W. and Paulsen, C.A.(1981).Textbook of endocrinology. 6th edition. Williams and Saunders, Philadelphia. (6) p:293-354.
- [20] Anthony, L.M.(2016). Basic histology , Text and Atlas ,fourteenth edition . *Indian Univer, School of Med . p-1-4.*
- [21] Stoths, S.J.; Bagchi, D.; Hassoun, E.; Bagchi, M.(2001). Oxidative mechanisms in the toxicity of chromium and cadmium ions. *J Environ Pathol Toxicol Oncol* **20**: 77-82.
- [22] Al-Attar, A.M.(2011). Antioxidant effect of vitamin E treatment on some heavy metals-induced renal and testicular injuries in male mice. *Saudi J. of Biolo. Scie.*,**18**:63-72.
- [23] Murugesan, P.;Muthusamy, T.;Balasubramanian, K. and Arunakaran, J.(2007). Effects of vitamins C and E on steroidogenic enzymes mRNA expression in polychlorinated biphenyl exposed adult rat Leydig cells. *Toxicol.* **232**, 170-182.
- [24] Ekhoie, E.I.; Nwangwa, E.K. and Aloamaka, C.P.(2013). Changes in some testicular biometric parameters and testicular function in cadmium chloride administered wistar rats. *Brit.J.Medi . Medi .* **3(4)**: 2031-2041.
- [25] Li, R. et al. (2015). The Protective Effects of Melatonin Against Oxidative Stress and Inflammation Induced by Acute Cadmium Exposure in Mice Testis. Biological Trace Elements Research, First online 30 July. Doi:**10.1007/s12011-015-0449-6**. supplied by Springer publisher.
- [26] El-Taieb, M.A.A.; Herwig, R.; Nada, E.A.; Greilberger, J. and Marberger, M.(2009). Oxidative stress and epididymal sperm transport, motility and morphological defects. *Eur. J. Obst. Gynecol Reprod. Biol.*; **144**: 199-203.
- [27] Shiva, M.; Gautam, A.K.; Verma, Y.; Shivgotra, V.; Doshi, H. and Kumar, S. (2011). Association between sperm quality, oxidative stress, and seminal antioxidant activity. *Clin. Biochem.*, **44(4)**: 319- 324.
- [28] Venkatesh, S. et al. (2009). Clinical significance of reactive oxygen species in semen of infertile Indian men . *Andro* , **41**: 251-256.
- [29] Weidinger, A. and Kozlov, A.V. (2015). Biological Activities of Reactive Oxygen and Nitrogen Species: Oxidative Stress versus Signal Transduction. *Biomolec.*, **5**: 472-484.
- [30] Khan, A.N.; Khan, R.A.; Ahmad, M. and Mushtaq, N.(2015). Role of antioxidant in oxidative stress and diabetes mellitus. *J. Pharmacog. Phytochem.* **3(6)**: 217-220.
- [31] Brooks, D.E.(1979). Biochemical environment of sperm maturation. [In the Spermatozoa, Fawcett, D.E. and Bedford, J.M. (eds). (Urban & Schwargenber Baltimore), 23.
- [32] Baharara, J.; Zafar-Balanejad, S.; Kamareh, E. and Asadi-Samani, M.(2014). The effects of green tea extract on teratogenicity induced by low frequency electromagnetic field on bone marrow Balb/C mice embryo. *J. Herbmed Pharmacol.*,**3(1)**:47-51.
- [33] Kujala, T.S.; Vienola, M.S.; Klika, K.D.; Loponen, J.M. and Pihlaja, K. (2002). Betalain and phenolic compositions of four beetroot (*Beta vulgaris*) cultivars. *Eur. Food Res. Technol.*, **214**: 505-510.

فعالية الدور الوقائي لعصير الشمندر في الجهاز التناسلي الذكري للجرذان البيض ضد سمية كلوريد الكاديوم

قاسم عزيز رزوقي الجنابي , راشد خميس شعبان القيسي , نور ابراهيم حسن الكراعي

كلية التربية للعلوم الصرفة , جامعة تكريت , تكريت , العراق

الملخص

صُممت هذه الدراسة لتقييم الدور الوقائي لعصير الشمندر ضد سمية كلوريد الكاديوم (CdCl₂) في ذكور الجرذان البيض. شملت الدراسة على 20 ذكراً من الجرذان البيض تراوحت اعمارها ما بين (2-3 شهور) والأوزان تراوحت بين (220-260 غم) ، وتم تقسيمها عشوائياً إلى 4 مجموعات، أعطيت المجموعة الأولى الماء المقطر التي اعدت مجموعة سيطرة، المجموعة الثانية أعطيت عصير الشمندر 10 مل / كغ وزن الجسم، المجموعة الثالثة أعطيت كلوريد الكاديوم بجرعة من 5 مغ / كغ وزن الجسم. لمدة 30 يوماً، وعدت سيطرة مصابة ، وتمت معاملة المجموعة الرابعة بعصير الشمندر 10 مل / كغ وزن الجسم. مع كلوريد الكاديوم. أظهرت النتائج أن معاملة الحيوانات بكلوريد الكاديوم أدى إلى انخفاض معنوي ($P \leq 0.05$) في الهرمونات قيد الدراسة وتأثيرات سلبية في الشكل الطبيعي للنطف واحداث تغيرات نسجية سلبية واضحة في انسجة الخصى مقارنة مع مجموعة السيطرة ، وبشكل عام أدى تجريع الجرذان المعاملة بكلوريد الكاديوم بعصير الشمندر، إلى تحسن إيجابي لمعظم قيم المؤشرات السابقة فقد ادى إلى ارتفاع معنوي، في تركيز الهرمونات LH، و FSH وهرمون التستوستيرون، وتحسن في معالم النطف، اذ انخفض بشكل واضح الشكل غير الطبيعي للنطف وإلى تحسن نسجي واضح وأصبحت مقارنة مع ما لوحظ في مجموعة السيطرة.