



Tikrit Journal of Pure Science

ISSN: 1813 – 1662 (Print) --- E-ISSN: 2415 – 1726 (Online)

Journal Homepage: <http://tjps.tu.edu.iq/index.php/j>



The protective effect of common fig (*Ficus carica* L.) leaves extract on testes of white rats (*Rattus norvegicus*) against paracetamol (Acetaminophen) drug.

Noori Taha Alkhafaji, Waad Sabri Shaher

Department of Biology, College of Science, Mosul University, Mosul, Iraq

<https://doi.org/10.25130/tjps.v25i6.310>

ARTICLE INFO.

Article history:

-Received: 19 / 9 / 2020

-Accepted: 16 / 10 / 2020

-Available online: / / 2020

Keywords: *Ficus carica*, paracetamol, spermatogenesis, leaves extract, testes

Corresponding Author:

Name: Noori Taha Alkhafaji

E-mail:

nooritaha9090@gmail.com

Wadsbio20@uomosul.edu.com

Tel:

ABSTRACT

Aim: This study to investigate the protective effect of *Ficus carica* leaves extract against the effect of paracetamol.

Material and methods: In the present study used (40) male rats (*Rattus norvegicus*) (2.5-3) months old, weighting (200-250)g were randomly divided into (4) groups of (10 rats/group). The first group (control group), the second group (paracetamol group), the third group (Fc leaves extract group), the fourth group (Fc leaves extract + paracetamol group). The first group were given (0.5 ml) distilled water, the second group were given paracetamol with dosage (1000 mg/kg), the third group were given alcoholic extract of *F. carica* leaves by dosage (250 mg/kg), the fourth group were given paracetamol by dosage (1000 mg/kg) and after two hours given (250 mg/kg) alcoholic extract of *F. carica* leaves, all groups were treated with doses between day and another for six weeks.

Results: The results of the present study showed a significant decrease ($P < 0.05$) to the relative weight of the testicles, the head and tail of the epididymis, the seminal vesicles of male rats in the paracetamol group compared with the control group and Fc leaves extract group, while showed treated by alcoholic extract of *F. carica* leaves after paracetamol an improvement in the relative weight of the testicles, the head and tail of the epididymis, the seminal vesicles in Fc leaves extract group and Fc leaves extract + paracetamol compared with paracetamol and control group. For the histopathological study showed occurrence histopathological changes of paracetamol drug, represented as complete stop of spermatogenesis, atrophy and hypoplasia of leydig cells, congestion of blood vessels, pyknosis of nucleus of primary spermatogonia, hemorrhage between seminiferous tubules, tunica albuginea and exfoliation of seminiferous tubules as cellular debris.

Conclusions: The paracetamol led to pathological changes in the tissues of male rat testes. It was represented by a complete cessation of spermatogenesis and a loss of the developmental stages of this process, while The alcoholic extract of *F. carica* leaves had protective effect against the influence of paracetamol.

Introduction

Paracetamol or acetaminophen is chemically referred to as N-acetyl-p-aminophenol, which is widely used without a prescription for treating headaches as analgesic, antipyretic, flu therapy, severe colds [1,2]. For adult humans, the typical reported dosage of Paracetamol is 500-1000 mg/kg, but the daily does not exceed 4000 mg [3]. The initial action of

Paracetamol may be prostaglandin inhibition similar to cyclooxygenase-1 and 2 inhibition, due to the peroxidase activity of these regulated enzymes [4,5]. And those enzymatic reactions reduce glutathione production. Also, coenzyme such as prostaglandin-E-synthase inhibits prostaglandin production and induces oxidative stress [4,5,6]. Using a heavy dose

of Paracetamol (more than 2000 mg / day) raises the risk of complications in the upper gastrointestinal (Gastrointestinal) tract such as hemorrhage of the stomach [7]. It was found that a single dose of Paracetamol (4.4 mmol / kg) administered to male rats resulted in irregular changes in morphological changes and degeneration in certain seminal tubules, fragmentation of Sertoli cells and changes in spermatide structure [8]. The chemical pathogenesis of Paracetamol toxicity can be due to the formation of reactive or reactive oxygen species, difference in levels of active oxygen species and antioxidants, and the activation of oxidative stress, resulting in damage and cell death [9,10,11]. antioxidants are commonly used for breaking the oxidation reaction chain [12,13].

Interest in herbal medicine and its usage in the treatment of infertility has increased in recent decades, possibly because of the availability of antioxidants in plants along with their efficacy against infertility [14]. A common fig plant (*Ficus carica* L.), which belongs to the family (Moraceae) and is cultivated in West Asia and the Middle East, is among the medicinal plants. Different parts of the plant, such as leaves, berries, bark, seeds, and latex, have been used to treat many diseases such as jaundice and anemia, Diarrhea, anti-inflammatory agents, etc., because the plant is rich in minerals, vitamins, and many other compounds, including flavonoids, enzymes, nicotinic acid, tyrosine, and mucilage [15,16]. Fig leaves contain higher amounts of phenolic compounds compared to fruits, so they contain the best antioxidants [17]. and these phenolic compounds are capable of removing free oxidizing radicals and ions and inhibiting some enzymes [18]. The present study aims to consider the harmful effects on testicular tissues of the use of high doses of paracetamol and the protective effect of *F. carica* leaf extract against the use of paracetamol in male rats (*Rattus norvegicus*).

Materials and methods

Extract preparation: -

1- Collecting plant samples:-

Fig leaves (*Ficus carica* L.) collected from the Rashidiya region in the city of Mosul on 27/April/2019. The leaf samples washed with tap water to get rid of dust and spread them in the shade to dry on clean white papers. The leaves were then ground with an electric grinder to acquire the fig leaves in powder form and stored in paper bags in a dry place until they are used in preparing the extract[19].

2-prepare the alcoholic extracts of *Ficus carica* leaves:-

(100) g of plant papers powder mixed with (400) ml of ethyl alcohol (80%). Then the solution left for (48) hours. The solution filtered by gauze the resulting solution by the filter paper (Whatman No.1) for twice in a row, then placed in the rotary evaporator (Ratory evaporator) to isolate the alcohol and obtain

the extracted material, that was a brown-green glue kept in the refrigerator until use and preparation of the required concentrations[20].

Obtaining animals

In the study, (40) adult white male rats, of the type *Rattus norvegicus*, were obtained from the animal house of the College of Veterinary Medicine/ Mosul University. Their ages ranged between (2.5-3) months and their weights ranged from (200-250) g. The animals were subjected to suitable laboratory conditions for raising laboratory animals in terms of temperature (20 ± 2) ° C and a light cycle (10) light hours (14) hours of darkness, Given a standard diet and water ad libitum throughout the trial period.

Experimental design

The animals were randomly distributed in equal numbers into four groups each group (10 rats) and were treated as follows: _

1- First Group (control group):-

The animals were given (0.5 ml) of distilled water orally by the oral tube (Cavage needle) from day to another and for a period of (6) weeks.

2- Second Group (Paracetamol group): -

Paracetamol was administered to of this animals group at a dosage of (1000 mg / kg) body weight [21]. orally by tube for a duration of (6) weeks from the day to another.

- Third Group (FC extract group):-3

Alcoholic extract of *F. carica* leaves was administered to the group animals at a dosage of (250 mg / kg body) weight (Naghdi *et al* . , 2016) from day to another and orally through an oral tube for a duration of (6) weeks.

4- Fourth Group (FC extract + Paracetamol Group):-

This group given the alcoholic extract of *F. carica* leaves orally by the oral tube at a dose of (250 mg / kg) of body weight, and after two hours the animals were given paracetamol by mouth at a dose of (1000 mg / kg) of body weight from one day and another[19]. And for (6) week time.

Histological study

The animal of each group were anesthetized with chloroform. The testes were carefully isolated and immobilized in neutral formalin (10%). The dehydrated with progressing degrees of ethanol alcohol (70% to 100%) the testes clearing with two changes of xylene, impregnated with 2 changes of paraffin wax, and finally were into the wax. Testes sections were cut 5 µm thick using a microtome and dye with hematoxylin and eosin, and loaded with DPX[20,22]. Histological sections were imaged using optical microscope with a digital camera.

Statistical analysis

SPSS statistical program was used to analyze the results of the study in the studied traits. Through the SPSS program, Completely Randomized Design System was used for the studied trait anisometry. The rates were extracted for the studied characteristics in addition to extracting the standard error. The Duncan

multi-range test was also used to measure the significance of the difference between the means at the significance level $P < 0.05$.

Result

The results of present study showed a significant decrease ($P < 0.05$) in the relative weights of the testes and epididymis (head and tail) and seminal

vesicles of male rats in the paracetamol group compared with the control group and Fc leaves extract group, while the relative weights of the testes, epididymis and seminal vesicles in the extract group + paracetamol were gradual improvement compared with paracetamol group, control group and Fc leaves extract group.(Table).

Table: Protective effect of the alcoholic extract of *Ficus carica* leaves on the relative weights of the testes, epididymis and seminal vesicles of male rats treated with paracetamol.

Treatments	Relative organ weight(mg/100)			
	Testes	Epididymis head	Epididymis tail	Seminal vesicles
control group	865.91 \pm 73.81 c	188.27 \pm 4.88 b	194.62 \pm 5.18 c	313.42 \pm 25.74 c
Paracetamol group	499.97 \pm 63.81 a	131.45 \pm 10.15 a	132.21 \pm 7.86 a	185.91 \pm 10.33 a
Fc leaves extract group	826.31 \pm 35.77 bc	182.38 \pm 5.36 b	184.41 \pm 5.36 bc	201.97 \pm 13.30 bc
Fc leaves extract + Paracetamol Group	660.57 \pm 47.55 ab	165.81 \pm 19.07 ab	169.42 \pm 3.75 b	368.30 \pm 102.60 ab

All values: Mean \pm SE ;Similar letters in one column indicate that there are no significant differences at the level of ($p < 0.05$) between the groups.

The different letters in one column indicate significant differences at the level ($0.05 > p$) between the groups.

Histological results

Normal structure

The histologic study showed the normal structure of control group seminiferous tubules.(Fig1).

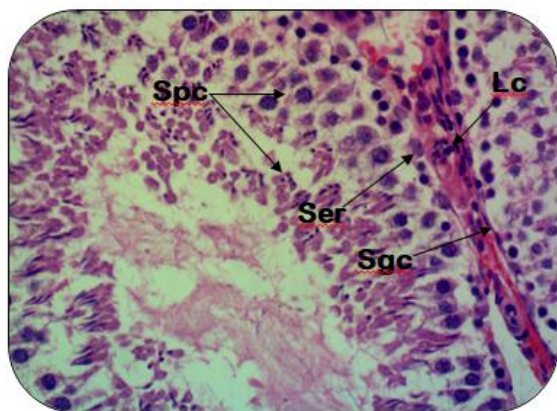


Fig. 1: An extended segment of a control group sperm tube showing the normal structure of the seminiferous tubule, Stages of spermatogenesis (spc), Spermatogenic cells (sgc), Sertoli cells (ser), and leydig cells (Lc), hematoxylin and eosin, 400X.

Pracetamol group

shows the effect of paracetamol (1000 mg / kg) on testicular tissue, where a complete stop in the spermatogenesis process is observed, as well as congestion of blood vessels and the deposition of proteinuric acid between the seminiferous tubules with pyknosis (PK) of nucleus of primary spermatogonia.(Fig 2,3).

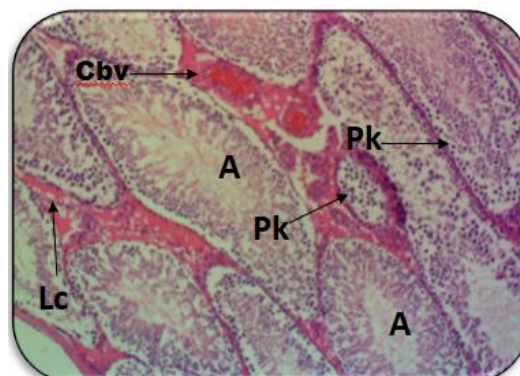


Fig. 2: Testis section of the paracetamol group showing complete interruption of spermatogenesis (A), hypoplasia of Leydig cells (Lc), congestion of blood vessels (Cbv) and pyknosis of nucleus of primary spermatogonia (pk), hematoxylin eosin, 100 \times .

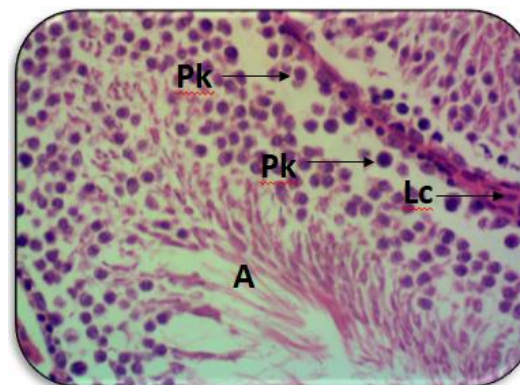


Fig. 3: Testis section of the paracetamol group showing stop of spermatogenesis (A) and atrophy and hyperplasia of Leydig cells (Lc) with pyknosis of nucleus of primary spermatogonia (pk) hematoxylin and eosin, 400 \times .

Also bleeding between the seminiferous tubules was observed and pyknosis of nucleus of primary spermatogonia.(Fig4).

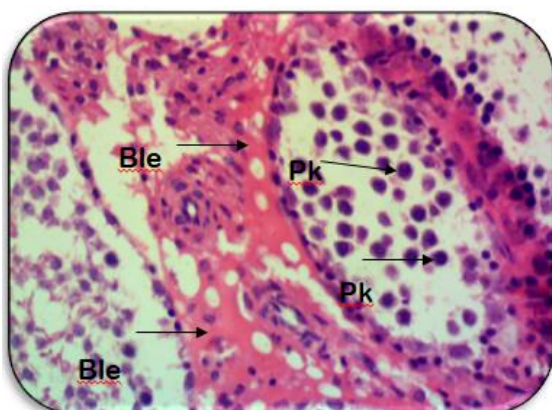


Fig. 4: Testis section of the paracetamol group showing the presence of bleeding between the seminiferous tubules (Ble) and pyknosis of nucleus of primary spermatogonia (Pk). Hematoxylin and Eosin, 400 ×

The results of the histopathological effects of paracetamol showed that spermatogenic cells separated from the spermatogonia cells and thickening of the tunica albuginea .(Fig5)

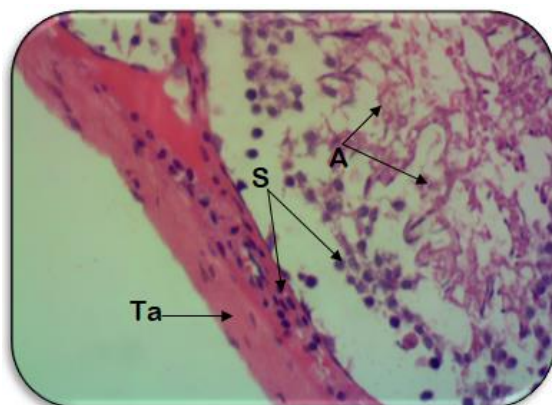

Fig. 5: A segment of a seminiferous tube of the paracetamol group showing the stop of the spermatogenesis process (A) and the separation of the spermatogenic cells from the spermatogonia cells (S) and the tunica albuginea thickens (Ta). Hematoxylin and Eosin, 400 ×

The histological results showed also the complete loss of the developmental stages of spermatogenesis , the decrease and irregularity of the spermatogenic cells and the thickening of the tunica albuginea.(Fig6).

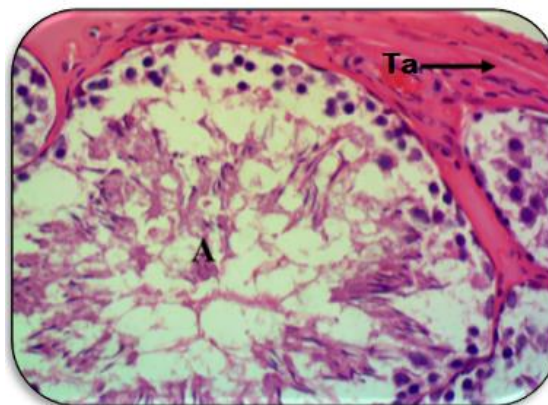


Fig. 6: A segment of a seminiferous tube of paracetamol group showing complete loss of spermatogenesis (A) and tunica albuginea thickened(Ta) hematoxylin and eosin, 400 ×.

The histological study also showed that the components of the seminiferous tubules were exfoliated in the form of cellular debris and aggregated as an acid-colored substance.(Fig7).

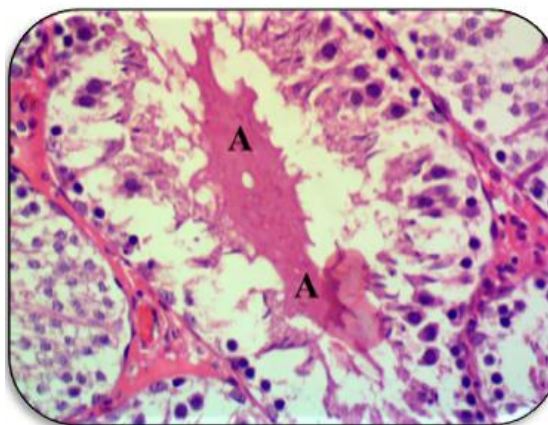


Fig. 7: Paracetamol group testis Shows exfoliation the seminiferous tubule components in the form of cellular debris with aggregated as an acid-colored material(A) Hematoxylin and Eocin, 400 x.

Fc leaves extract group

The histological study also showed the effect of *Ficus carica* leaves extract (250 mg / kg) on the tissue of the testis, where showed the normal structure and the process of spermatogenesis are observed in all its stages, the regularity of the spermatogenic cells towards the lumen of the seminiferous tubule and the presence of a large number of sperms in the lumen of the tubule of the FC extract group.(Fig8).

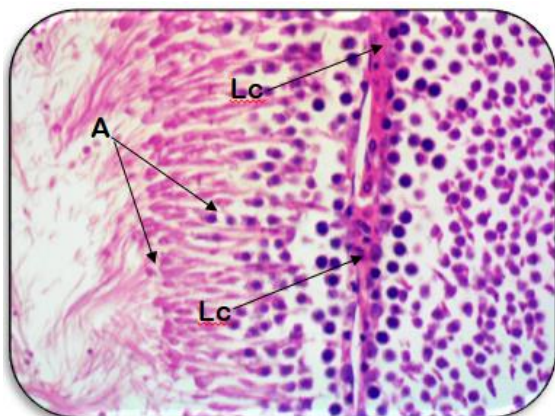


Fig. 8: Testis section of the Fc extract group showing the normal structure of the seminiferous tubules, the presence of the whole spermatogenesis process(A) and the presence of Leydig cells (Lc), hematoxylin and eosin, 400 x.

Fc leaves extract + paracetamol group

The histological study of the protective effect of Ficus carica leaves extract (250 mg / kg) + paracetamol group on testicular tissue, as showed the resumption of spermatogenesis in some seminiferous tubules with the continuation of this process being discontinued in other number of tubules. The return of the Leydig cells between the seminiferous tubules to the normal structure and the disappearance of the acid protein deposited between the seminiferous tubules.(Fig9,10).

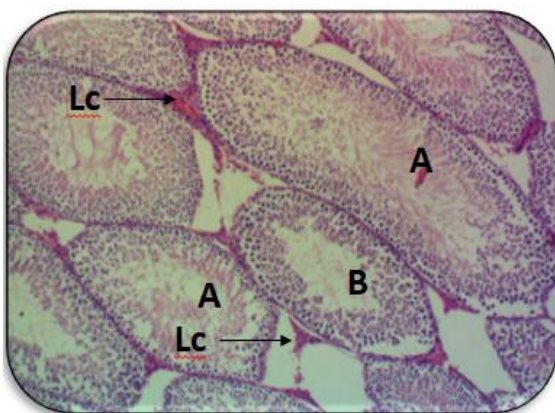


Fig. 9: A testis section of the Fc extract + paracetamol group showing the stages of spermatogenesis in some tubules (A), the stop of spermatogenesis in other tubules (B), the return of Leydig cells (Lc) between the tubules. Hematoxylin and eosin, 100 x.

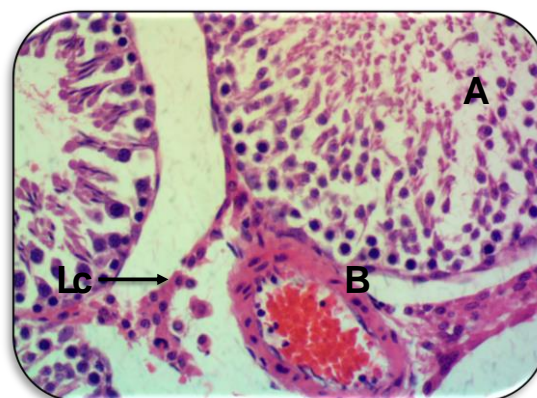


Fig. 10: Testis section of the extract + paracetamol group showing the return of spermatogenesis in some seminiferous tubules (A), the return of Leydig cells to their normal structure (Lc). hematoxylin and eosin, 400 x.

Discussion

In this present study, the paracetamol group showed a significant decrease ($P < 0.05$) in the relative weights of the testes and epididymis (head and tail) and the relative weight of seminal vesicles when compared with the control group and Fc extract group. This can be explained by the changes and degenerations that occur in the seminiferous tubules during the current study, which can result in a decrease in the relative weight of the testicles, as these seminal tubules constitute the structural and functional unit of the testicles.

The current research has shown that paracetamol in male rats treated with a dosage of (1000) mg / kg body weight induced changes in testicular tissue. These changes were primarily reflected in the spermatogenesis developmental stages and thus the effect on the spermatogenesis process by affecting the spermatogenic cells, form, vitality, and sperm preparation, as well as the Leydig cells.

The reason for these changes is that paracetamol induces oxidative stress, especially when used in high doses, which causes pathological changes in the epithelial tissues lining the spermatogenic cells (germ cells), which enhances the health of this is the occurrence of toxicization in the components of the seminal tubule and a decrease in the diameters of the seminiferous tubules. The decrease in the number of sperm-forming cells, as well as the number of sperm, is that the Leydig cells are under the negative influence of oxidative stress as well, being an important part of the testicle tissue, which causes a decrease in the level of the hormone testosterone produced by these cells, which plays a fundamental role in the development and maturation of sperm[23,24].

The precise mechanism of paracetamol action and the hepatotoxicity of this drug is due to the formation of reactive metabolites by enzymes (Cyclooxygenase 1 and 2 Cyclooxygenase) and such enzymatic reactions may reduce the formation of glutathione and inhibition of prostaglandin building and the induction of oxidative stress [4,5,6]. Yano and Dolder (2002) reported irregular morphological changes in male adult rats treated with a single dose of paracetamol (4.4 mmol / kg) of body weight due to degeneration of the seminiferous tubules and fragmentation of Sertoli cells and morphological changes of spermatids (spermatid)[8]. In a recent review, Diab *et al.*, (2020) found that the paracetamol dose (500 mg / kg) for a duration of (5) weeks had harmful effects on the tissues of the testes, liver and kidneys, Of the spermatogenic epithelial cells (Spermatogenic cells) and the incidence of hemorrhage in the interstitial tissue and pyknosis of the Lidge cells and spermatocytes in the lumen of the damaged seminiferous tubules[25]. And this result agrees with and confirms the result of current study that showed many of these changes in the tissues of male rats treated with Paracetamol.

Histological studies in this current study have also shown that administration of *F. carica* leaves extract eliminates some of the harmful effects that

References

- [1] Anderson B.J.; Hollford N.H.G. and Woolard G.A. (1998): Paracetamol plasma and cerebrospinal fluid pharmacokinetics in children. *Br. J. Clin. Pharmacol.*, **46**: 237–43
- [2] Oyediji, A. F.; Bolarinwa, A. F. and Ojeniran, S. S. (2013). Effect of paracetamol (Acetaminophen) on haematological and reproductive parameters in male albino rats. *Res. J. Pharmacol.*, **7** (2): 21- 25.
- [3] Bergman, K.; Müller, L. and Teigen, S.W. (1996). The genotoxicity and carcinogenicity of paracetamol: a regulatory (re)view. *Mutat Res-Fund Mol Mech* **349**:263–288.
- [4] Graham, G. G. and Scott, K. F. (2005). Mechanism of action of paracetamol. *American Journal of Therapeutics*, **12**: 46–55.
- [5] Graham, G. G.; Davies, M. J.; Day, R. O.; Mohamudally, A., and Scott, K. F. (2013). The modern pharmacology of paracetamol: therapeutic actions, mechanism of action, metabolism, toxicity and recent pharmacological findings. *Inflammopharmacology*, **21**: 201–232.
- [6] Lebda, M. A.; Taha, N. M.; Korshom, M. A.; Mandour, A. A. and Goda, R. I. (2013). Ginger (*Zingiber officinale*) potentiate paracetamol induced chronic hepatotoxicity in rats. *J. Med. Plant. Res.*, **7** (42): 3164- 3170.
- [7] Carcia, R.L.A. and Hernandez-Diaz, S. (2000).“The risk of upper gastrointestinal complications associated with non-steroid anti-inflammatory drugs, glucocorticoids, acetaminophen, and combination of these agents”. *Arthritis Research and Therapy* **3**:98.
- [8] Yano, C. L., and Dolder, H. (2002). Rat testicular structure and ultrastructure after paracetamol treatment. *Contraception*, **66**: 463–467.
- [9] Adam, G. O.; Rahman, M. M., Lee, S. J., Kim, G. B., Kang, H. S., Kim, J. S. and Kim, S. J. (2016). Hepatoprotective effects of *Nigella sativa* seed extract against acetaminophen- induced oxidative stress. *Asian Pacific Journal of Tropical Medicine*, **9**: 221–227.
- [10] Aksu, E. H.; Ozkaraca, M.; Kandemir, F. M.; Omur, A. D.; Eldutar, E.; Kucukler, S. and Comakli, S. (2016). Mitigation of paracetamol-induced reproductive damage by chrysin in male rats via reducing oxidative stress. *Andrologia*, **48**: 1145-1154.
- [11] Eugenio-Perez, D.; de Montes Oca-Solano, H. A. and Pedraza - Chaverri, J. (2016). Role of food-derived antioxidant agents against acetaminophen-induced hepatotoxicity. *Pharmaceutical Biology*, **54**: 2340–2352.
- [12] Miller, J.K.; Brzezinska - Slobodzinska, E. and Madsen, F.C.(1993).“Oxidative stress, antioxidants, and animal function,”*Journal of Dairy Science*, **76**(9):pp.2812–2823.
- [13] Bansal, A.K. and Bilaspuri, G.S.(2008).“Mn2+: a potent antioxidant and stimulator of sperm capacitation and acrosome reaction in crossbred cattle bulls,”*Archiv fur Tierzucht*, **51**(2):pp.149–158.
- [14] Safarnavadeh, T. and Rastegarpanah, M.(2011). “Antioxidants and infertility treatment, the role of Satureja Khuzestanica: a mini-systematic review,

"Iranian Journal of Reproductive Medicine, **9**(2): pp. 61–70,

[15] Canal, J.R.; Torres, M.D.; Romero, A. and Perez, C. (2000). A chloroform extract obtained from a decoction of *Ficus carica* leaves, improve the cholesterolaemia of rats with streptozocin-induced diabetes. *Acta Physiol Hung* **87**:71–6.

[16] Joseph, B. and Raj, S.J. (2011). Pharmacognostic and phytochemical properties of *Ficus carica* Linn – An overview. *Int. J. Pharm. Tech. Res.*, **3**:8–12.

[17] Oliveira, A. P.; Valente, P.; Pereira, J.A.; Silva, B.M.; Tavares, F. and Andrade, P.B. (2009). "*Ficus carica* L.: metabolic and biological screening," *Food and Chemical Toxicology*, **47**(11); pp.2841–2846

[18] Samsulrizal, N.; Awang, Z.; Najib, M. L. H. M.; Idzham, M. and Zarin, A. (2011). Effect of *Ficus deltoidea* leaves extracts on sperm quality, LDH-C 4 activity and testosterone level in alloxan-induced male diabetic rats. In *2011 IEEE Colloquium on Humanities, Science and Engineering* (pp. 888-891). IEEE.

[19] Naghdi, M.; Maghbool, M.; Seifalah-Zade, M.; Mahaldashtian, M.; Makoolati, Z.; Kouhpayeh, S. A.,... and Fereydouni, N. (2016). Effects of common fig (*Ficus carica*) leaf extracts on sperm parameters and testis of mice intoxicated with formaldehyde. *Evidence-Based Complementary and Alternative Medicine*.

[20] Al-Shaher, W.S. (2020) Effect of leaf extract of *Melia azedarach* L. on the testis tissue of albino mice *Mus musculus*. *Raf. J. Sci.*, **29**(1):1-9.

[21] Ratnasooriya, W. D. and Jayakody, J. R. (2000). Long-term administration of large doses of paracetamol impairs the reproductive competence of male rats. *Asian Journal of Andrology*, **2**, 247–255.

[22] Luna, L. G. (1968). Manual of histological staining methods of the armed forces institute of pathology. *McGraw-Hill Book Company*.

[23] Sofikitis, N.; Giotitsas, N.; Tsounapi, P.; Baltogiannis, D.; Giannakis, D. and Pardalidis, N. (2008) Hormonal regulation of spermatogenesis and spermiogenesis. *J Steroid Biochem Mol Biol* **109**:323–330.

[24] Banihani, S. A. (2018). Effect of paracetamol on semen quality. *Andrologia*, **50**(1), e12874.

[25] Diab, K. A.; Fahmy, M. A.; Hassan, E. M.; Hassan, Z. M.; Omara, E. A. and Abdel-Samie, N. S. (2020). Inhibitory activity of black mulberry (*Morus nigra*) extract against testicular, liver and kidney toxicity induced by paracetamol in mice. *Molecular Biology Reports*, 1-17.

[26] Perez-Garcia, F.; Adzet, T. and Canigual, S. (2000). Activity of artichoke leaf extract on reactive oxygen species in human leukocytes. *Free Radical Res*; **33**:661–665.

[27] Algothary, A. M.; Ahmad-Farid, O. A.; Abdelrazek, A. M. and Al-Baradie, R. S. (2016). Neuroprotective effects of herbal cocktail on cerebrovascular dysfunction in rats with induced hyperhomocysteinaemia. *Biomed Res Ther*, **3**(12): 1045-1061.

التأثير الوقائي للمستخلص الكحولي لأوراق التين (*Ficus carica L.*) في أنسجة الخصى لذكور الجرذان البيض (*Rattus norvegicus*) ضد تأثير عقار الباراسيتامول.

نوري طه الخفاجي ، وعد صبري شاهر

قسم علوم الحياة ، كلية العلوم ، جامعة الموصل ، الموصل ، العراق

الملخص

الهدف: تهدف هذه الدراسة الى معرفة التأثير الوقائي لمستخلص أوراق التين (*Ficus carica L.*) ضد تأثير الباراسيتامول. **المواد وطرائق العمل:** في هذه الدراسة الحالية تم استخدام (40) من ذكور الجرذان باعمار (2.5-3) أشهر، تراوحت اوزانها (200-250)غم قسمت عشوائياً الى اربعة مجاميع (10جرذ/مجموعة). المجموعة الاولى (مجموعة السيطرة)، المجموعة الثانية(مجموعة الباراسيتامول)، المجموعة الثالثة (مجموعة مستخلص أوراق التين)، المجموعة الرابعة(مجموعة مستخلص أوراق التين + الباراسيتامول). أعطيت المجموعة الاولى (0.5) مل ماء مقطر، واعطيت المجموعة الثانية الباراسيتامول بجرعة (1000 ملغم/كغم) ، وأعطيت المجموعة الثالثة المستخلص الكحولي لأوراق التين بجرعة (250 ملغم/كغم)، اما المجموعة الرابعة أعطيت الباراسيتامول بجرعة (1000ملغم/كغم وبعد ساعتين أعطيت (250 ملغم/كغم) من المستخلص الكحولي لأوراق التين، أعطيت كل المعاملات الجرعة بين يوم وآخر ولمدة (6) أسابيع.

النتائج: أظهرت نتائج الدراسة الحالية انخفاضاً معنوياً ($P<0.05$) في الوزن النسبي للخصيتين، رأس وذيل البربخ، الحويصلات المنوية في مجموعة الباراسيتامول مقارنة مع مجموعة السيطرة ومجموعة مستخلص أوراق التين، بينما أظهرت المعاملة بمستخلص أوراق التين بعد الباراسيتامول تحسن في الوزن النسبي للخصيتين، رأس وذيل البربخ ، الحويصلات المنوية بالمقارنة مع مجموعة الباراسيتامول ومجموعة السيطرة. كما أظهرت الدراسة النسجية المرضية حدوث تغيرات نسيجية مرضية لعقار الباراسيتامول، تمثلت هذه التغيرات بتوقف تام لعملية تكوين النطف وضمور وقلة تنسج خلايا ليدج، واحتقان في الاوعية الدموية، وتغلظ نواة الخلايا القاعدية المولدة للنطف، وحدوث نزف بين النيبات المنوية، وتشن الغلالة البيضاء، وتوسف مكونات النيبات المنوية بشكل انقاض حلوية.

الاستنتاجات: ادى الباراسيتامول الى تغيرات مرضية في انسجة خصيتي الجرذان. تمثلت هذه التغيرات بتوقف تام لعملية تكوين النطف وفقدان المراحل التطورية لهذه العملية. بينما المستخلص الكحولي لأوراق التين امتلك تأثير وقائي ضد تأثير الباراسيتامول وازالة معظم التأثيرات المرضية وفي النهاية ، اعاد عملية تكوين النطف الى حالتها الطبيعية.