



## Tikrit Journal of Pure Science

ISSN: 1813 – 1662 (Print) --- E-ISSN: 2415 – 1726 (Online)

Journal Homepage: <http://tjps.tu.edu.iq/index.php/j>



### The effect of Some hepatic worms on adult sheep liver

Balqees Mohamed sulieman , Idrees khalaf Thamer , Omaila Ibrahim Mahmood

Department of Internal Medicine, College of Veterinary Medicine, Tikrit University, Tikrit, Iraq

<https://doi.org/10.25130/tjps.v25i6.304>

#### ARTICLE INFO.

##### Article history:

-Received: 15 / 5 / 2020

-Accepted: 28 / 8 / 2020

-Available online: / / 2020

**Keywords:** *fasciola hepatica* , histological changes, adult sheep.

##### Corresponding Author:

**Name:** Balqees Mohamed sulieman

**E-mail:** [blkesedke@gmail.com](mailto:blkesedke@gmail.com)

**Tel:**

#### ABSTRACT

The current experiment previous from beginning of September 2019 until March 2020 and a It checkup 165 liver tissue of adult sheep from both sexes slaughtered in slaughterhouses and butchers' stores in Salahuddin Governorat.

Since the liver is one of the important organs where most of the body's metabolism activities occur in it, as it performs the metabolism of protein, metabolism of fats and the formation of bile, and the liver works to reduce toxic substances entering the body and plays a role in the immune response of the body so diseases that Liver disease affects animals directly [1].

The results are shown through macroscopic and histological examinations in the examined livers, presence of both acute and chronic phases. Where the chronic phase was the dominant, and showed infiltration of the inflammatory cells represented by lymphocytes, macrophages, plasma and eosinophils, as well as many necrotic foci, characterized by proliferation of fibrous tissue and thickening and expansion of the bile ducts compared to liver. The natural non-infection liver without *fasciola hepatica* whose cells are in form of polygonal rows in a radial order and each hepatic cell has a dark colored spherical nucleus.

#### Introduction

The scientific classification of *Fasciola* According to [2] as following:-

Kingdom: Animal

Phylum: Platyhelminthes

Subphylum: Neodermata

Class: Trematoda

Subclass: Digenea

Superorder: Anepitheliocystida

Order: Echinostomida

Suborder: Echiostomata

Superfamily: Echinostomatoidea

Family: Fasciolidae

Genus: *Fasciola*

Species: *Fasciola hepatica* [3].

Species: *Fasciola gigantica* [4].

The animal parasitic diseases prevalent in most countries is hepatitis [5].

Hepatitis is one of the diseases that infect sheep, cattle, and goats, as well as human. It also causes long-term damage and it may reduce the ability to fight diseases [5].

This unhealthy condition is a parasitic disease that is attributable to digenean worms of the genus *Fasciola*, The other important species *Fasciola hepatica* [3] and *Fasciola gigantica* [4,7], The Worms settle in the hepatobiliary system of definitive host and are seldom found in other locations of anatomy of definitive carrier of parasite[8].

This species of worms are formed in the pipe line liquid of ruminants, and are characterized by their flat-leaf-shaped form in a grayish-brown color and surrounded by skin[9], The front part is wider than the posterior and is characterized by the presence of the anterior cone and two oral sucker and ventral sucker [10], The gastrointestinal tract consists of the mouth, which is located in the middle of the oral volume and leads to the esophagus is in turn surrounded by the muscular pharynx. This part of the gastrointestinal is connect to the cecum and ends with blind branches . this tract Has no anus [11]. The female heterosexual female genital worms lie near the ventral and male genitalia near the center of the body [12].

The susceptibility of infection to the *fasciola* parasite varies according to different types of hosts. The severity of infection depends on several factors, including the immune status of the animal, the nature of the liver tissue, the type of animal, the age and nature of animal feeding, and the number of infectious stages ingested by the final host [13]. The researchers classified the disease, depending on the length of exposure and the clinical symptoms of the disease in to three phases (acute, subacute and chronic)[14,15]. It must be taken into consideration that the acute histoplastic changes showed the presence of fibrous inflammation around the capsule and damage and destruction of hepatic cells with hemorrhagic pathways. The immature larval migration pathways within the liver board and infiltration of neutrophil and eosinophil cells and areas of worm migration appear as necrosis scars. As for The subacute phase, it has been identified by the presence of hemorrhagic methods, healing scars, biliary ductal hyperplasia and infiltration of inflammatory egg cells, while the chronic phase is a continuation of the acute phase, where adult worms settle in pipe line liquid and are recognized by thickening and expansion of the bile ducts and histologically. It is noticed that most liver tissue is replaced by Sage Levy and also infiltration of white blood cells of a single cell nucleus and eosinophils with thickening hepatic veins Baabism.[16].

one of the symptoms of the disease is sudden death of the acute condition, the other important symptoms of the chronic condition are wasting, poor wool, poor milk production, paleness of mucous membranes, frowning between the jaws, diarrhea and severe anemia [17]. Given the fact that sheep constitute an important aspect of livestock that requires care and attention and is considered as one of economic animals in Iraq, and because of damage and breakdown of these worms to livers of sheep and economic damage and losses, our study was conducted to reveal pathological, macroscopic changes in liver of liver infected with liver *fasciola hepatica*.

### Materials and methods

The difference in the nature of liver tissue between hosts causes a difference in acceptance of infection among animals. Sheep liver has the advantage of containing fibrous tissue compared to that of cows and buffalo, which indicates the possibility of direct relationship with host resistance [19].

Liver samples were collected from sheep slaughtered with regular visits to slaughterhouses at a rate of twice a week, from beginning of September 2019 until March 2020 and a It checkup 165 liver tissue of adult sheep from both sexes slaughtered in slaughterhouses and butchers' stores in Salahuddin Governorat. The liver was carefully examined for any physical lesion by palpation of the organs [1]s, and liver samples were taken and stabilized in a 10% neutral formalin solution for the purpose of studying

Histological changes [10]. The histological sections were prepared using the method [18]: As written by: The tissue slices were dyed with hematoxylin and eosin by immersing both phasies of slices in zeol for both half an hour in each stage to remove the wax. After that the slices were passed in descending concentrations of ethyl alcohol starting from 100-90-80- 70%, then submerged in distilled water 15minutes, then dyed with hematoxylin for 10 minutes. The tissue slices were washed by distilled water for a minute and then dyed with an eosin dye for two minutes and then they passed through ascending concentrations from alcohol to pure alcohol then xylene half an hour and then a drop of DPX was added, and finally the slide cover is put. The slides were examined using Olympus microscope A Histopathological changes were recorded and photographed using a USD 5 mega / pixel tray-origin microscope camera equipped with a scope image 9. image analysis software.

### Results and discussion

The results of histopathological changes that were observed in liver, infection with *fasciola hepatica*, showed lesions concentrated in liver and bile ducts. The accompanying changes in the chronic phase were characterized by paleness of liver color, irregular edges of the liver, and severe bleeding and subsequent tissue scarring that occurred in paranchemia (Figure 1). Those results are consistent with what mentioned [19], There is an appearance of bleeding on the surface of liver with precise hemorrhagic foci on the parietal capsoler which is considered as a place of entrance of the previously puerile parasite [11].

As Compatible with previous research [14] evidence that the liver is rigid and rigid with enlargement and thickness in the bile ducts and their inflammation in addition to the existence of adult worms in the pipeline, and it may be due to interaction of immune cells and lymphocyte infiltration and macrophages, which It works to replace the fibrous tissue of the dead areas during later stages of infection as shown in figure (1), due to gradual irritation secretion metarial from parasite bile ducts, such as excessive bile ductitis, thickening of duct wall and their emergence clearly with an expansion of the bile cavity and containment of these ducts with liquid viscous materials from Mocha Yeh with yellow material and wall thickening of the yellow bag and large size. [21] Hepatic nodules and multiple foci have also been observed in livers of sheep, which may be caused by an abnormal immune response of host against dead larvae or worm products retained in the liver. These results are consistent with the results of [21] who stated that the widespread hyperplasia of the bile ducts due to the constant irritation of adult worms [1]. In addition to these facts [22] stated that the hepatopathy occurs as a reaction to acute infection caused by mechanical damage to larva. Remote roaming in the liver.

The mesenteric lymph nodes are enlarged with edema in opening ooze edematous. The liver lesion usually caused by bacterial infections and subsequent degeneration of neutrophils. Later they are surrounded by a fibrous capsule. As well as, reason may be a signal to the reaction of the host against parasitic infection and continuous irritation along with destruction paranchemia which is guided by extensive hemorrhagic lesions and immunological reactions. This result current study is consistent with [22].

Tissue changes were characterized by observation of fibrous cells with inflammation cells (WBC) through non-adult worms from chronic hepatococcal worm infection in this study, and this may be an indication of granulomatous hepatitis resulting from macrophage aggregations and epithelial appearance with accompanied epithelial appearance predominantly in lymphocytes and plasma cells [1].

The hyperplasia of epithelium of the bile ducts is attributed to the toxic substances *F.hepatica* that cause changes in the structure of the ductal cell structure in an unlimited way and may be destructive. In fact the existence of adult worms within the lumen of the bile ducts leads to perpetual irritation and hyperplasia. as shown in figure (2)

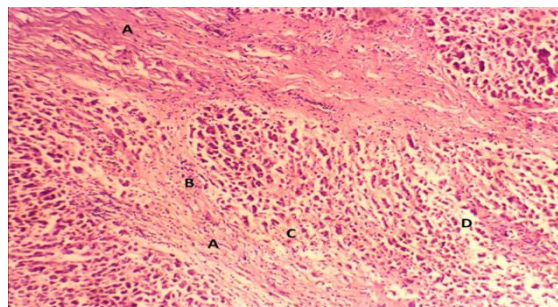
The gradual mechanical irritation of hepatocytes in infection with chronic liver worms promotes the destruction of hepatocytes with the formation of fibrous connective tissue and leads to cirrhosis and infiltration of single-core cells. It may be due to enzymes such as proteins and toxins produced by worms and later become fibrosis and cirrrous and these researchers agree with what [1].

In the present study the granular lesion indicates the limited focal grouping of epithelial cells and single-core cells, which are coated with fibrous connective tissue of the capsule. This lesion is an immune response of the host against the eggs of worms or it may be dead larvae trapped in the liver as indicated by [23].

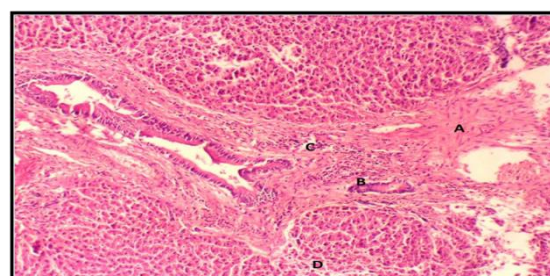
The places of movement and wandering of non-adult worms within the liver board were distinguished as they represent the acute phase. These place were characterized by their congestion with the presence of diffuse hemorrhagic spots that lead to damage and breakdown of its tissues and thus to reduce anaerobic oxygen, which allowed closterid to multiply by divorce its toxins and induce cell necrosis [14].

Histological test also showed up the existence of many cells of citrus eosinophils with a small number of lymphocytes with associated hemorrhages and edema in hepatic worms. The acute condition is associated with what was recorded [21]. The increase of eosinophils is due to an allergy to the foreign protein of the parasite and this part from the state of

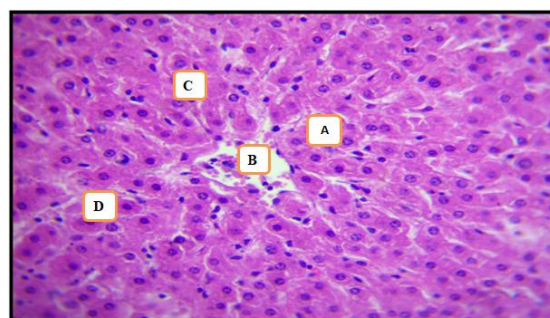
immune phenomena, extensive damage to the liver cells with hemorrhagic red tracts of the liver and aggregation of the liver vessels during the immigration stage of larva. Clotting occurs on areas of the local vein produced by the migration and is consistent with what was recorded [20].



**Fig. 1: C.S. in sheep liver (A) proliferation of fibrous tissue between the lobules of liver , (B) infiltration of single-cell inflammatory cells , (C)necrosis of hepatocytes , (D)expansion of sinusitis (H&E,100X)**



**Fig. 2: C.S. of sheep liver : (A) proliferation of fibrous tissue in the portal area, (B) the multiplication of bile ducts (a compensatory process) , (C) infiltration of single-cell inflammatory cells , (D) hepatic cell necrosis (H&E,100x)**



**Fig. 3: C.S.. of sheep liver (control group): (A) proliferation of fibrous tissue in the portal area , (B)the multiplication of bile ducts (a compensatory process) , (C) infiltration of single-cell inflammatory cells , (D) hepatic cell necrosis (H&E,400X)**

### Acknowledgements

We would like to thank College of Veterinary Medicine and the College of Science, Tikrit University, Iraq for their support this work



## References

- [1] Sohair, IB.; and Eman, MN. (2009). Histopathological and bacteriological study on liver affected with *Fasciolasis* in Cattle . *Egy. J. comp. path .and clinic . path* , 22(1):19-45.
- [2] Lotfy, W.M.; Brant, SV.; DeJong, RJ.; H Le, T.; Demiaszkiewicz, A.; Rajapakse, RP.; Perera, VB.; Laursen, JR.; and Loker, ES. (2008). Evolutionary origins, diversification, and biogeography of liver flukes (Digenea, Fasciolidae). *Am. J.Trop. Med. Hyg.*, 79: 248–255 .
- [3] Linnaeus, C. (1758). *Systema naturæ per regna tria naturæ, secundum classes, ordines, genera, species, cum characteribus, differentiis, synonymis, locis*. Tomus I. *Editio decima, reformata*. – pp. (1–4), 1–824. Holmiæ.(Salvius).
- [4] Cobbold, T.S. (1855). Description of a new trematode worm (*Fasciola gigantica*). *Edin N Phil J NS* 2:262–266.
- [5] Aliyu, A. A.; Ajogi, I. A.; Ajanusi, O. J. and Reuben, R. C. (2014). Epidemiological studies of *Fasciola gigantica* in cattle Zaria, Nigeria using coprology and serology. *J. Pub. Healt. and Epi.*, 6(2): 58-91.
- [6] Zeynab, A.; Mas – coma, M.; Bouman, A.S.; Boenke, M.; and Thomas, S. (2018) . *Fasciola hepatica* eggs in paleofaeces of the person onager Equus hemionus onager , A donkey from chenrabad irchaeological site, dating back to the sassanit Empire ( 224 – 651 ) AD infection , *Genetics and evaluation* 62 : 233-243 .
- [7] Paula, M.M.; Fernanda, H.J.; and Ana, J.P. (2012). Genetic characterization of Portuguese *Fasciola hepatica* isolates. *Faculdade Ciencias e tecnologia* . Universidade Nova De Lisboa 1-3 .
- [8] Nguyen, T.G; Van De, N.; Vercruysse, J.; Dorny, P.; and Le, TH. (2009). Genotypic Characterization and Species Identification of *Fasciola spp*. With Implications regarding the isolates infecting goats in Vietnam. *Exp Parasitol*. 123:354-361.
- [9] Robinson, M. W.; and Dalton, J. P. (2009). Zoonotic helminth infections with particular emphasis on *fasciolosis* and other trematodiasis. *Philosophical Transactions of the Royal Society B: Biological Sciences*, 364(1530): 2763–2776.
- [10] Mary, B.A.; Wahba, A.A.; and Marwa, I. (2015). Molecular characterization of *Fasciola spp*. in sheep and cattle . *Animal Health Research Journal* Vol. 3No.( 2): 67-75.
- [11] Kotpal, RL. (2012). *Modern Text Book of Zoology: Invertebrates*. New Delhi: *Rastogi Publications*. p. 338. ISBN 978-81-7133-903-7.
- [12] WHO .(1998).Triclabendazole and *Fascioliasis* A new drug to combat on Age-old disease , *Whold Health Organization. disease Fact sheet* N19.
- [13] Andrews ,SG .(1999).The life cycle of *Fasciola hepatica* : In *Fasciolasis* , Dalton JP (1999), *Dalton School of Biotechnology*, Dublin , pp. 1-21.
- [14] Sayed, S.M.; Gehan, M.S.; and Neveen A.E. (2008). Clinico diagnostic studies on hepatic affections of aged buffaloes. *Assi. Vet. med. J*.54(117):310-328.
- [15] Underwood, W. J.; Blauwiekel, R.; Delano, M. L.; Gillesby, R.; Mischler, S. A.; and Schoell, A. (2015). Biology and Diseases of Ruminants (Sheep, Goats, and Cattle). In *Laboratory Animal Medicine (Third Edition)* (pp. 623-694).
- [16] Kitila, D. B.; and Megerssa, Y. C. (2015). Pathological and serum biochemical study of liver fluke infection in ruminants slaughtered at ELFORA Export Abattoir, Bishoftu, Ethiopia. *Global Journal of Medical Research*.
- [17] Raza, M.A.; Murtaza, S.; Bachaya, H.A.; Qayyum, A.; and Zaman, M.A. (2012). Point Prevalence of *Toxocara vitulorum* in large ruminants slaughtered at Multan abattoir . *pak Vet j*.30:242-244.
- [18] Al-Hajj, H.A. (2010). Optical microscopy, theory and practice. Al Masirah House for Publishing, *Distribution and First Printing*, Amman Jordan, p. 234.
- [19] Okaiyeto, S.O.; Salami, O.S.; Danbirni, S.A.; Allam, L.; and Onoja, I.I. (2012). Clinical, gross and histopathological changes associated with chronic *fasciolosis* infection in a dairy farm. *Journal of Veterinary Advances*, 2(8): 444-448.
- [20] Borai, G.M.; Nagi, A.A.; Gab-Allah, S.M .; El-Mashad, I.A.; and Moustafa, A.S. (2013). Comparative Pathological Studies on Parasitic Affections of liver in Farm animals . *Msc . thesis ; pathology department, faculty of Vederinary Medicine* , Benha University . pp.4-8.
- [21] Talukder, S.I.; Bhuiyan, M.J.; Hossain, M.M.; Uddin, M.M.; Paul, S.; and Howlader, M.R. (2010). Pathological investigation of liver fluke infection of slaughtered Bnjal goats in a selected area of Bangladesh . *Bangi . J.Vet.med* . 8(1):35-40.
- [22] Adrien, M.L.; Schild, A.L.; Marcolonho-Pereira, C-Fiss.L.; Ruas, J.L.; Grecco, FB.; and Raffi, M.B .(2013) . *Fasciolose aguda em bovinos no sul do Barsil* , *Pesq.Vet bars* ., 33(6):23.
- [23] Soulsby, E.J.L . (1982) . *Helminthes Arthropods and protozoa of Domesticated Animals seventh edition* . *Billier , Tindall , London* , pp . 40-52.

## تأثير بعض الديدان الكبدية على أكباد الأغنام البالغة

بلقيس محمد سليمان ، ادريس خلف ثامر ، اميمة ابراهيم محمود

كلية الطب البيطري ، جامعة تكريت ، تكريت ، العراق

### الملخص

استمرت التجربة الحالية من بداية سبتمبر 2019 حتى مارس 2020، وفحصت 165 من أنسجة الكبد من الأغنام البالغة من كلا الجنسين المذبوحة في المسالخ ومحلات الجزارين في محافظة صلاح الدين. بما أن الكبد هو أحد الأعضاء المهمة التي تحدث فيها معظم أنشطة التمثيل الغذائي في الجسم، حيث يقوم بعملية التمثيل الغذائي للبروتين، واستقلاب الدهون وتشكيل الصفراء، ويعمل الكبد على تقليل المواد السامة التي تدخل الجسم ويلعب دور في الاستجابة المناعية للجسم حتى الأمراض التي تصيب أمراض الكبد الحيوانات مباشرة. تظهر النتائج من خلال الفحوصات المجهرية والنسجية في كبد فحص وجود مراحل حادة ومزمنة. حيث كانت المرحلة المزمنة هي السائدة، وأظهرت تسلاً للخلايا الالتهابية ممثلة بالخلايا الليمفاوية والبلاعم والبلازما والحمضات، بالإضافة إلى العديد من البؤر النخرية، التي تتميز بانتشار الأنسجة الليفية وتكثيف وتوسع القنوات الصفراوية مقارنة بالكبد. الكبد الطبيعي غير المصاب بالعدوى بدون اللفافة الكبدية التي تكون خلاياها على شكل صفوف مضلعة بترتيب شعاعي وكل خلية كبدية لها نواة كروية داكنة اللون.