



Sciatic Nerve Regeneration Using Collagen Tubes and Acellular Nerve Transplants in Rabbits (A comparative study)

Ali Ghanim Abdulla , AbdulJabbar Jameel Al-Samarae , Samira Abdulhussain Abdullah

Anatomy Department , College of Medicine , University of Tikrit , Tikrit , Iraq

<https://doi.org/10.25130/tjps.v25i1.224>

ARTICLE INFO.

Article history:

-Received: 9 / 10 / 2018

-Accepted: 20 / 2 / 2019

-Available online: / / 2019

Keywords: nerve graft; autograft; allograft, peripheral nerve injuries. Collagen tubes, biological conduits.

Corresponding Author:

Name:

Samira Abdulhussain Abdullah

E-mail:

Drsamira2018r@tu.edu.iq

Tel:

ABSTRACT

The present study was conducted to evaluate and compare on anatomical bases between the different types of nerve graft, autograft, collagen tubes (natural polymers), and acellular epineurial nerve sheaths (biological conduits), which included acellular rabbit nerve graft and acellular rat nerve graft.

Forty local bred rabbits were used and divided into four groups, each of ten rabbits. Then each group was subdivided again into two subgroups according to time of scarifying, which was after 45 days and 3 months post operation.

All animals were undergone surgical operation on the right thigh and sciatic nerve of 8-10mm section was sectioned at the mid thigh, and the gap was replaced with the previous graft types comparison was made between the right (experimental) and left thighs (control) side. Samples from proximal, middle and distal stumps were taken to evaluate the regeneration process.

The gross results revealed that, most animals developed ulcer formation and others with bone exposure. All animal groups of both periods showed delay latency. All these manifestations appeared as a subsequent of Wallerian degeneration with effects of nerve graft guidance extra cellular matrix, Schwann-macrophage interactions, neurons death and surgical scarring.

Introduction

The peripheral nervous system refers to parts of the nervous system outside the brain and spinal cord. It includes the cranial, spinal nerve[1] their roots and branches, peripheral nerves and neuromuscular junctions. In the peripheral nervous system, bundles of nerve fibers or axons conduct information to and from the control nervous system.

Treatment of peripheral nerve injuries is considered as challenge procedure, in the past there was no definite line of treatment. A lot of cases with peripheral nerve injuries are either missed the diagnosis or found no treatment [2]. Surgical causes of peripheral nerve injuries include acute and chronic causes, the acute surgical causes of peripheral nerve injuries mostly due to simple bone fracture, open fracture, cut wound, traction injuries, crushed injuries, or animal bite injuries. The chronic surgical type include either acute nerve injuries with formation of painful neuroma or entrapment neuropathes [2].

It is just over the last years that research synergy between surgical science and the tendency of molecular neurobiology rise again, then the declare was in that, the next advancement in peripheral nerve reconstruction would need a stronger biological basin [3, 4].

The aim of the study was to compare on anatomical base between different types of nerve graft; autograft, collagen tubes (natural polymers), and a cellular epineurial nerve sheaths (biological conduits) experimentally on rabbits in two periods of time post-operation procedure.

Materials & Methods

Forty local bred rabbits weighing (1-1.5) kg were divided randomly into four groups A, B, C and D each group included ten rabbits:

Group A: for autograft, and then subdivided into A₁ & A₂.

Group B: for collagen conduit graft, and subdivided again into B₁ & B₂.

Group C: for a cellular rabbit nerve graft and again subdivided into C₁ & C₂.

Group D: for a cellular rat nerve graft, and subdivided into D₁ & D₂.

Subgroups number (1) from each were sacrificed after 45 days post operation. Subgroups number (2) were sacrificed three months post-surgical operation. Animals were anesthetized by I.M injection of ketamine and xylazine in a ratio of 3:1.

The right sciatic nerve was exposed in each group by dissection of the posterior aspect of the thigh from the sciatic notch to the popliteal region, after careful incision of skin and underlying fascia, and separation of the surrounding tissues using surgical instruments. 8-10 mm segment of sciatic nerve was transected or sectioned at the middle third of the thigh. The transected nerve segment was either restored as an autograft in group (A), or it was replaced by collagen conduits in group (B), or grafted by a cellular rabbit sciatic nerve graft in group (C), or replaced by a cellular rat nerve graft in group (D).

All the surgical procedures were performed under sterilized condition using eye loup of (4x) magnification. Nerve suturing was made as in 8/0 vicryl absorbable sutures. Fascial suturing was made with 3/0 catgut, while skin suturing was made with 3/0 black silk sutures. Animals were housed after operation in cages with normal exposure to day light and night and good feeding and drinking.

1. Autograft surgical procedure in groups (A₁ & A₂):

8-10 mm section of sciatic nerve was resutured using 8/0 vicryl absorbable suture.

2. Collagen conduits procedure in groups (B₁ & B₂):

A bioresorbable collagen membrane for guided tissue regeneration type (B & B Italy) was manually rolled to form a tube with a length of 1.5 cm, to bridge the gap between the stumps.

3. A cellular rabbit procedure in groups (C₁ & C₂):

A total of ten sciatic nerves were removed from white New Zealand rabbits and placed in petri dishes prepared as allograft made a cellular through chemical extraction depending on Marian Sondell protocol [5]. A piece of 1-1.5 cm was taken from the a cellular sciatic nerve segment and sutured as a graft to bridge the gap of the sectioned sciatic nerve in the experimental animals in groups C₁ and C₂.

4. A cellular rat procedure in groups (D₁ & D₂):

The procedure in (3) was followed, but only with the exception of that, the sciatic nerve piece was taken from white albino rats.

Animals dissection:

All animals were survived to their end periods and then sacrificed using intramuscular injection of ketamine then slaughtered in order to take the samples. Three specimens were taken; one from three millimeters above the proximal stump, the second one

from the middle of graft, and the third was taken three millimeters below the distal stump.

Statistical analysis:

All data were presented as a mean and standard deviation (SD). Unpaired T. test was used to compare between the means of various parameters. P-values less than 0.05 ($P \leq 0.05$) was accepted as a significant value, using spss version 17 for determination of significant differences between variables [6].

Results & Discussion

Morbidity and mortality:

Postoperative, all animals were housed and fed routinely and monitored for changes in their appearance, appetite, response to locomotion activities.

There was no apparent severe discomfort, this was an indication to the good tolerance to the operation, because animals behave and eat normally. There was no complications, all the wounds healed primarily. Two animals only died 2 and 3 weeks postoperatively of unknown reason, and only one animal missed. Ulcer started to appear during the 3rd week post-operation in the fore foot, but several attempts were made to overcome such symptoms through preparing antibiotic fucidine bandages.

Damage of peripheral nervous system is surprisingly common and occurs primarily from trauma or a complication of surgery. Although recovery of nerve function occurs in many mild injuries (e.g, crush injury), the outcomes are often unsatisfactory following severe trauma [6]. Nerve injury, repair, their effects on neurons and regeneration are difficult areas to study in human clinical situation because of the inability to obtain tissue samples to elucidate the injury, inflammation, and repair events without causing significant damage to the peripheral nerve and other associated tissues. Therefore, approximately all nerve injury and regeneration researches have taken place in experimental animals mostly in rats [7].

As axons are disconnected from their cell bodies in the distal segment, they are rapidly fragmented by an intrinsic process of self-destruction (Wallerian degeneration), due to loss of axonal contact the myelinating Schwann cells differentiate into an immature phenotype, start proliferating and help in the myelin degeneration [8].

Wallerian degeneration typically triggers a strong neuron inflammatory response in which the Schwann cells are believed to play an important role in, they induce the production of inflammatory cells as macrophages lymphocytes, neutrophils, which reaches a maximum at one day after injury promotes the recruitment of macrophages to the damaged nerves and other immune cells. Wallerian degeneration typically triggers a strong neuroinflammatory response in which Schwann cells are believed play an important role, they induce the production of inflammatory cells as macrophages, lymphocytes, neutrophil, which reaches maximum at

one day after injury, promotes the recruitment of macrophages to the damaged nerves and other immune cells. Moreover, most cells accumulate in the endoneurium of the injured nerve [9].

After sciatic nerve injury, the injury itself leads to a breakdown of the blood-nerve barrier, and fibrinogen can leak into the nerve where it is converted into fibrin [10]. Fibrinogen is not synthesized by nervous system cells but it can enter the nervous tissue when there is leakage of blood-nerve barrier (BNB). BNB disruption is considered a key mechanism of inflammatory demyelination traumatic injuries and autoimmune peripheral nervous system diseases [11].

Cross anatomical observation:

Post sacrificing the animal, in general there was no dislocation of the conduits and grafts in the 45 days and three months groups, and the grafts of both groups were closely adhered to the surrounding fascia and muscles.

A. For the 45 days groups:

1. In autograft group (A_1); there was a good continuity of the regenerated nerve trunk, with no neuroma formation (figure -1).
2. In collagen group (B_1); there was a slight residue of the collagen tube conduits found bridging the gap of proximal and distal stumps (figure -2).
3. In the acellular rabbit group (C_1); there was almost a good appearance and continuity of the repaired nerve trunk with remnants of the sutures and slight neuroma at proximal stump (figure-3).
4. In the acellular rat group (D_1); a good continuity of the repaired nerve but with slight constriction at proximal stump (figure -4).

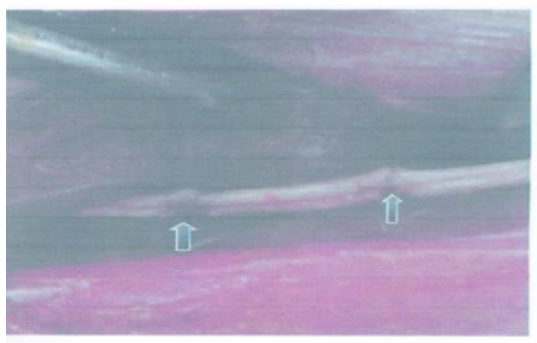


Fig. 1: Autograft operation (black arrows) clarify proximal and distal suturing sites




Fig. 2: Collagen conduit procedure, black arrows show proximal and distal stumps

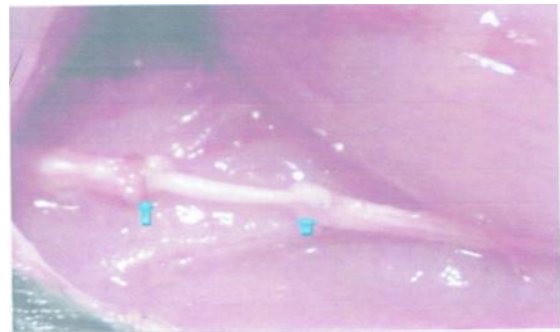


Fig. 3: acellular rabbit graft, blue arrows show proximal and distal stumps



Fig. 4: Acellular rat graft black arrows clarify proximal and distal stumps

B. For the three months group:

1. In the auto graft group (A_2); there was a good appearance and texture of the repaired nerve in a way it is difficult to differentiate between the graft and remaining nerve.
2. In the collagen group (B_2); the texture of the repaired nerve was good, in some cases was with slight neuroma at distal stump, but with complete resorption of collagen conduit, and in one case, there was a residue of collagen conduit.
3. In the acellular rabbit group (C_2); the appearance nerve trunk was of good continuity, but with neuroma either on proximal or distal stumps.
4. In the acellular rat group (D_2); the regenerated nerve trunk appeared of slight good continuity but in one case was recognized constricted, in other case appeared with neuroma on proximal and distal stumps.

Early sensation and foot cleaning:

The loss of general sensation after nerve sectioning is reported in many studies [12, 13]. Colin and Donoff reported that, sensory loss continues to three months post-operation [12]. Guo et.al, [13], proved in experiments that, rats cannot spread their toes in response to puncture till the beginning of third month post-operation. While Gerburg-Khilhoff, et.al; [14] in their experiment showed that rats after sectioning 50 mm of sciatic nerve and bridging the gap using a cellular muscle graft recognized thermosens activity of the digits after 4-6 weeks post-operation.

The present results proved that, rabbits from collagen group (B_2), and from a cellular rabbit group (C_2) have seen cleaning their foot after 6-7 weeks post operation, such events are most likely attributed to collateral nerve sprouting.

Conclusion

The results of the present work clarify the following conclusion:

- 1- Bridging the gap of transected nerve was facilitated by conduits.
- 2- Regenerated axons were traversed to the distal stump.

References

- [1] Snell, RS. Clinical neuroanatomy, 7th ed. Lippincott Williams and Wilkins; 2010. P:13.
- [2] Sunderland, SS. Nerve injuries and their repair: a critical appraisal. New York: Churchill Livingstone. 1991. P:33.
- [3] Sunderland, SS. Factors influencing the course of regeneration and the quality of the recovery after nerve suture. Brain. 1952; 75:19.
- [4] Raffe, MR. principles of nerve repair: biology of nerve repair and regeneration. In: Newton, CD; Nunmarker, DM. Textbook of small animal. Orthopedic. 1985: p504-545.
- [5] Mariann, S; Goran, L; and Martin, K. regeneration of the rat sciatic nerve into allografts made a cellular through chemical extraction. Brain. Res. 1998. 795: 44-54.
- [6] Bryan, JP; Gordon, T; Loverde, JR; Kochar, AS; Mackinnon, AS; Cullen, DK. Biomedical engineering strategies for peripheral nerve repair: surgical application; state of the art and future challenges. Critical reviews in biomedical engineering. 2011; 39(2): 81-124.
- [7] Ijkema, P; Meek, MF; and Gramsbergen, A. transection of the sciatic nerve and reinnervation in adult rats: muscle and endplates morphology. Equine. Vet. J. 2011. 33:41-50.
- [8] Saxon, S; Carnol, P. mechanism of axon degeneration from development to disease. Prog. Neurobiol. 2007. 83: 174-191.
- [9] Elke, Y; Anje, C; Bob, A; Sofie, G; Guillauma, L; Leonardo, AS; Van ginderachter, JOA; Sofie, J. acute injury in the peripheral nervous system triggers an alternative macrophages response. J. neuro-inflammation. 2012. 9:176-195.
- [10] Keterina, A; Wei, MY; Pinar, A; Sidney, S. fibrin inhibits peripheral nerve remyelination by regulating Schwann cell differentiation. J. cell. Boil. 2002; 33:861-875.
- [11] Keiseir, BC; Seifert, T; Giovannoni, G; Hartung, HP. Matrix metalloproteinases in inflammatory demyelination: targets for treatment. Neurology. 1999; 53:20-25.
- [12] Colin, W; Donoff, RB. Nerve regeneration through collagen tubes. J. dent.. res. 1984; 63:987-933.
- [13] Guo, Ly; Zhitao, J; Haiying, Z; Zhang, Xy; Xiaojie, T. immunological rejection of a cellular heterogenous nerve transplant for bridging the sciatic nerve in rats. Neurol. Regen. Res. 2010; 5.
- [14] Gerburg, K; Florian, P; Gerlad, W; Hisham, F. bridging extra-large defects of peripheral nerves: possibilities and limitations of alternative biological grafts from a cellular muscle and Schwann cells. Tissue. Engine. 2005. 11:1004-1015.

إعادة ترميم العصب باستخدام الانابيب الكولاجينية وزراعة العصب اللاخوي في الارانب

علي غانم عبد الله ، عبد الجبار جميل مهدي السامرائي ، سميرة عبد الحسين عبد الله

فرع التشريخ ، كلية الطب ، جامعة تكريت ، تكريت ، العراق

الملخص

أجريت الدراسة الحالية للتقييم والمقارنة على أسس تشريحية بين أنواع مختلفة من زراعة العصب (الزراعة الذاتية، الانابيب الكولاجينية، والغلاف العصبي الخارجي اللاخوي) ومن نوعين: زراعة الارانب اللاخوي وزراعة عصب الجرذ اللاخوي. استخدمت أربعون أرنباً محلياً وقسمت الى أربعة مجاميع، كل مجموعة حاوي على عشرة ارانب. وقسمت كل مجموعة الى مجموعتين ثانويتين وتبعاً لوقت نهاية التجربة والتي كانت 45 يوماً وثلاث اشهر بعد اجراء العملية الجراحية. خضعت جميع الحيوانات لعملية جراحية على العصب الوركي الأيمن، وتم قطع قطعة من منتصف العصب وبطول (8-10) ملم، وتم ملئ منطقة القطع بقطع من أنواع الزراعة النسيجية المذكورة أعلاه. وأجريت المقارنة بين الجهتين اليمنى (التجريبي) واليسرى (السيطرة). اخذت عينات من الجزء القريب والوسط، والبعيد من العصب التي تم قطعها لتقييم عملية إعادة تكوين العصب. النتائج العينية أظهرت ان معظم الحيوانات أظهرت لديها تقرحات والبعض الآخر اظهر تعرض العظم. جميع حيوانات التجربة أظهرت تأخر في إعادة الوظيفة. وكل هذه التغيرات جاءت نتيجة لتحلل والر (Wellerian degeneration)، وتأثير زراعة العصب لاعادة ترميمها، إضافة الى زيادة المادة بين خلوية، وتداخل خلايا البلعمة مع خلايا شوان، وموت الخلية العصبية والندب الجراحية المتكونة.