



## Physiological and histological study of the effect of *Cumin Cuminum* watery extract and vitamin E on the male reproductive system in rats exposed to oxidative stress

Othman Aeed Saleh Alfahdawi<sup>1</sup>, Muneef Saab Ahmed Aljanabi<sup>1</sup>, Treefa Farouq Ismail<sup>2</sup>

<sup>1</sup> Department of Biology, College of Education for pure Science, University of Tikrit, Tikrit, Iraq

<sup>2</sup> Department of Biology, College of Education, University of Salahuddin, Tikrit, Iraq

### ARTICLE INFO.

#### Article history:

-Received: 4 / 12 / 2017

-Accepted: 15 / 1 / 2018

-Available online: / / 2018

**Keywords:** *Cuminum cyminum*, Testis, Oxidative stress, Testosterone, LH, FSH

#### Corresponding Author:

**Name:** Othman Aeed Saleh

#### E-mail:

[othmanaheed94@gmail.com](mailto:othmanaheed94@gmail.com)

**Tel:** +964 7807711505

#### Affiliation:

### Abstract

This study was conducted to investigate the effect of watery extract of Cumin plant (200 mg/kg B.W.) on some physiological and histological parameters of the male reproductive system in white albino rats exposed to oxidative stress by Hydrogen peroxide (H<sub>2</sub>O<sub>2</sub> 0.5%). Thirty adult male rats weighting about (200-250 g) and 10-12 weeks age were used in the present study and divided into (5) groups, 6 rats per group, group1: serve as a control group and given normal diet with drinking water, group2: Administrated H<sub>2</sub>O<sub>2</sub> 0.5% with drinking water, group3: Given Cumin extract (200 mg/kg B.W.) through oral tubular feeding + H<sub>2</sub>O<sub>2</sub> (0.5%), group4: Given Cumin extract (200 mg/kg B.W.) alone and group5: Administrated Vitamin E 500 (mg/kg B.W.) with H<sub>2</sub>O<sub>2</sub> 0.5%, the experiment were continued 30 days for all groups. The results of the current study showed that treatment with H<sub>2</sub>O<sub>2</sub> resulted significant increase (P<0.05) in malondialdehyde, significant decrease (P <0.05) in glutathione and significant decrease (P<0.05) in serum testosterone compared with control group, While the treatment with H<sub>2</sub>O<sub>2</sub> plus the water extract of Cumin seeds (200 mg/kg B.W.) showed a significant decrease (P<0.05) in malondialdehyde, a significant increase in glutathione and a significant increase in testosterone in the serum compared to the H<sub>2</sub>O<sub>2</sub> group. As for ectopic tissue, H<sub>2</sub>O<sub>2</sub> has resulted in satisfactory tissue changes, while water extract (200 mg/kg) with H<sub>2</sub>O<sub>2</sub> resulted in little improvement of the testes tissue. The water extract of Cumin plant acts as an antioxidant through its important role in curbing the harmful effects of some types of free radicals within the body and thus repair the damage in most of the physiological and histological changes and functions of the male reproductive system of rats with exposure to oxidative. Histological section of the testes in the rats treated with vitamin E and H<sub>2</sub>O<sub>2</sub> observed repair of the cells lining the seminiferous tubules with the continuation of the formation of sperm, on the other hand the results showed that giving the Cumin for a long periods lead to reduce the level of hormone testosterone.

### Introduction

Cumin is a multi-purpose aromatic plant used worldwide as a food additive and represents the popularity of spices to flavor different preparations, including cheese, pickles, soups, beans, and alcoholic beverages. It is also used in traditional medicine, especially in veterinary medicine [1]. Cumin seeds have shown anti-oxidant properties, as well as useful in indigestion, diarrhea and cholera, as a treatment

against indigestion and colic [2], also Cumin seed oil used as active oil against microbes [3]. These medicinal benefits were generally referenced to their content of active ingredients and strong action such as terpenes, phenols, and flavonoids, it also contains essential fatty acid and various classes of compounds, including terpenes, alcohol, phenols and aldehydes more precisely known as aldehyde Cumin:

cuminaldehyde, eugenol, B-benin and some other minor compounds [4]. The botanical kingdom is the actual source of most of the drugs and other active pharmaceutical molecules that are waiting to be discovered. Over the past decade, the therapeutic use of herbal medicines has gained momentum worldwide due to the high toxicity of many chemically manufactured pharmaceuticals, resulting in a sudden increase in the number of herbal medicine manufacturers [5]. The cumin product has demonstrated an active antioxidant capacity, with the ability to suppress free radicals and fatty peroxides [6]. It has the ability to reduce cholesterol levels in plasma for diabetic rats. [7]. *Cuminum cyminum* was used as an antioxidant in male rats with oxidative stress induced by 0.5% hydrogen peroxide by measuring the level of malondialdehyde (MAD), GSH, and testosterone.

## Materials and Methods

### Animals Housing and Experimental Design:

Thirty adult male albino rats weighting about (200-250 g) were used in the present study and divided into (5) groups, 6 rats per group, group1: serve as a control group and given normal diet with drinking water, group2: administrated  $H_2O_2$  0.5% with drinking water, group3: given Cumin extract (200 mg/kg B.W.) through oral tubular feeding +  $H_2O_2$  (0.5%), group4: given Cumin extract (200 mg/kg B.W.) alone and group5: administrated Vitamin E 500 (mg/kg B.W.) with  $H_2O_2$  0.5%, the experiment were continued 30 days for all groups.

### Collection of Plant and Preparation of Extract:

Cumin seeds were obtained from the local market in Erbil city; they were exposed to fresh air away from the sun until they dried and were grinded and stored in transparent plastic containers, sealed at room temperature in conditions without moisture until preparation of the extract. The cold water extract of Cumin seeds was prepared based on [8].

### Blood Sampling:

At the end of each experiment, the animals were fed for 24 hours and then anesthetized with ketamine and xylazine for several minutes, after that the front and hind limbs of the animal were fixed with pins. blood samples were taken directly from the heart by cardiac stenosis, collected about 8-10 ml of blood, placed in Test tubes free of anticoagulants left for about a quarter of an hour at room temperature (25) In the centrifuge at 3000 / rpm for 15 minutes and take serum, and kept at (-20 °C) in new, clean plastic tubes (Plane Tubes) until required biochemical tests were carried out.

### Dissection and Removal of Organs:

Testis was pulled using special forceps and removed with scissors at the level of the groin duct, and then placed in a Petri dish containing the saline salt solution (0.9% NaCl) to separate it from the surrounding grease, And were kept in formalin at a concentration of 10% for the conduct of tissue study.

### Physiological Tests

### Determination of Serum Glutathione (GSH):

The concentration of glutathione in the serum was estimated using the Ellmans detector method [9]. By mixing an equal volume of 150 microliters of serum and Sulfosalicylic acid solution at 4% concentration, 150 microliters were removed from the leachate to a test tube, added to 4.5 ml of the Ellmans 0.1 mMol, and left for 5 minutes. The solubility of the solution was recorded using a spectral device at a wavelength of 412 nanometers. The samples are placed in the water bath at 100 ° C for 15 min. The samples are then cooled and placed in the centrifuge for 5 min at 2000 ppm. Absorption is performed at a wavelength of 532 nm using an optical spectrometer.

### Determination of Serum Malondialdehyde (MDA):

Thiobarbituric acid (0.375 gm) was used and mixed with hydrochloric acid 0.25m (Thiobarburic acid 15%). The concentration of malondialdehyde (MDA), a product of the peroxidase process, was measured as an indicator of this process; the measurement depends on the interaction between lipid peroxides, especially Malondialdehyde, with TBA in a pH-based medium [1].

### Estimation the Level of Luteinzing Hormone:

The level of the LH hormone was estimated by following the steps attached to its prepared measurement kit and according to the instructions of the ELISA manufacturer [11].

### Estimating the Level of Follicle Stimulating Hormone:

The level of the FSH hormone was estimated by following the steps associated with the test kit as per the instructions of the ELISA manufacturer [12].

### Estimate the Level of Testosterone:

Testosterone concentration was measured by following the steps accompanying the test kit and the ELISA manufacturer's instructions [13]. The basis for measurement of the male hormone in the ELISA device is based on the principle of competition between fixed amounts of the hormone in the sample Testosterone-HRP For the rabbit anti Testosterone by antibodies associated with the hormone.

### Calculation of the Epididymal Content of the Sperm (sperm concentration):

The left part of the left larvae of each animal was crushed with 5 mL of NaCl 0.9 by a hand mixer. The mixture was kept in the refrigerator at 4 ° C for 24 hours to allow the sperm to separate from the walls, then take 1 ml of this mixture In addition, 7 ml of the neutral solution was added, and the sample was then placed into the blood-cell count by optical microscopy. The sperm were counted in 25 squares [14].

### Histological Sections Preparation:

Samples of testes were directly fixed in 10% buffered formalin for 24 hours and then processed for paraffin method by dehydrating through ascending concentrations of ethanol (50%, 70%, 95% and 100%), cleared in xylene, infiltrated in paraffin wax

and finally embedded in paraffin wax. Sections were cut at 5µm thickness with a rotary microtome (Hunting Don, Bright.UK). The sections were stained by hematoxylin and eosin (H&E) method [15].

#### Statistical analysis:

The results were statistically analyzed using the Statistical Analysis Package for Social Science (SPSS). In order to extract the differences between the experimental groups with emphasis on these differences by extracting the standard error (Stander Error) SE Statistical analyzes were conducted according to Duncan and others [16].

#### Results and discussion

#### Effect of Different Treatments on the Concentration of Glutathione:

The level of glutathione showed significant decrease in serum of H<sub>2</sub>O<sub>2</sub> treated group when compared to the control group, while the treatment of rats with H<sub>2</sub>O<sub>2</sub> with the water extract of Cumin seeds (200 mg/Kg B.W.) showed a significant increase in serum glutathione compared with the H<sub>2</sub>O<sub>2</sub> group. The water extract of Cumin seed (200 mg / kg B.W.) was significantly higher than the H<sub>2</sub>O<sub>2</sub> group. The vitamin E and H<sub>2</sub>O<sub>2</sub> groups were similar when compared with the control group (Fig 1).

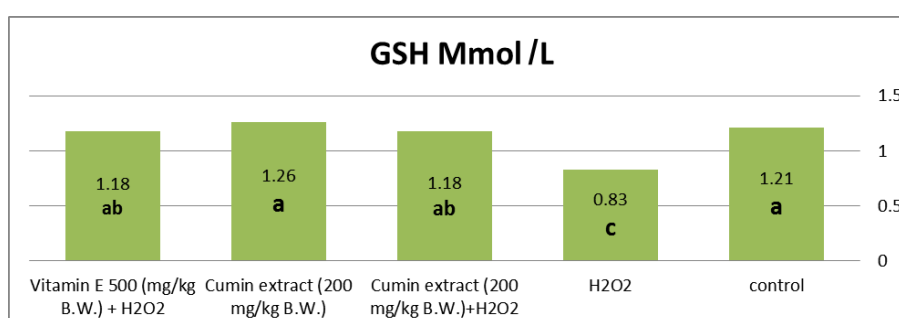


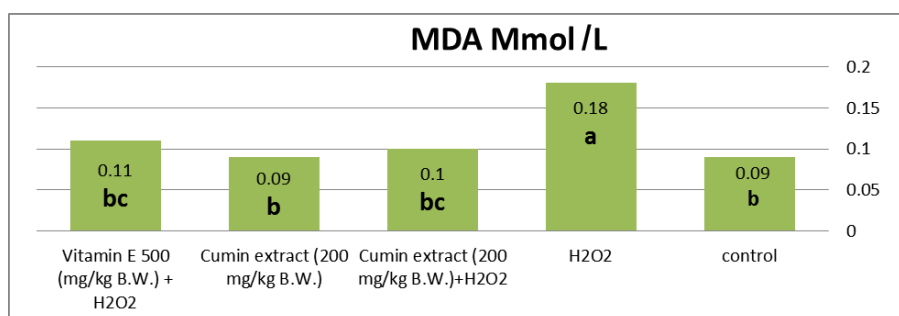
Figure (1): Effect of cumin (200 mg/kg B.W.) in the level of glutathione in male rats exposed to oxidative stress with H<sub>2</sub>O<sub>2</sub> (0.5%).

The level of glutathione decreased significantly in rats exposed to H<sub>2</sub>O<sub>2</sub> compared to the control group according to [17,18]. The low level of glutathione may be attributed to several reasons including increased consumption of glutathione, Non-enzymatic in the removal of free radicals and their products and then transforms from the active form to the inactive form of glutathione disulfide, The sulfur group in the synthesis of glutathione is a well-reduced factor as hydrogen atom is easily released due to the weak sulfur-hydrogen (SH) [19]. The reason for lowering the level of glutathione may also be due to a deficiency in the raw materials of its structure, especially the helper enzyme (the reduced form), nicotine Amadine adenine deoxyribethide phosphatase, which is the catalyst for the action of the enzyme Glutathione reductase, which works to restore the effective form of glutathione of the ineffective form [20], or may be due to the reduction of glutathione to the lack of appetite in animals because of treatment H<sub>2</sub>O<sub>2</sub> Lead to a decrease in levels of dietary antioxidants. The study showed that exposed rats to H<sub>2</sub>O<sub>2</sub> with the water extract of Cumin

seeds led to a significant increase in the level of glutathione in the serum, which may be due to cumin containing effective antioxidant compounds such as cuminaldehyde aldose reductase and a glucosidase [1,2,21]. Vitamin E with H<sub>2</sub>O<sub>2</sub> is a powerful antioxidant that increases the effectiveness of a number of antioxidant enzymes including catalase, which destroys H<sub>2</sub>O<sub>2</sub> and converts it into a water molecule [22].

#### Effect of different treatments on the concentration of Malondialdehyde (MDA)

The treatment of male rats with H<sub>2</sub>O<sub>2</sub> resulted in a significant increase of (P<0.05) in serum malondialdehyde compared with the control group, while the treatment of rats with H<sub>2</sub>O<sub>2</sub> with the water extract of Cumin seeds (200 mg/kg B.W.) showed a significant decrease in serum malondiadealdehyde compared with H<sub>2</sub>O<sub>2</sub> group. The water extract of Cumin seed (200 mg/kg B.W.) was significantly lower than the group of H<sub>2</sub>O<sub>2</sub>. There was significant loss of vitamin E and H<sub>2</sub>O<sub>2</sub> when compared with control group H<sub>2</sub>O<sub>2</sub>. (Fig. 2).



**Figure (2): Effect of Cumin (200 mg/kg B.W.) in the concentration of malondialdehyde in male rats exposed to oxidative stress with H<sub>2</sub>O<sub>2</sub> (0.5%).**

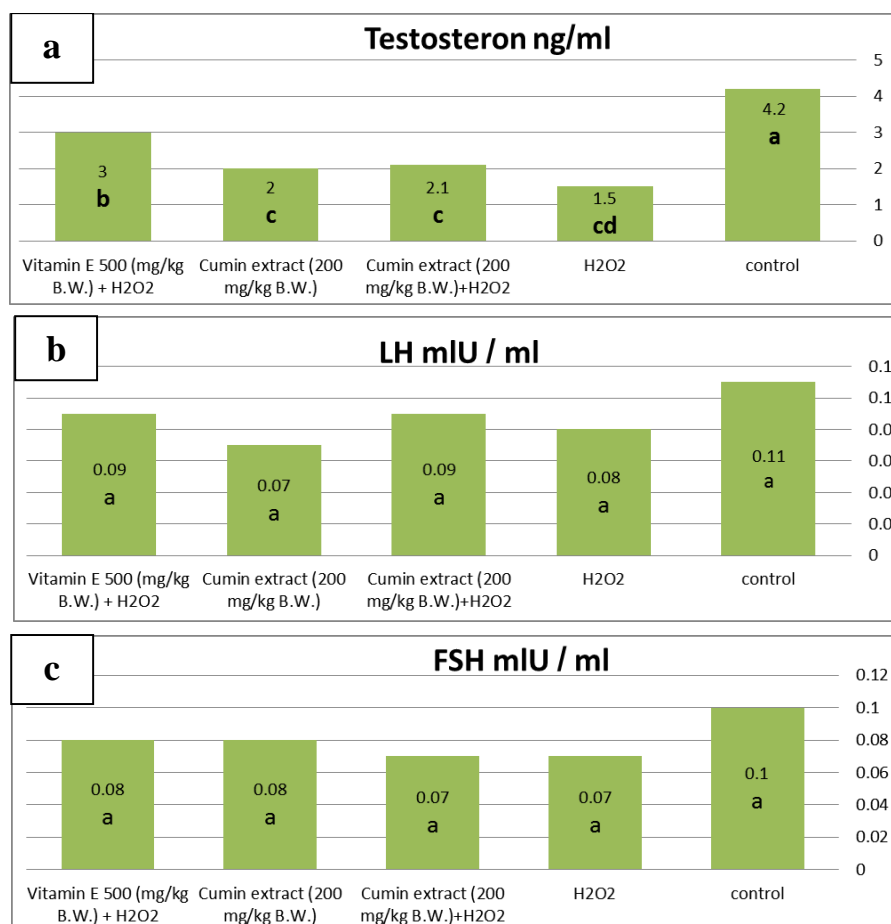
The results of the present study indicate that the oxidative stress induced by H<sub>2</sub>O<sub>2</sub>(0.5%) with drinking water has lead to a significant increase in serum MDA levels for male rats compared to control group. These results are consistent with the study of [17,18]. Malondialdehyde is one of the most important end products of lipid peroxidation resulting from free radical interactions with the molecules of biochemical compounds. The high level of MDA may be due to oxidative stress by H<sub>2</sub>O<sub>2</sub> which leads to the generation of free radicals. This oxidation of fat in the cellular membranes as the unsaturated fatty acids of cellular membranes is the most exposed part of free-radical reactions because of the acquisition of double bonds is the main goal of free radicals, MDA produces oxidation of these fatty acids through free radical reactions in the lipid peroxidation process [23]. This increase in peroxidated fat due to free radicals and the lack of antioxidants leads to oxidative damage that affects the body's various tissues [24].

The treatment of animals exposed to H<sub>2</sub>O<sub>2</sub> with the water extract of Cumin plant showed a significant

decrease in MDA, this means that this extract has reduced the process of lipid peroxidation resulting from the presence of hydrogen peroxide. This is due to its rich content of active ingredients and its strong work such as terpenes, phenols, flavonoids [4,1,25]. Vitamin E reduces the consumption of glutathione and prevents oxidation by reducing free oxygen or free radicals by merging with it or substituting it. Through this interaction, the tocopherol root is transferred to the cell surface and is reduced from the enzyme glutathione peroxide (GSH-px) As it dates back to tocopherol again [26].

#### **Effect of different treatments on Testosterone, LH and FSH hormone:**

A significant increase in the level of testosterone in serum of male rats was observed in all treatments group compared to the H<sub>2</sub>O<sub>2</sub> group, treatment of male rats with H<sub>2</sub>O<sub>2</sub> resulted in non-significant events (P<0.05) in serum LH and serum FSH compared to control group (Fig3).



**Figure (3): The effect Cumin (200 mg/kg B.W.) on the concentration of testosterone hormone, LH and FSH in male rats exposed to oxidative stress by H<sub>2</sub>O<sub>2</sub> (0.5%).**

\* The different letters mean that there is a significant difference at a significant level ( $P < 0.05$ ) between the studied groups.

The results of this study showed a significant decrease ( $P < 0.05$ ) in the serum testosterone concentration of male rats in the H<sub>2</sub>O<sub>2</sub> group compared with control group, this result is consistent with the result of 17 and 27. The treatment with H<sub>2</sub>O<sub>2</sub> leads to a decrease in the levels of sex hormones (testosterone, LH and FSH) compared to the control group which found that the cause of this decline is an increase in the level of free radicals and cause rise in the level of oxidative damage and thus affect the level of hormones which reduces the possibility of fertilization [28].

Decrease in the concentration of sex hormones may be due to the rise of active oxygen classes in the Leydegcells, which inhibit the cloning of the steroidogenic acute protein (STAR) protein in the mitochondrial membranes in the Leydig cells and hydrogen peroxide inhibits the protein expression of Cytochrome P450 side chain cleavage enzyme (P450

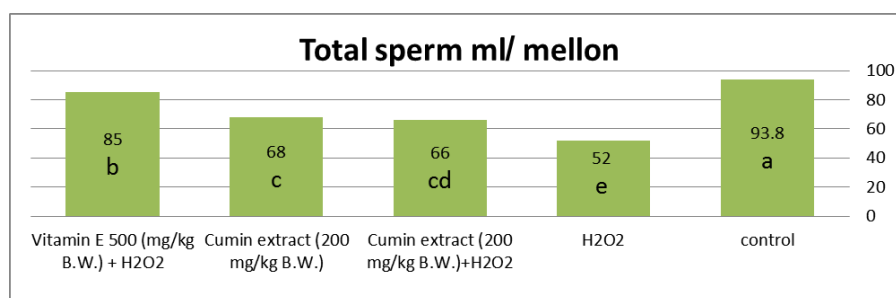
scc), which plays an important role in the process of hormone synthesis within the Leydig cells [29].

The result of the testosterone level in the group which treated with cumin (200 mg/kg B.W.) and H<sub>2</sub>O<sub>2</sub> (0.5%) showed a significant increase compared with the infected control group and significant decrease compared to normal control group which is similar to the result of [30]. The treatment with the water extract of cumin plant (200 mg/kg B.W.) showed a significant decrease in testicular lipid hormone compared with the control group [31].

#### **Effect of different treatments of the total content of sperms in the epididymis:**

It is noted from Figure (4) that there is a significant decrease in the treatment group with H<sub>2</sub>O<sub>2</sub>, the total number of sperm compared with the control. A significant increase was observed in other treatments compared to H<sub>2</sub>O<sub>2</sub> group.





**Figure (4): Effect of Cumin (200 mg/kg B.W.) on the level of total sperm concentration in male rats exposed to oxidative stress with H<sub>2</sub>O<sub>2</sub> (0.5%).**

\* The different letters mean that there is a significant difference at a significant level ( $P < 0.05$ ) between the studied groups.

The results showed that animals treated with H<sub>2</sub>O<sub>2</sub> (0.5%) with drinking water showed a significant decrease in sperm count compared with the control group, which is consistent with the results of the researchers 17 and 26. Exposed the animal to H<sub>2</sub>O<sub>2</sub> lead to oxidative stress resulting in the generation of large numbers of active oxygen species these free radicals affect the tissues and cells of the body and cause pathological changes, including testicular cells and subsequent sex glands [32], these effects may be varied and may affect the inhibition of the sperm formation process of Spermatogenesis. The effective oxygen classes break down the Leydig cells responsible for the secretion of testosterone in the testis, which leads to a reduction in the level of hormone responsible for the functions of the prostate and testes, decrease in the number of sperm as well as the destruction of cells lining the spermatozoa (Sertoli cells and sperm generated cells) and thus impede sperm maturity [33]. The treatment with Cumin extract (200 mg/kg B.W.) was not shown to be effective when given alone in sperm characteristics and had a negative effect [30,31,33]. While it was more effective when given to animals with H<sub>2</sub>O<sub>2</sub>. This may be due to the fact that H<sub>2</sub>O<sub>2</sub> treated animals suffer from oxidative stress due to the generation and reproduction of effective oxygen classes due to H<sub>2</sub>O<sub>2</sub>. This means stimulating the active compounds in plants to act as antioxidants [30,31,34], which works to limit the effect of effective oxygen classes on the cells and tissues of the body, including testicular tissue. The results of this study showed that vitamin E plays a role as an antioxidant. This is reflected in the increase in the number of sperm compared to the control group. This indicates that this vitamin plays a major role in improving reproductive efficiency and increasing fertility for fertility [35,26].

#### **Histological effect of different treatment on testis:**

The normal feature of the testis in the control group were showed in the figure (5-A & B) in which healthy histological structure of rat testis having a germinal epithelium undergoing cell division and

well formed spermatids are seen. while microscopic examination of the testis tissues of the H<sub>2</sub>O<sub>2</sub> group observed many changes included degenerative in some spermatogenic cells, large amount of cellular debris was collected in the tubular cavity, seminiferous tubules showed few spermatozoa in the lumens, detaching of the spermatogonia from the basal lamina in some places, an increase in the space between the seminiferous tubules and decreasing in the number of Leydig cells between them, highly vacuolated spermatogonia also were seen (fig. 5-C & D). These results were agreed with [26,17]. The appearance of degeneration and necrosis was explained by the inhibition of H<sub>2</sub>O<sub>2</sub> for mitochondrial action by disruption of energy production and thus the effect on the sodium pump and the effect of the plasma membrane or the decrease in the pH of the cells through the increase in the production of lactic acid, Produces proteins and thus inhibits the formation of the plasma membrane and the occurrence of necrosis [36]. Microscopic examination of the testis tissue in the group of rats treated with the water extract of cumin (200 mg/kg B.W.) with H<sub>2</sub>O<sub>2</sub> showed a slight improvement compared to the testis tissue in the H<sub>2</sub>O<sub>2</sub> group, also the seminiferous tubules showed improvement in the number and activity of the germ cells and lack of distance between them (fig. 5-E&F) which is similar to the result of [30].

The results in the treatment group of cumin alone (200 mg/kg B.W.) showed that the sperm cells were very effective compared to the control group (fig. 5-G & H), this may be due to the active substances contained in this plant that have resulted in a non-positive result [31,33]. The result of histological section of the testes in the rats treated with vitamin E and H<sub>2</sub>O<sub>2</sub> observed repair of the cells lining the seminiferous tubules with the continuation of the formation of sperm as shown in the figure (5-I&J) and this is agree with the result of [35] which observed that rats treated with vitamin E with fluoxetine showed an improvement in semeniferous tubules and an increase in the number of sperm.

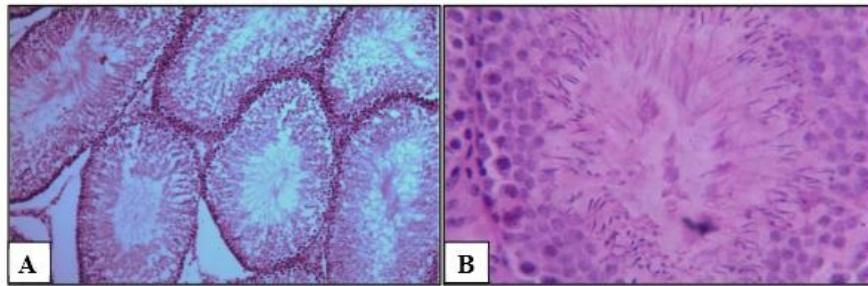


Figure (5-A&B): Section through the testis of control group rats showing normal histological structure of seminiferous tubules with a lot of spermatids in the lumen of the tubules, 100x and 400x respectively, H&E.

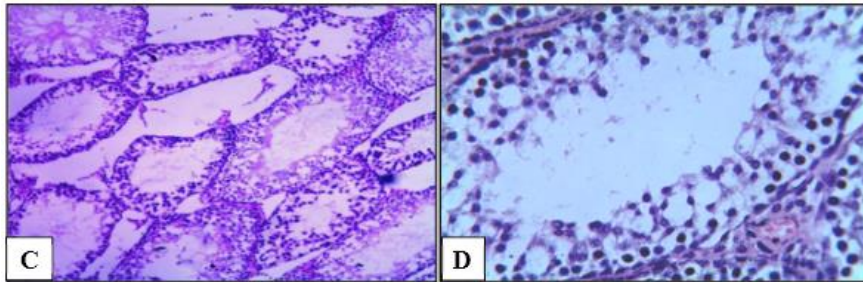


Figure (5-C&D): Section through the testis of H<sub>2</sub>O<sub>2</sub> group rats showing empty lumen of seminiferous tubules, different vacuolated spermatocytes 100x and 400x respectively, H&E.

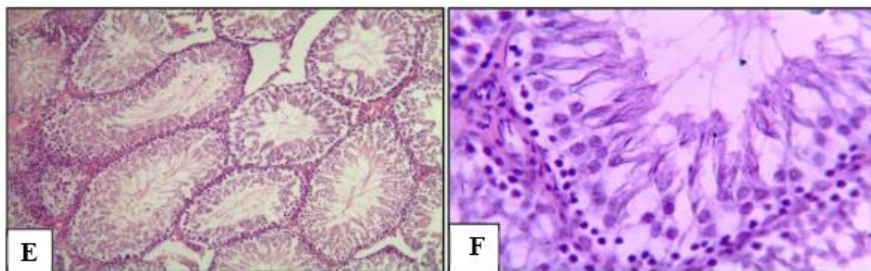


Figure (5-E&F): Section through the testis of the Cumin plant extract (200 mg/kg) with H<sub>2</sub>O<sub>2</sub> group rats showing nearly normal seminiferous tubules, good number of sperms and healthy germinal cells undergoing cellular division, 100x and 400x respectively, H&E.

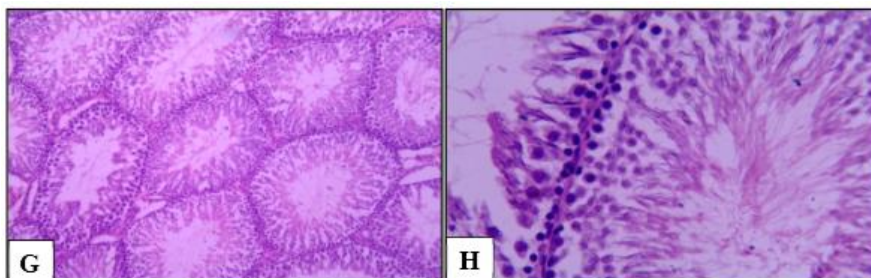


Figure (5-G&H): Section through the testis of the Cumin plant extract (200 mg/kg) group rats showing nearly to control group structure of the seminiferous tubules, 100x and 400x respectively, H&E.

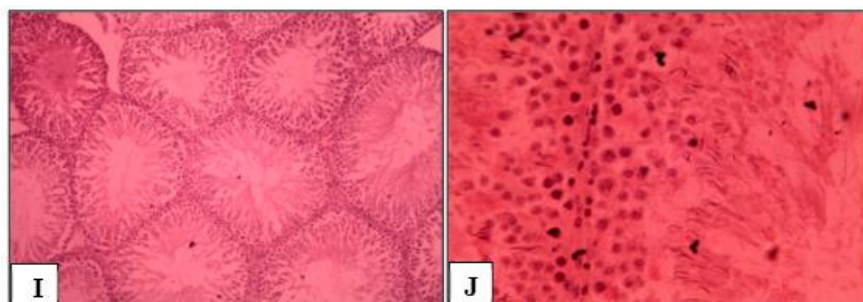


Figure (5-I&J): Section through the testis of the vitamin E and H<sub>2</sub>O<sub>2</sub> group rats observed repair of the cells lining in the seminiferous tubules with the continuation of the formation of sperm 100x and 400x respectively, H&E.

## References

1. Sultana, S.; Ripa, F. A.; Hamid, K. (2010). Comparative antioxidant activity study of some commonly used spices in Bangladesh. *Pak. J. Biol. Sci.*, 13(7), 340.
2. El-Ghorab, A. H.; Nauman, M.; Anjum, F. M.; Hussain, S.; Nadeem, M. (2010). A comparative study on chemical composition and antioxidant activity of ginger (*Zingiber officinale*) and cumin (*Cuminum cyminum*). *J. agricul. food chem.*, 58(14), 8231-8237.
3. Abbaszadegan, A.; Gholami, A.; Ghahramani, Y.; Ghareghan, R.; Ghareghan, M.; Kazemi, A.; Ghasemi, Y. (2016). Antimicrobial and cytotoxic activity of *Cuminum cyminum* as an intracanal medicament compared to chlorhexidine gel. *Ira.endod. J.*, 11(1), 44.
4. Oroojalian, F.; Kasra-Kermanshahi, R.; Azizi, M.; Bassami, M. R. (2010). Phytochemical composition of the essential oils from three Apiaceae species and their antibacterial effects on food-borne pathogens. *Food chem.*, 120(3), 765-770.
5. Nasreen, S. and Radha, R. (2011). Assessment of Quality of *Withaniasomnifera* Dunal (Solanaceae) Pharmacognostical and physicochemical profile. *Int. J. Phar. Pharm. Sci.*, 3(2), 152-155.
6. Deepak. (2013). Importance of *Cuminum cyminum* L. and *Carum carvi* L. in traditional medicaments-a review. *Indian J. Trad. Knowl.*, 12(2), 300-307
7. Dhandapani, S.; Subramanian, V. R.; Rajagopal, S.; Namasivayam, N. (2002). Hypolipidemic effect of *Cuminum cyminum* L. on alloxan-induced diabetic rats. *Pharmacol. Res.*, 46(3), 251-255.
8. Anesini, C. and Perez, C. (1993). Screening of plant used in argentine folk medicine for antimicrobial activity. *J. Ethnopharmacol.*, 39(2): 119-128.
9. Sedlak, J.; and Lindsay, R. H. (1968). Analytical biochemistry. pp: 192. Cited by Al-Zamely (2001).
10. Beng, J. A.; and Aust, S. D. (1978). Estimation of serum malondialdehyde level. *Methods in enzymology* Hoffee Jones ed. By Hoffee PA and Jone ME. Academic Press, a Subsidiary of Harcourt Brace Jovanovich Publisher, New York.
11. Lenton, E.; Meal, L.; Sulaiman, R. (1982). Plasma concentrations of Human Gonadotropin from the Time of Implantation until the second week of pregnancy. *Fert. Ster.* 37. 773-78.
12. Vitt, U. A.; Kloosterboer, H. J.; Rose, U. M.; Mulders, J. W.; Kiesel, P. S.; Beta, S.; Nayudu, P. L. (1998). Isoforms of human recombinant follicle stimulating hormone S: comparison of effects on murine follicle development in vitro. *Biol. Rep.*, 59 (4), 854-861.
13. Bristow, A. F. (1998). Standardization of protein hormone immunoassays: current controversies. proceeding of the UKNEQAS Endocrinology meeting ACB, 3: 66-73
14. Yucra, S.; Gasco, M.; Rubio, J.; Nieto, J.; Gonzales, G. F. (2008). Effect of different fractions from hydroalcoholic extract of Black Maca (*Lepidium meyenii*) on testicular function in adult male rats. *Fert. Ster.*, 89(50), 1461-1467.
15. Bancroft, J. D. and Gamble, M. (2008). *Theory and practice of histological techniques*. Elsevier Health Sciences. 16(2):16-10.
16. Steel, R.G.D. and Torries, J.H. (1980). *Principle and Procedures of Statistics: A Biochemical Approach*. 2nd edition, McGraw-Hill Book Company Inc., New York, USA.
17. Tayawi, Hussein Mohammed (2015). A comparative study of the effect of carnitine, ginseng, shark and arginine in some physiological and biochemical aspects of male reproductive system in healthy white rats exposed to stress, PhD thesis, Faculty of Science, University of Tikrit.
18. Tayawi, Hussein Mohammed and Abdul Rahman, the owner of Juma. (2017). A comparative study of the effect of carnitine, ginseng, shark, and arginine in the levels of MDH and SOD in the healthy white rats exposed to stress. (*Tikr. J. Pur. Sci.* 22 (4).
19. Krishnamoorthy, P.; Vaithinathan, S.; Rani, V. A.; & Bhuvanewari, A. (2007). Effect of Terminalia chebula fruit extract on lipid peroxidation and antioxidative system of testis of albino rats. *African Journal of Biotechnology*, 6(16): 1888-1891.
20. Hassani, Awis Muwafaq Hamed (2004). Effect of a number of cancer tumors in lipid peroxidation, caldathathione level and a number of variables in blood components. Master Thesis, Faculty of Science, University of Mosul.
21. Nadeem, M.; Riaz, A. (2012). Cumin (*Cuminum cyminum*) as a potential source of antioxidants. *Pak J Food Sci*, 22, 101-107.
22. Copeland, K. R.; Scales, D. B.; Hill, G. M.; Link, J. E.; Turner, K. C.; Rozeboom, C. J.; Stuart, R. L. (2017). 397 Effects of vitamins E and D on performance and antioxidant enzymes in nursery pigs. *Journal of Animal Science*, 95(supplement2), 192-192.
23. Kampa, M.; Nistakaki, A.; Tsaousis V.; Votas, G.; Nistakaki, A.; Hatzoglou, A. Blekas, G. (2003). Antiproliferative and apoptotic effect of selective phenolic acids on T 47 D human breast cancer cells. Potential of mechanism of action. *Bre. Canc. Res.* 6 (2): 63 – 74.
24. Fonseca, V. A.; Stone, A.; Munshi, M.; Baliga, B. S.; Aljada, A.; Thusu, K.; Dandona, P. (1997). Oxidative stress in diabetic macrovascular disease: does homocysteine play a role?. *Southern medical journal*, 90(9), 903-906.
25. Diplock, A. T.; Charleux, J. L.; Grozier, Will, G.; Kok, F. T.; Evans, R.; Roberforid, M.; Stable, W.; Vina-Ribes, J. (1998). "Functional food science



and defense against reactive oxidative species". British J. Nutr. 80 (suppl. 1): 570.

**26. Jankeer, M. Hussen (2015)**. The protective effect of Vitamin C and Vitamin E on some antioxidants and lipid peroxidation in blood and tissues of male albino rats treated with aluminum. Int. J. Enh. Res. Sci. Techn. Engin. 4 (2), 34-44.

**27. Rahim, S. M.; Taha, E. M.; Mubark, Z. M.; Aziz, S. S.; Simon, K. D.; Mazlan, A. G. (2013)**. Protective effect of *Cymbopogon citratus* on hydrogen peroxide-induced oxidative stress in the reproductive system of male rats. Systems biology in reproductive medicine, 59(6), 329-336.

**28. Allen, R. G. and Tresini, M. (2000)**. Oxidative stress and gene regulation. Fre. Rad. Biol. Medic. 28(3), 463-499.

**29. Sakhaee, E.; Emadi, L.; Azari, O.; Kheirandish, R.; Esmaili Nejad, M. R.; ShafieiBafti, H. (2016)**. Effects of *Cuminum cyminum L.* essential oil on some epididymal sperm parameters and histopathology of testes following experimentally induced copper poisoning in mice. Andrologia, 48(5), 542-547.

**30. Saxena, P.; Gupta, R.; Gupta, R. S. (2015)**. Contraceptive studies of isolated fractions of *Cuminum cyminum* in male albino rats. Natural product research, 29(24), 2328-2331.

**31. Ishihara, M.; Itoh, M.; Miyamoto, K.; Suna, S.; Takeuchi, Y.; Takenaka, I.; Jitsunari, F. (2000)**.

Spermatogenic disturbance induced by di-(2-ethylhexyl) phthalate is significantly prevented by treatment with antioxidant vitamins in the rat. Int. J. of andro. 23(2), 85-94.

**32. Hipler, U. C.; Gornig, M.; Hipler, B.; Romer, W.; Scheiber, G. (2000)**. Stimulation and scavestrogen - induced inhibition of reactive oxygen species generated by rat sertoli cells. Arch. Andro. 44(2), 147-154.

**33. Gupta, R. S.; Saxena, P.; Gupta, R.; Kachhawa, J. B. (2011)**. Evaluation of reversible contraceptive activities of *Cuminumcyminum* in male albino rats. Contraception, 84(1), 98-107.

**34. Khare, C. P. (2008)**. Indian medicinal plants: an illustrated dictionary. Springer Science & Business Media.

**35. Jalili, T.; Khaki, A.; Ghanbari, Z.; Imani, A. M.; Hatefi, F. (2014)**. A Study of the Therapeutic Effects of Vitamin E on Testicular Tissue Damage Caused by Fluoxetine. Crescent J. Med. Biolo. Sci. 1(2), 37-41.

**36. Al-Zubair, Suha Abdel-Karim Rashid (2003)**. Effect of sodium thenxate on testicular function in rats exposed to oxidative oxidation induced by hydrogen peroxide. Master Thesis, Faculty of Veterinary Medicine, University of Mosul.

**37. Johri, R. K. (2011)**. *Cuminum cyminum* and *Carum carvi*: An update. Pharmacog. Rev. 5(9), 63.

## دراسة فسلجيه ونسجيه لتأثير المستخلص المائي لنبات الكمون *Cuminum cyminum* وفيتامين E على الجهاز التكاثري الذكري في الجرذان البيض المعرضة للإجهاد التأكسدي

عثمان عيد صالح الفهداوي<sup>1</sup> ، منيف صعب احمد ساجت الجنابي<sup>1</sup> ، تريفة فاروق اسماعيل<sup>2</sup>

<sup>1</sup>قسم علوم الحياة ، كلية التربية للعلوم الصرفة ، جامعة تكريت ، تكريت ، العراق

<sup>2</sup>قسم علوم الحياة ، كلية التربية ، جامعة صلاح الدين ، اربيل ، العراق

### الملخص

أجريت هذه الدراسة لمعرفة تأثير المستخلص المائي لنبات الكمون بجرعة (200 ملغم/كغم من وزن الحيوان) على بعض المتغيرات الفسلجية والنسجية للجهاز التناسلي الذكري في الجرذان البيض المعرضة للكرب التأكسدي المستحدث بيروكسيد الهيدروجين ( $H_2O_2$ ). استخدمت (30) حيوانا من ذكور الجرذان البيض اوزانها تتراوح بين (200- 250 غم) واعمارها بين 10-12 اسبوع وقسمت الحيوانات إلى (5) مجاميع، كل مجموعة شملت (6) حيوانات وكانت المجموعة الأولى هي مجموعة السيطرة حيث أعطيت العلف مع ماء الشرب الاعتيادي، المجموعة الثانية شملت مجموعة السيطرة المصابة وقد عوملت هذه المجموعة بـ  $H_2O_2$  (0.5%) مع ماء الشرب، المجموعة الثالثة مجموعة المستخلص المائي لنبات الكمون (200 ملغم/كغم من وزن الحيوان) عن طريق التغذية الانبوبية مع  $H_2O_2$  (0.5%)، المجموعة الرابعة هي مجموعة المستخلص المائي لنبات الكمون (200 ملغم/كغم من وزن الحيوان) لوحده والمجموعة الخامسة جرعت فيتامين E بجرعة 500 ملغم/كغم وزن الحيوان مع  $H_2O_2$  (0.5%) واستمرت التجربة لمدة (30) يوما لكل المجاميع. نتائج البحث الحالي اظهرت ان  $H_2O_2$  أدى إلى أحداث ارتفاع معنوي ( $P \leq 0.05$ ) في المألوندايديهايد، انخفاض معنوي ( $P \leq 0.05$ ) في الكلوتاثيون وإلى أحداث انخفاض معنوي ( $P \leq 0.05$ ) في الهرمون الذكري (Testosterone) في مصل الدم مقارنة مع مجموعة السيطرة، بينما أدى معاملة الجرذان بـ  $H_2O_2$  مع المستخلص المائي لنبات الكمون (بجرعة 200 ملغم/كغم من وزن الجسم) إلى انخفاض معنوي في المألوندايديهايد، ارتفاع معنوي في الكلوتاثيون وارتفاع معنوي في مستوى هرمون (Testosterone) في مصل الدم مقارنة مع المجموعة المعاملة بـ  $H_2O_2$ . اما بالنسبة لانسجة الخصى فقد أدى  $H_2O_2$  الى حصول تغيرات نسجية مرضية واضحة في النيببات المنوية، من جهة اخرى معاملة الحيوانات المعرضة للإجهاد بـ  $H_2O_2$  بالمستخلص المائي للكمون (200 ملغم/كغم) أدى الى تحسن قليل في النيببات المنوية وعودة نشاطها. ان المستخلص المائي لنبات الكمون يعمل كمضاد للاكسدة من خلال دوره المهم في كبح التأثيرات الضارة لبعض انواع الجذور الحرة داخل الجسم وبالتالي إصلاح الضرر الحاصل في معظم التغيرات الفسلجية والنسجية ووظائف الجهاز التناسلي الذكري للجرذان ازاء تعرضها للكرب التأكسدي المستحدث بـ  $H_2O_2$ . ولكن تبين من خلال النتائج أن اعطاء مستخلص نبات الكمون لفترات طويلة يعمل على خفض مستوى هرمون Testosterone وبالتالي قد يكون له تأثيرات سلبية على الخصوبة.