



Diagnosis of parasitic infections in vermiform appendix in patients with appendicitis in Kirkuk city, Iraq

Khulood Abdulmuttaleb Al-Saeedi , Fatima Shihab Al-Nasiri

Department of Biology, College of Science, Tikrit University , Tikrit , Iraq

<https://doi.org/10.25130/tjps.v24i7.452>

ARTICLE INFO.

Article history:

-Received: 18 / 8 / 2019

-Accepted: 29 / 9 / 2019

-Available online: / / 2019

Keywords: Appendicitis, parasites, protozoa, helminths.

Corresponding Author:

Name: Fatima Shihab Al-Nasiri

E-mail: fshnasiri@yahoo.com

Tel:

ABSTRACT

The present study is conducted in Kirkuk city, Iraq; between July to December 2018. Within this period 197 resected appendix are examined to investigate the parasitic infections that may associated with appendicitis. Direct with concentrated methods are used in luminal content examinations. Also, histological examination of haematoxylin and eosin stained tissue sections is performed to diagnose the parasitic infections in the lumen and within the appendix tissue. The parasitic infection reported in 12.69% cases included four species, as well as a mixed infection. *Entamoeba histolytica* (trophozoite and cyst), *Giardia lamblia* (trophozoite and cyst), *Cryptosporidium sp.*(oocyst) and *Enterobious vermicularis* (adult worm and ova) are recorded. The most common determined parasite is *E. histolytica* (8.63%). The parasitic infection within the resected appendix reported in females (8.12%) more than males (4.57%). The parasitic infections in the study are prevalent in patients within the age groups 13 to 18 years and 19 to 24 years (3.55% for each one).

Introduction

The intestinal parasitic infections represent a serious and major problem of medical health, especially in undeveloped countries [1]. Among the ten most prevalent intestinal infections in the world are amobiasis, ascariasis, trichuriasis and hookworm infection [2].

The vermiform appendix is a worm-shaped structure originating from the posteromedial caecal wall, less than or equal to 2 cm beneath the ileum end. It's located within the abdominal right lower quadrant [3]. Histologically the structure of the appendix is the same as that of the large intestine, but there are some important histological variations present within the appendix; the most evident one is the presence of the lymphoid aggregates within the mucosa and submucosa in abundant numbers [4].

Appendicitis is the inflammation of the appendix it possibly acute or chronic. Appendectomy considered as one of the most common surgical contingencies of the abdomen [5]. Although appendicitis is very common, it's etiopathogenesis is poorly understood, luminal obstruction by a faecolith, worms (especially pin worm), reactive lymphoid hyperplasia, foreign body, calculi, or tumour is often considered to be the causes. However, obstruction isn't present in many cases and appendicitis considered to be due to

generalized infection haematogenous spread, vascular occlusion, or inappropriate diet [6,7]. Intestinal parasites occasionally influence the vermiform appendix, this state may differ between an inoffensive reaction and an inflammatory reaction that may threaten the life [8]. The most prevalent parasites in appendectomy specimens are the pin worm *E. vermicularis*, as well as other parasitic infections that may influence the vermiform appendix includes amebiasis, cryptosporidiosis, schistosomiasis and ascariasis, also *Strongyloides stercoralis* [4].

There are few studies in Iraq reported the parasitic infection of the vermiform appendix by luminal content and histological examinations. A study carried out in Najaf City determined *E. histolytica*, *G. lamblia*, *Ascaris lumbricoids*, *E. vermicularis*, *Trichuris trichura* and *Hymenolepis nana* [9]. Appendicitis parasitological and histological study is performed in Al-Diwaniya city recorded six parasite species, *E. histolytica*, *G. lamblia*, *A. lumbricoids*, *E. vermicularis*, *T. trichura* and *H. nana* [10]. In Thi Qar city, a study of the parasitic and bacterial infections associated with appendicitis is carried out and reported four parasitic species; *E. histolytica*, *G. lamblia*, *A. lumbricoids* and *E. vermicularis* [11]. Another study in Samara district, also recorded four

species *E.histolytica*, *Entamoeba coli*, *E. vermicularis* and *Taenia saginata* [12]. In Kirkuk city the parasitic infections associated with appendicitis aren't studied; according to the mentioned above the objective of the present study is the diagnosis of the parasitic infections in resected appendices in patients with appendicitis in Kirkuk city, in addition to determining its relationship with age, gender and stage of reported parasites species.

Materials and methods

The study is conducted through a period from July till December 2018. A total of 197 patients with appendicitis underwent appendectomy in Azadi teaching hospital and Kirkuk general hospital, in Kirkuk city. The patient's case sheet is performed to record information about each patient: case number, name, age, gender, appendectomy date, collection site, resected appendix content, reported parasite species and diagnosed stage. All specimens are labelled with the patient name, number and appendectomy date. After the surgical removal, first each appendix examined by the naked eye, cut up into three parts (top, middle and distal), the appendix content of the top and middle parts are washed with

normal saline in order to diagnose the parasitic infection in the luminal content of the resected appendix by both the direct examination method and concentration methods [13,14]. The macroscopically diagnosed helminths are relaxed and examined microscopically [15]. The distal part, as well as the top and middle parts are preserved in a clean container with 10% formal saline for histological examination. The fixed distal part of appendectomy specimens are sectioned, cross section cuts up from the top and the remain distal part cut up into two longitudinal sections[16]. Tissue processing protocols in the present study are performed as illustrated by Slaoui and Fiette [17].

Results

In both parasitological and histological examinations, the parasitic infections detected in 25 patients ages between 7 to 55 years. The peak prevalence of parasitic infections is 3.55% in both age groups 13-18 and 19-24 years, whom most frequently operated. The age groups distribution of patients with appendicitis and parasitic infections illustrated in table (1).

Table 1: Distribution of 197 patients with appendicitis in relation to age groups and parasitic infections.

Age groups (Year)	No. of patients With ppndicitis	No. of patients with appendicitis and parasitic infections	Prevalence of infection (%)
7-12	10	2	1.02
13-18	57	7	3.55
19-24	45	7	3.55
25-30	44	6	3.04
31-36	25	1	0.51
37-42	9	1	0.51
43-55	7	1	0.51
Total	197	25	12.69

The prevalence of parasitic infections is higher in females (8.12%) than in males (4.57%) as in table (2).

Table 2: Distribution of 197 patients with appendicitis in relation to the gender and parasitic infections.

Gender	No. of patients with appendicitis	No. of patients with appendicitis and parasitic infections	Prevalence of infection (%)
Male	86	9	4.57
Female	111	16	8.12
Total	197	25	12.69

The present study determined different intestinal parasite species, as well as mixed infection; among the diagnosed species *E. histolytica* infection determined mostly in 8.63% cases. The luminal content examination of resected appendices reported *E. histolytica* trophozoite and cyst (figure 1 A and B), *G. lamblia* trophozoite and cyst (figure 2 A and B),

Cryptosporidium sp. only oocyst stage (figure 3) and *E. vermicularis* adult worm and ova, while larva stage isn't reported (figure 4 A and B). As well as, mixed infection included (*G. lamblia* cyst, *Cryptosporidium sp.* oocyst and *E. vermicularis* ova). The reported parasites stages in relation to patients ages and gender illustrated in table (3).

Table 3: Prevalence of infection with parasites which detected in luminal contents of vermiform appendix in relation to parasite stage, age and gender of patients with appendicitis

Groups	Infection with <i>E. histolytica</i>			Infection with <i>G. lamblia</i>		Infection with <i>Cryptosporidium sp.</i>	Infection with <i>E. vermicularis</i>		Mixed infection (<i>G. lamblia</i> , <i>Cryptosporidium sp.</i> and <i>E. vermicularis</i>)
	Trophozoite No. (%)	Cyst No. (%)	Trophozoite and cyst No. (%)	Cyst No. (%)	Trophozoite and cyst No. (%)	Oocyst No. (%)	Adult No. (%)	Adult and ova No. (%)	Cyst, oocyst and ova No. (%)
7-12	0	0	0	0	0	0	1 (0.51)	1 (0.51)	0
13-18	2 (1.02)	1 (0.51)	3 (1.52)	0	0	1 (0.51)	0	0	0
19-24	0	3 (1.52)	1 (0.51)	1 (0.51)	1 (0.51)	0	0	0	1 (0.51)
25-30	2 (1.02)	1 (0.51)	2 (1.02)	1 (0.51)	0	0	0	0	0
31-36	0	0	1 (0.51)	0	0	0	0	0	0
37-42	1 (0.51)	0	0	0	0	0	0	0	0
43-55	0	0	0	1 (0.51)	0	0	0	0	0
Age (total)	5 (2.54)	5 (2.54)	7 (3.55)	3 (1.52)	1 (0.51)	1 (0.51)	1 (0.51)	1 (0.51)	1 (0.51)
Male	1 (0.51)	1 (0.51)	3 (1.52)	1 (0.51)	1 (0.51)	1 (0.51)	1 (0.51)	0	0
Female	4 (2.03)	4 (2.03)	4 (2.03)	2 (1.02)	0	0	0	1 (0.51)	1 (0.51)
Gender (total)	5 (2.54)	5 (2.54)	7 (3.55)	3 (1.52)	1 (0.51)	1 (0.51)	1 (0.51)	1 (0.51)	1 (0.51)

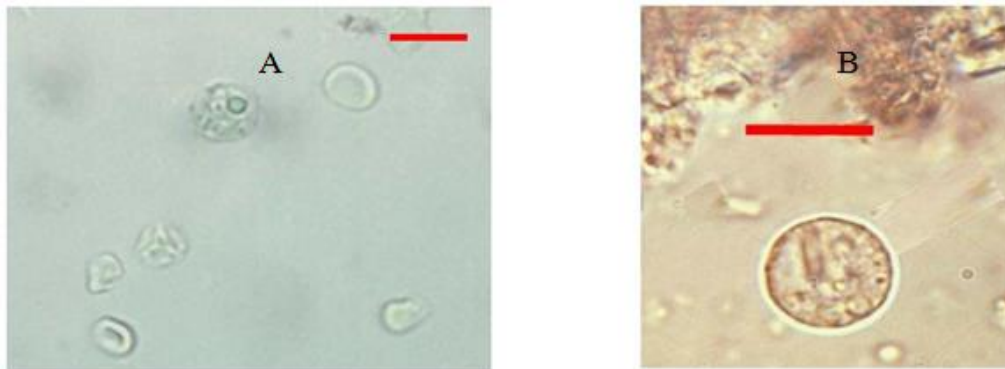


Fig. 1: *E. histolytica* detected by luminal content examination of the vermiform appendix. A: trophozoite (Bar=50µm), B: cyst (Bar=10µm).

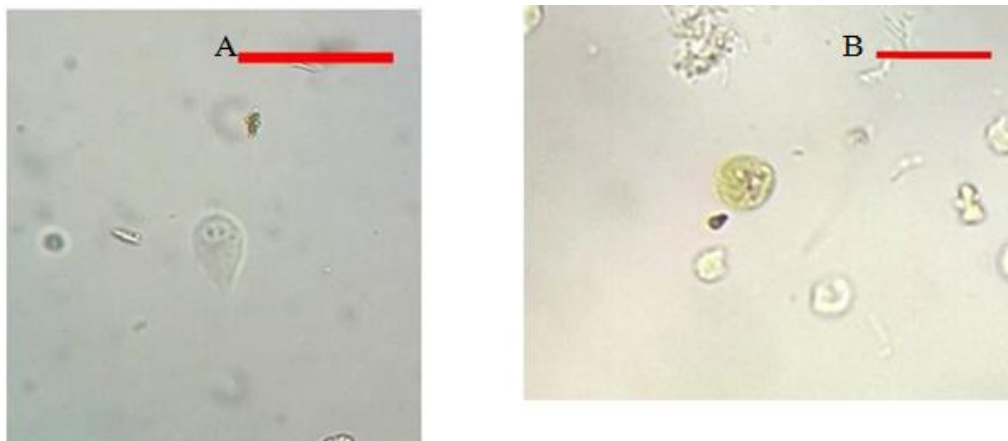


Fig. 2: *G. lamblia* detected by luminal content examination of the vermiform appendix. A: trophozoite (Bar=25µm), B: cyst (Bar=15µm).

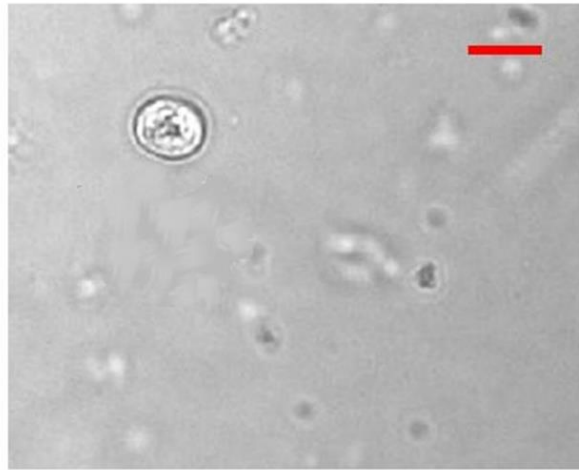


Fig. 3: *Cryptosporidium sp.* oocyst detected by luminal content examination of the vermiform appendix. (Bar=5 μm).

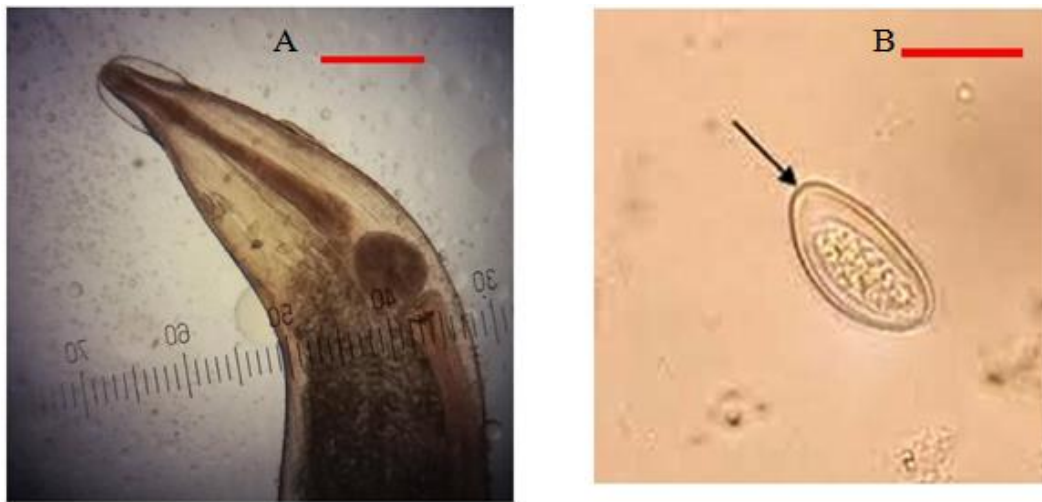


Fig. 4: *E. vermicularis* detected by luminal content examination of the vermiform appendix. A: adult female (Bar=200μm), B: ova (Bar=10μm).

E. vermicularis adult worms and ova are reported by the histological examination of transverse and longitudinal tissue sections (figure 5 A and B); *E. histolytica*, *G. lamblia*, *Cryptosporidium sp.* aren't

reported by histological examination of haematoxylin and eosin stained tissue sections. *E. vermicularis* reported stages in relation to patients age and gender are described in the table (4).

Table 4: *E. vermicularis* prevalence reported by histological examination of haematoxylin and eosin stained tissue sections in relation to determined stages, patients age and gender.

Groups	<i>E. vermicularis</i> adult worm and ova No. (%)
7-12	1 (0.51)
13-18	0
19-24	0
25-30	0
31-36	0
37-42	0
43-55	0
Age (total)	1 (0.51)
Male	0
Female	1 (0.51)
Gender (total)	1 (0.51)

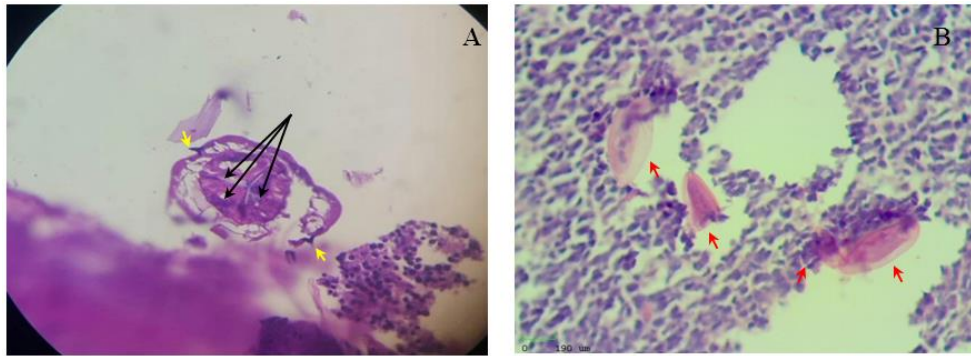


Fig. 5: Showing diagnosed *E. vermicularis* by histological examination of tissue sections of the vermiform appendix. A: the anterior region of adult worm, the lateral alae (→) with triradiate pharynx (→), B: more than one *E. vermicularis* ova (→) that deposited in the mucosal layer within the lamina propria. (Hematoxylin-eosin; 40x).

Discussion

The study determined four parasite species in the resected appendices from patients with appendicitis in Kirkuk city. The diagnosed species are *E. histolytica*, *G. lamblia*, *Cryptosporidium sp.* and *E. vermicularis*, as well as mixed infection. The prevalence of parasitic infections of the gastrointestinal tract is worldwide; nearly four billion people in the world suffer from parasitic infections that especially influence communities which have lower education, living conditions, socioeconomic state, sanitation and hygiene [18].

The causes of appendicitis undetermined and remain debated. The vermiform appendix is a blind ended tube that may harbor some pathogens. Different materials may infiltrate this blind ended tube including fecalith, parasites and microbes. These transient materials that found their way to the appendix can stay within the organ for a while without initiating any disease. Sometimes, a number of these pathogens can initiate an inflammatory reaction that causes the inflammation of the appendix. If the inflammatory process is serious and continued acute appendicitis will result [19,20].

Although 0.2-41.8% of resected appendix revealed the parasitic infection, only little evidence was regarding the association of appendicitis with parasitic infections [21]. Within the resected appendix, the parasitic infections are generally an incidental finding and so on numerous parasites are found in the appendix lumen including protozoan parasites as *E. histolytica*, *G. lamblia*, *B. coli*, *Cryptosporidium spp.* and helminths as *E. vermicularis* [22,23].

Appendicitis is very common in the second and third decades of life (adolescents and young adults). But acute appendicitis may occur at any life time from infancy to the very old age [7]. In the present study the highest prevalence of parasitic infections in the vermiform appendix (3.55%) determined in the age groups 13 to 18 years and 19 to 24 years (3.55%) followed by 25 to 30 years (3.04%). The vermiform appendix in the second and third decades of life has abundant patches of lymphoid tissue within the mucosal and submucosal layers. This lymphoid tissue

not existent at birth, it gradually grows and best seen in about 10 years old. Subsequently, in the fourth and fifth decades the lymphoid tissue tend to progressively reduce in quantity. Within the sixth, seventh and eighth decades, only diffuse lymphatic infiltration is exists in the lamina propria. In appendicitis these lymphatic tissues become active and enlarged [24,25-26]. Petroianu and Barroso [27] suggested that, the prevalence of appendicitis in young adults and teenagers supposes the pathophysiological role for lymphoid tissue that exists in abundance in the appendix at this decade of life. However, the appendicitis incidence in the second decades of life was the greatest, while the lymphoid tissue in the first decade of life is at its maximum. The lymphatic system's ability for a rapid response to a different stimuli, especially infection, possibly explain that, the parasites may evoke a lymphoid response of the appendix lymphatic tissue, which present in abundance at the second and third decades of life that results in an inflammatory reaction [28].

Intestinal parasitic infections are not associated with a particular gender. While, appendicitis incidence varies with the season, geographic region, country, race and gender, but the reasons responsible for these variations are unknown [29,30]. The results of the present study reported that the prevalence of parasitic infection of the vermiform appendix is higher in females (8.12%) than males (4.57%).

Among the diagnosed parasite species in the study *E. histolytica* infection of the appendix is the highest (8.63%). Although the authors supposed *E. vermicularis* as the most frequently diagnosed parasites within the resected appendix with a globally recorded prevalence (0.6%-13%) [31,32-33], while others referred to amoebic appendicitis globally recorded prevalence (0.5-2.3 %) [34,35]. This can be interpreted, that *E. histolytica* habitat ileocecal region or sigmoidrectal regions; close to the vermiform appendix, so the appendix infection is usually developed exclusively or almost exclusively as an extension of the infection from the caecum and right colon [36].

In the current study, by luminal content examinations *E. histolytica* trophozoite and cyst diagnosed equally in all cases (2.54%), also trophozoite with cyst stages determined in 3.55% cases; whereas, in histological examination, the amoebic infection isn't detected. Otan *et al.* [37] considered that the direct wet luminal content examination of appendectomy specimens is the effective and rapid method in diagnosis of amoebic appendicitis. Likewise, Lamps mention that, particularly by histological examination of gastric biopsy, it's difficult or impossible to detect the amoebic infection in patients with mild symptoms or asymptomatic [32]. Diagnosis of two parasite stages in the current study may be explained by the details of the life cycle within the human small intestine, excystation triggered by trypsin; trophozoite carried by the peristalsis to the large intestine where it resides in the lumen or the wall of the large intestine. The ileocecal region or sigmoidrectal region are the most common sites or may involve the appendix causes amoebic appendicitis or generalize to involve the whole large intestine length [38,39]. Sastry and Bhat [39] referred to some factors within the large intestine that may enhance encystation; food deprivation, accumulation of waste products and overcrowding. Among amebas *E. histolytica* considered unique which have the ability to hydrolyze and invade host tissue. Attachment to the host cell, contact cytolysis of host cells or release cytotoxic substances evoke the host inflammatory response by stimulation of cytokine production [40]. In the world mortality as a consequence of amoebic appendicitis is higher (7-10%) than nonamoebic appendicitis. As a result of several reasons, including, there are no specific examinations or symptoms to distinguish nonamoebic and amoebic appendicitis, therefore it is almost impossible to diagnose amoebic appendicitis preoperative. Another reason is the difficulty in trophozoites detection with hematoxylin and eosin stained tissue sections of resected appendix, also conduct periodic acid Schiff (PAS) stain is useful in diagnosis of amoebic appendicitis [41]. Appendicitis associated with *G. lamblia* infection in the current study determined by luminal content examination. The infection not determined by histological investigations. Lamps mention that many trophozoites in the endoscopic biopsy specimen of the gastrointestinal tract within the lumen may be washed away during processing [32]. The frequently reported cyst stage within the resected appendix can be suggested to the trophozoite habitat and encystation process triggers. Unlike *E. histolytica*; *G. lamblia* trophozoite resides the small intestine (duodenum, jejunum, and upper ileum), encystation began gradually when trophozoite pass down to the large intestine in response to alkaline pH, cholesterol starvation and exposure to bile salts where these conditions are considered to be adverse to the trophozoite stage [39,40].

The infection with *G. lamblia* determined in the current study is equal in both genders, males and females. The reported infections are more prevalent within the age group 19 to 24 years. Consideration must be given to the limited number of *G. lamblia* infection associated with appendicitis in our study and all previous studies, so it is difficult to restrict the infection in a certain age group or certain gender. However, John and Petri mention that, *G. lamblia* infects all ages, but children more frequently suffer from giardiasis than adults [42].

The current study reported *Cryptosporidium sp.* oocyst within appendiceal luminal content, whereas by histological investigations the infection isn't reported. The mostly reported oocyst stage in the resected appendix may be explained by *Cryptosporidium spp.* difference from other coccidian parasites; it resides in an intracellular extra cytoplasmic location and do not go deep within the host cell. Just below the cell membrane of the intestinal epithelial cells, both the sexual and asexual reproduction takes place in a parasitophorous vacuole within intestinal epithelial cells [43]. Shikani and Weiss mention that, when the infection is asymptomatic *Cryptosporidium spp.* infection often confined to the colon, but in severe cases, *Cryptosporidium spp.* colonize the gastrointestinal tract, such as stomach, small intestine, rectum and can extend to the appendix causes appendicitis [44].

The present study reported one case which is male and within the age group 13-18 years. Al-Shamiri *et al.* and Rahi *et al.* mention that, cryptosporidiosis predicted to be raised in developing countries, particularly in children and both sexes have a similar chance of being infected [45,46].

The current study reported *E. vermicularis* adult worm and ova in surgically removed appendices by luminal content examinations and by histological examination adult worms diagnosed in the appendix lumen and ova within the mucosal layer. The present study determined *E. vermicularis* infection associated with appendicitis equal in males and females, within the age group 7 to 12 years. Some studies referred to the prevalence of *E. vermicularis* infection in children ages 5 to 14 years and the infection relatively uncommon in adults and infants under two years ages. Also, frequently infect females more than males [47,48].

Globally, *E. vermicularis* infection within the resected appendices in patients with symptoms of appendicitis ranging from 0.2% to 41.8% [23]. This percentage more likely suggested that the presence of *E. vermicularis* within the appendix lumen may result in symptoms "appendiceal syndrome" resembles acute appendicitis. This "syndrome" also called appendiceal colic; characterized by pelvic pain with chronic right lower quadrant pain. The hypothesis demonstrated that appendiceal colic occurred due to obstruction of the appendiceal lumen by *E. vermicularis* adult worms or ova [49].

References

- [1] Kucik, C. J.; Martin, G. L. and Sortor, B. V. (2004). Common intestinal parasites. *American Family Physician*, 69 (5): 1161-1168.
- [2] Mengistu, A., Gebre-Selassie, S. and Kassa, T. (2007). Prevalence of intestinal parasitic infections among urban dwellers in southwest Ethiopia. *Ethiopian Journal of Health Development*, 21: 12-17.
- [3] Gupta, G.; Srivastava, S. K.; Mathur, S. K. and Gupta, V. (2012). Histomorphometric characteristics of human vermiform appendix with special reference to lymphoid tissue. *Journal of Morphological Sciences*, 29 (3): 135-139.
- [4] Carr, N. J. and Sobin, L. H. (2009). Appendix. In: Weidner, N.; Cote, R. J.; Suster, S. and Weiss, L. M. (Eds.), *Modern surgical pathology*. 2nd Edn.. Saunders Elsevier, China: 837-854.
- [5] Kadim, A. A.-M. (2016). Surgical and clinical review of acute appendicitis. *International Journal of Multidisciplinary and Current Research*, 4: 280-287.
- [6] Mohan, H. (2010). *Textbook of pathology*. 6th Edn. Jaypee Brothers Medical Publishers, Ajanta: 933 pp.
- [7] White, S. J.; Levison, D. A. and Carey, F. A. (2014). The gastrointestinal system. In: Herrington, C. S. (Ed.), *Muir's textbook of pathology*. 15th Edn., Taylor and Francis group, New York: 231-271.
- [8] Anwar, I.; Hassan, S. and Khalid, A. (2016). Parasitic infestation of the appendix, masquerading as acute appendicitis. *International Journal of Pathology*, 14 (2): 74-78.
- [9] Al-Shadood, H. A. S.; Sultan, B. A. and Alsaiegh, A. M. (2009). Parasitic cause of acute appendicitis in Najaf. *Kufa Medical Journal*, 12 (2): 62-69. (In Arabic)
- [10] Al-Awa'ady, J. H. H.; Al-Wa'aly, A. B. M.; Shubber, H. W. K. and Al-Mayahi, F. S. A. (2010). A parasitological and histological study of the appendicitis in Al-Diwaniya city. *Al-Qadisiyah Journal of Pure Sciences*, 15 (4): 103-112. (In Arabic)
- [11] Al-Rikabi, N. J. A. (2010). The parasitic and bacterial infections associated with appendicitis in Thi Qar province. *Journal of Thi-Qar Science*, 2 (1): 14-20. (In Arabic)
- [12] Al-Sammarai, A. S. M. (2015). Diagnosis study of the parasites that cause appendicitis and histological changes accompanying her in Samarra city. *Al-Anbar Journal of Veterinary Sciences*, 8 (2): 46-53. (In Arabic)
- [13] World Health Organization (WHO). (1991). *Basic laboratory methods in medical Parasitology*. World Health Organization, Geneva: 114 pp.
- [14] Cuomo, M. J.; Noel, L. B. and White, D. B. (2009). Diagnosing medical parasites: a public health officers guide to assisting laboratory and medical officers. *Air education and training command Randolph AFB TX*: 286 pp.
- [15] Sepulveda, M. S. and Kinsella, J. M. (2013). Helminth collection and identification from wildlife. *Journal of Visualized Experiments*, (82): e51000.
- [16] Allen, D. C. and Cameron, R. I. (2004). Gastrointestinal specimens. In: Allen, D. C. and Cameron, R. I. (Eds.), *Histopathology specimens: clinical, pathological and laboratory aspects*. Springer - Verlag, London: 3-124.
- [17] Slaoui, M. and Fiette, L. (2011). Histopathology procedures: from tissue sampling to histopathological evaluation. In: Gautier J-C. (Ed.), *Drug safety Evaluation: methods and protocols, methods in molecular Biology*, Springer Science and Business Media: 69-82.
- [18] Yabanoğlu, H., et al. (2014). Parasitic infections of the appendix as a cause of appendectomy in adult patients. *Türkiye Parazitoloji Dergisi*, 38: 12-16.
- [19] Okolie, B. I., et al. (2008). Incidence and detection of parasite ova in appendix from patients with appendicitis in South-eastern, Nigeria. *World Journal of Agricultural Sciences*, 4: 795-802.
- [20] Amer, A. S.; Saad, A. E.; Antonios, S. N. and Hasby, E. A. (2018). Prevalence of parasitic infections in surgically removed appendices: parasitological and histopathological studies. *Helminthologia*, 55 (1): 33-44.
- [21] Dorfman, S.; Cardozo, J.; Dorfman, D. and Del Villar, A. (2003). The role of parasites in acute appendicitis of pediatric patients. *Investigacion Clinica*, 44 (4): 337-340.
- [22] Lamps, L. W. (2010). Infectious causes of appendicitis. *Infectious Disease Clinics*, 24: 995-1018.
- [23] Hatipoğlu, S.; Lök, U.; Gülaçtı, U. and Çelik, T. (2016). Pre-operative stool analysis for intestinal parasites and fecal occult blood in patients with acute appendicitis. *Turkish Journal of Trauma and Emergency Surgery*, 22 (5): 471-476.
- [24] Katzin, W. E. and Petras, R. E. (2012). Vermiform appendix. In: Mills, S. E. (Ed.). *Histology for pathologists*. 4th Edn. Library of congress cataloging in publication data, USA: 697-708.
- [25] Vasudeva, N. and Mishra, S (2014). *Inderbir Singh's Textbook of human Histology with colour atlas and practical guide*. 7th Edn., Jaypee Brothers Medical Publishers, New Delhi: 439 pp.
- [26] George, J. R. (2016). Histological observations and its variations in appendix at different stages of life. *International Journal of Research in Medical Sciences*, 4 (6): 2324-2327.
- [27] Petroianu, A. and Barroso, TV. V. (2016). Pathophysiology of acute appendicitis. *JSM Gastroenterology and Hepatology*, 4 (3): 1062.
- [28] Nathans, A. A.; Merenstein, H. and Brown, S. S. (1953). Lymphoid hyperplasia of the appendix: clinical study. *Pediatrics*, 12 (5): 516-524.
- [29] Puri, P. and Mortell, A. (2006). Appendicitis. In: Stringer, M. D.; Oldham, K. T. and Mouriquand, P. D. E. (Eds.), *Pediatric Surgery and Urology: Long-term Outcomes*. 2nd Edn., Cambridge University Press, New York: 374- 384.

- [30] Jaaffer, H. S. (2011). Prevalence of *Gairdia lamblia* and *Entamoeba histolytic/Entamoeba dispare* infections among children in AL-Shulaa and AL-khadimya–Baghdad-Iraq. *Journal of university of Anbar for Pure science*, 5 (2): 6-10.
- [31] Aydin, Ö.(2007). Incidental parasitic infestations in surgically removed appendices: a retrospective analysis. *Diagnostic pathology*, 2: 1-5.
- [32] Lamps, L. W. (2009). *Surgical pathology of the gastrointestinal system: bacterial, fungal, viral and parasitic infections*. Springer Science and Business Media, New York: 224 pp.
- [33] Pehlivanoglu, B.; Aydin, B. T.; İşler, S.; Özdaş, S. and Abeş, M. (2019). Findings in appendectomies with *Enterobius vermicularis* infection: pinworm is not a cause of appendicitis. *Turkiye Parazitoloji Dergisi*, 43 (1): 21-25.
- [34] Hegazi, M. A. and Patel, T. A. (2012). Acute amoebic appendicitis: case reports and review of parasitic appendicitis. *Journal of the Pediatric Infectious Diseases Society*, 2 (1): 80-82.
- [35] Ito, D.; Hata, S.; Seiichiro, S.; Kobayashi, K.; Teruya, M. and Kaminishi, M. (2014). Amebiasis presenting as acute appendicitis: report of a case and review of Japanese literature. *International Journal of Surgery Case Reports*, 5: 1054-1057.
- [36] Bhatia, V.; Jawarkar, A.; Gohil, V. and Patel, D. (2017). Parasitic infection mimicking acute appendicitis in an adult male-a rare case. *International Clinical Pathology Journal*, 4 (5): 143-144.
- [37] Otan, E.; Akbulut, S. and Kayaalp, C. (2013). Amebic acute appendicitis: systematic review of 174 cases. *World journal of surgery*, 37: 2061-2073.
- [38] Garcia, L. S. (2007). *Diagnostic Medical Parasitology*. 5thEdn., ASM Press, USA: 1202 pp.
- [39] Sastry, A. S. and Bhat, S. (2014). *Essentials of Medical Parasitology*. Jaypee Brothers Medical Publishers, New Delhi: 341 pp.
- [40] Roberts, L. S.; Janovy, J. and Nadler, S. (2013). *Foundations of Parasitology*. 9thEdn. McGraw Hill, New York: 670 pp.
- [41] Ichikawa, H., et al. (2016), Amoebiasis presenting as acute appendicitis. *Tokai Journal of Experimental and Clinical Medicine*, 41 (4): 227-229.
- [42] John, D. T. and Petri, W. A. (2006). *Markell and Voge's Medical Parasitology*. 9thEdn., Saunders Elsevier, United States: 463 pp.
- [43] Mehlhorn, H. (2016) *Human parasites: diagnosis, treatment and prevention*. 7thEdn. Springer international publishing, Switzerland: 461 pp.
- [44] Shikani, H. and Weiss, L. M. (2014). Human Cryptosporidiosis: A clinical perspective. In: Cacciò, S. M. and Widmer, G. (Eds.). *Cryptosporidium: parasite and disease*. Springer-Verlag, Wien: 383-421.
- [45] Al-Shamiri, A. H.; Al-Zubairy, A. H. and Al-Mamari, R. F. (2010). The prevalence of *Cryptosporidium spp.* in children, Taiz District, Yemen. *Iranian journal of parasitology*, 5 (2): 26-32.
- [46] Rahi, A. A.; Ali, M. A. and Al-Charrakh, A. H. (2013). Prevalence of *Cryptosporidium parvum* among children in Iraq. *American Journal of Life Sciences*, 1 (6): 256-260.
- [47] Akhigbe, T.; Smith, F.; Adeyemo, A.; Adeyanju, T.; Condon, E. and Waldron, D. (2013). Pinworm and appendicitis in children. *The Internet Journal of Surgery*, 30 (3): 1-4.
- [48] Zarbaliyev, E. and Celik, S. (2018). Parasitic Appendicitis: A Novel Laparoscopic Approach for the Prevention of Peritoneal Contamination. *Canadian Journal of Infectious Diseases and Medical Microbiology*, 1-5.
- [49] Hamdona, S. M.; Lubbad, A. M. and Al-Hindi, A. I. (2016). Histopathological study of *Enterobius vermicularis* among appendicitis patients in Gaza strip, Palestine. *Journal of Parasitic Diseases*, 40 (1): 176-183.

تشخيص الاصابات الطفيلية في الزائدة الدودية لدى الاشخاص المصابين بالتهاب الزائدة في مدينة كركوك, العراق

خلود عبدالمطلب السعيدى ، فاطمة شهاب الناصري

قسم علوم الحياة , كلية العلوم , جامعة تكريت , تكريت , العراق

الملخص

انجزت الدراسة الحالية في مدينة كركوك من شهر تموز ولغاية شهر كانون الثاني 2018, اذ تم التحري عن الاصابات الطفيلية التي ربما تترافق مع التهاب الزائدة الدودية, حيث جمعت 197 عينة زائدة دودية مزالة جراحيا. تم التحري عن الطفيليات بأستخدام طريقة فحص محتوى الزائدة بطريقة الفحص المباشر وطرائق التركيز, وكذلك تم استخدام الفحص النسيجي للمقاطع النسيجية المصبوغة بصبغة الهيماتوكسلين والايوسين للكشف عن وجود الطفيلي داخل التجويف او النسيج. سجلت الاصابة الطفيلية في 12.69% حالة التهاب الزائدة دودية, وشملت الطفيليات المسجلة في هذه الدراسة اربعة انواع فضلا عن الاصابة الطفيلية المختلطة. وتضم الانواع المسجلة في الدراسة كل من طفيلي *Entamoeba histolytica* (الطور المتغذي والطور المتكيس), *Giardia lamblia* (الطور المتغذي والطور المتكيس), *Cryptosporidium sp.* (الطور المتكيس) و *Enterobius vermicularis* (الدودة البالغة والبيوض). تم تسجيل الاصابة بطفيلي *E. histolytica* بأعلى نسبة إذ بلغت 8.63% خلال الدراسة الحالية. كما سجلت الاصابة الطفيلية في الاناث بنسبة (8.12%) اكثر من الذكور (4.57%). لوحظ من نتائج الدراسة الحالية ان الاصابات الطفيلية كانت اكثر انتشارا في المصابين الذين تراوحت اعمارهم بين 13 و 18 سنة وكذلك 19 و 24 سنة (3.55% لكل فئة عمرية).