



Tikrit Journal of Pure Science

ISSN: 1813 – 1662 (Print) --- E-ISSN: 2415 – 1726 (Online)

Journal Homepage: <http://tjps.tu.edu.iq/index.php/j>



The protective role of the alcoholic extract crude of the *Plantago ovata* plant seed compared with zinc against the toxicity of cadmium chloride on some biochemical and histological parameters in the male reproductive system of the white rat

Mohammed Shwish Saleh , Qasim Azeez Razooqi

Biology Department . College of Education Pure Science, Tikrit University , Tikrit , Iraq

<https://doi.org/10.25130/tjps.v25i5.288>

ARTICLE INFO.

Article history:

-Received: 4 / 7 / 2020

-Accepted: 4 / 8 / 2020

-Available online: / / 2020

Keywords: Cadmium chloride, *Plantago ovata*, zinc, testis.

Corresponding Author:

Name: Mohammed Shwish Saleh

E-mail:

m.sh.saleh87@gmail.com

Tel:

ABSTRACT

This study was designed to find out the protective role of the alcohol Extract crude of *plantago ovata* compared to zinc, on some functional and histological criteria in male rats treated with cadmium chloride. The study was conducted in the animal house of Tikrit University / College of Veterinary Medicine for 30 days, 35 male white rats were used which were randomly divided into seven groups (5 animals per group). It was observed that the treatment of rats with CdCl₂ resulted in a significant decrease ($P \leq 0.01$) in the SSH, ICSH and testosterone hormones compared to the control group, while the dose of rats treated with cadmium chloride with the ethanol extract of *plantago ovata* seeds and the food supplement resulted in significant increases in the concentration of SSH hormones, ICSH And testosterone compared to treatment with cadmium chloride, Likewise, when healthy rats are dosed with the ethanol extract of *plantago ovata* seeds and zinc, we notice a significant increase in SSH, ICSH, and testosterone compared to control. The study showed that the treatment of rats with cadmium chloride and that a clear negative tissue change in the testes was represented by the destruction of the basal membrane of the seminal tubules and a small number of sperm cells, The dose of rats treated with CdCl₂ with extract and zinc resulted in a clear histological improvement.

Introduction

Plant extracts and their active elements as non-food chemical substances have a preventive or therapeutic action for many diseases, and they are of little or limited effect compared to the chemical drug manufactured in the laboratory [1]. Also, the plant extract is used in feed additives as sources of medicinal compounds to grow in order to meet modern consumer requirements for natural, safe and high-quality products [2]. The organism is constantly exposed to environmental pollutants and is one of the external sources of effective oxygen varieties and free radicals, especially pollution caused by factories, in particular the heavy element cadmium [3,4]. Cadmium has a wide toxic effect that leads to many physiological damages to various body parts such as the lung, testes, liver, kidneys, etc [5]. The testicles are among the organs that are the target of cadmium toxicity, and the mechanism of this toxicity is through

damage to the lining of blood vessels and affecting the number of Germ cells and Spermatids, Leydig cells and Sertoli cells, and reducing testosterone production [6]. That the *plantago ovata* seeds contain many secondary compounds and important chemicals, such as phenols, flavonoids, alkaloids and turbines, which provide an important source of antioxidants and also Vitamin C, as well as the seeds are contain mucous compounds used in the pharmaceutical industry [7]. As this plant is spread in a number of countries in the Mediterranean region, North Africa and southwestern Asia, including Iran and Iraq, India leads the world in the production and export of *plantago ovata* [8]. It is prescribed for treatment of many diseases including colds, hepatitis, skin and infectious diseases, diseases and problems related to the digestive system, respiratory system, organs, reproductive, circulatory system, cholesterol,

blood sugar, anti-inflammatory, antiviral and anti-hypertensive agent [7].

Material & methods

1- Design of experiment

First group: (the control group) this group was given distilled water and food daily for a period of 30 days.

Second group: This group was treated with cadmium chloride at a dose of 5 mg / kg of body weight.

Third Group: This group was treated with zinc at a dose of 5 mg / kg of body weight.

Fourth Group: This group was treated with the plantago ovata seed extract 100 mg / kg body weight.

Fifth group: This group was treated with plantago ovata seed extract 100 mg / kg body weight as well as cadmium chloride 5 mg / kg body weight.

Sixth Group: This group was treated with cadmium chloride 5 mg / kg body weight with zinc 5 mg / kg body weight

Seventh group: This group was treated with extract + cadmium chloride + zinc

2- Obtaining blood samples

The animals were starved for 24 hours at the end of the 30-day experiment and then drugged using chloroform as the animal was placed inside a glass container with a tight lid and then blood samples were collected through a stab in the heart using a syringe and blood was placed in gel tube tubes, and then the expulsion device was used Centrifuge at

3000 rpm for 10 minutes. Serum serum was placed in Eppendorf Tubes and kept under freezing at -80°C until the required biochemical tests.

3- Hormones tests

The level of sexual hormones has been estimated by following the steps provided with their ready-made analysis kit according to the manufacturer's special instructions regarding ELISA technology [9].

Statistical analysis

Significant differences were extracted using the ANOVA-one way test and confirming these differences through standard deviation. The moral differences were determined according to Duncan's multiple ranges and at the level of significance ($p \leq 0.01$) [10].

Results

1- Determining the effective dose for the alcoholic extract of a plantago ovata

Table (1) shows the determination of the dose most effective in reducing the level of glucose and cholesterol in the blood of male rats intact for the extract of the plantago ovata plant. It was found that the dose (100 mg / kg) is the most effective in reducing the level of glucose and cholesterol in the blood when compared with the control group and was adopted as a dose to assess the effect of the plant extract used in the study.

Table 1: shows the effective dose of Plantago ovata in reducing sugar and cholesterol level

Transactions variable	Control	<i>P. ovata</i> concentration (mg/kg)		
		50	100	200
Glucose conc. (mg/100 ml)	122.42 ± 14.17	118.15 ± 23.36	110.72 ± 17.27	124.43 ± 42.33
Cholesterol conc. (mg/100 ml)	101.36 ± 6.21	87.3 ± 6.59	71.00 ± 4.0	86.00 ± 6.57

- The values represent the mean ± standard deviation.
- The number of rats (3) in each group.

Hormonal variables:

It is noted from Table (2) that the treatment of male rats with CdCl₂ resulted in significant decreases ($P \leq 0.01$) in the concentration of SSH, ICSH and testosterone hormones compared to the control group, while the dose of rats treated with CdCl₂ with ethanol extract of plantago ovata seed, dietary supplement (Zinc) to the events of significant increase in the

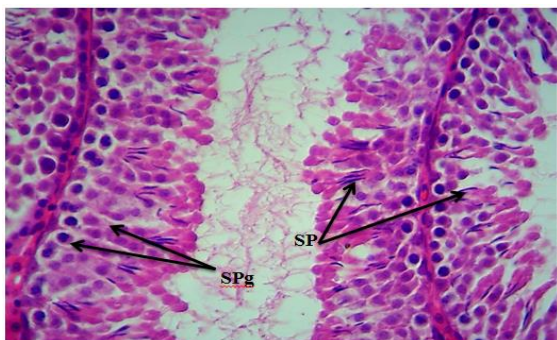concentration of FSH, LH and testosterone hormones compared with the treatment group with cadmium chloride, as well as when dosing healthy rats with ethanol extract for plantago ovata seeds, and zinc we note a significant increase in SSH, ICSH and testosterone hormones compared with the control group.

Table 2: concentrations of hormones in the blood serum

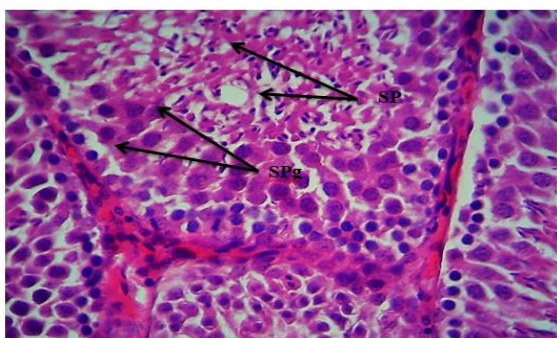
Transactions variable	ICSH (mIU/ml)	SSH (mIU/ml)	Testosterone (ng/ml)
Control	0.955 ± 1.226 b	1.701±0.619 a	1.059±0.018 b
CdCl ₂	0.532 ± 0.481 c	0.703±0.181 b	0.102±0.079 c
CdCl ₂ + Plantago ovata	2.173 ±0.356 a	1.552±0.123 a	1.026±0.016 b
CdCl ₂ + Zinc	0.682±0.027 bc	1.690±0.129 a	1.009±0.006 b
Plantago ovata+ CdCl ₂ + Zinc	1.189±0.302 b	1.785±0.637 a	1.073±0.028 b
Zinc	2.722±0.645 a	1.773±0.072 a	2.210±0.131 a
Plantago ovata	2.387±1.038 a	1.836±0.662 a	2.691±0.389 a

- The values represent the mean standard deviation.
- Vertically different letters mean a significant difference at the level of significance (P ≤ 0.01).
- The number of animals is 5 in each group.

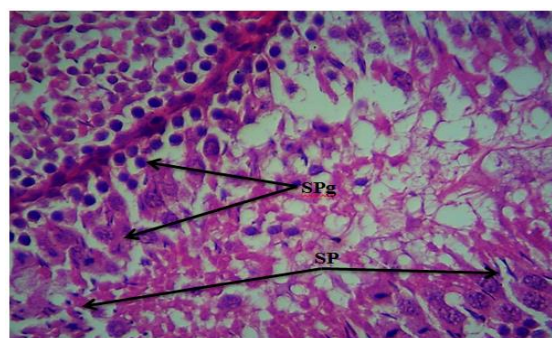
Histological Change



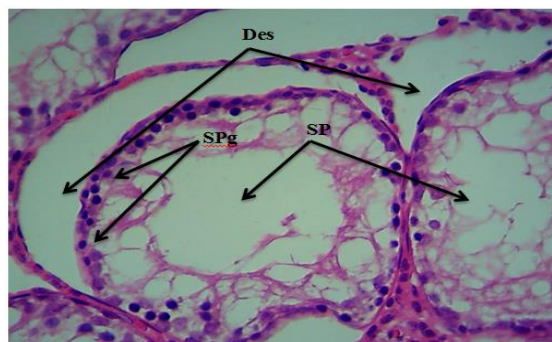
Picture 1: test group rat testis cross section showing the stages of sperm formation (SPg) and mature sperm (SP). H & E 400X,



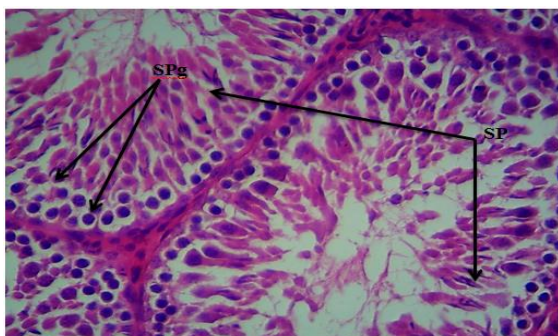
Picture 2: testis cross-section of the testis group's mice, showing the stages of spermatogenesis (SPg) and the increase of mature spermatogenesis (SP). H & E 400X



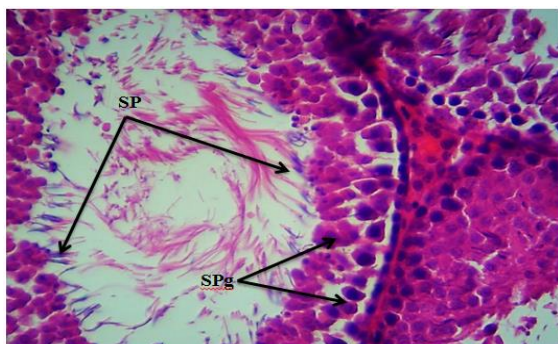Picture 3: testis cross section testis cross section showing the stages of sperm formation (SPg) and mature sperm (SP). H & E 400X



Picture 4: testis cross section of the cats with the cadmium group showing weakness in the stages of spermatogenesis (SPg), immature spermatogenesis (SP) and sperm intubation (Des.)



Picture 5: testis cross section of cats with cadmium and *Plantago ovata* showing sperm formation stages (SPg) and increasing mature sperm count (SP). H & E 400X



Picture 6: testis cross section of cats with cadmium and zinc, showing sperm formation stages (SPg) and increasing mature sperm count (SP). H & E 400X

Discussion

The results of the current study indicated that there is a decrease in the level of SSH, ICSH and testosterone hormones in the rats treated with cadmium chloride as in Table (2). The explanation for low testosterone is because cadmium increases the conversion of testosterone to estradiol. These results are consistent with a study [11]. Or it may be due to several reasons, including: The high effective oxygen classes (ROS) at the expense of antioxidants are permissions that work to obtain fat oxidation in the membranes of body cells, including the brain [12,13]. And stress works in various forms to the occurrence of inhibition in the hypothalamus-pituitary-testis axis and this inhibition occurs as a result of the activation of the Hypothlamo-pituitary-adrenocortical axis and thus the decrease in testosterone and luteinizing hormone [14]. Or the reason for low testosterone may be due to damage to testicular tissue in general and leydig cells in particular, as active oxygen classes (ROS) inhibit the reproduction of protein found in mitochondrial membranes in leydig cells, the main center for the manufacture of testosterone [15]. While the dose of rats treated with CdCl₂ with the ethanol extract of *plantago ovata* seed, zinc as in Table (2), caused

significant increases in the concentration of SSH, ICSH and testosterone hormones compared to the group treated with cadmium chloride, due to the components contained in the extract, represented by cyclosides, flavonoids and tropionides And alkaloids that maintain testicular tissue and sexual viability and sperm characteristics [16]. As existing compounds impede the formation of free radicals, these reduce oxidative stress on the hypothalamus, pituitary and testicle and increase the production of their hormones, or through their effects on reducing stress hormones such as cortisol [17]. As for the role of the efficacy of the flavonoids present in the extract, it is a group of multi-phenol compounds that possesses a free radical sweeping activity, in addition to its ability to inhibit the damages induced by the oxidation process and protect cells and tissues from the harmful effect of the types of effective oxygen [18,19]. Zinc is an important reproductive system in the male reproductive system, especially its role in hormonal metabolism, spermatogenesis and sperm motility, as a number of therapeutic nutrients have appeared to improve sperm count and motility such as Zinc, Arginine, Selenium, Vitamin B12 and antioxidants such as Clotathione and Vitamin E and C [20]. The histological examination of the testis of the male group of white rats showed treatment with cadmium that led to Desquamation in most of the seminal tubules, lack of sperm with thickening in other tubes, with very few numbers of sperm cells and loss of most stages of sperm formation, and the result was agreement With many studies, including one [21,22]. If they found that dose of rats with cadmium chloride at a dose of 5 mg / kg of body weight for 30 days leads to a decrease in body weight as a result of oxidative damage caused by cadmium chloride, and this has caused a decrease in the weight of the sexual reproductive organs, the cadmium chloride induces degeneration and necrosis of testicular tissue That may contribute to weight loss of the testicle [5]. While it is noticed that the protective role of *plantago ovata* and zinc extract is against cadmium toxicity in the testicle tissue of male white mice, since the *plantago ovata* extract possesses phenolic compounds, which are powerful antioxidants in the face of effective types of oxygen, thus protecting cells and tissues from the damage of oxidative stress [23]. As for zinc, it has stimulating effects that increase the cellular division of sperm ancestors, the presence of primary and mature sperms in the cavity of testicle and epididymal tubules, as well as an increase in myeloid and meiosis in the sperm cells [24].

References

- [1] Thanigaivel, S., Chandrasekaran, N., Mukherjee, A., & Thomas, J. (2016). Seaweeds as an alternative therapeutic source for aquatic disease management. *Aquaculture*, 464, 529-536.
- [2] Giannenas, I., Sidiropoulou, E., Bonos, E., Christaki, E., & Florou-Paneri, P. (2020). The history of herbs, medicinal and aromatic plants, and their extracts: Past, current situation and future perspectives. In *Feed Additives* (pp. 1-18). Academic Press.
- [3] Patar, A.; Giri, A.; Boro, F.; Bhuyan, K.; Singha, V. and Giri, S. (2016). Cadmium pollution and amphibians –studies in tadpoles of *Rana limnocharis*. *Chemosphere*, 144: 1043-1049.
- [4] Yuan, Y.; Wang, Y.; Hu, F.F.; Jiang, C.Y.; Zhang, Y.J.; Yang, J.L.; Zhao, S.W. and Liu, Z.P. (2016). Cadmium activate reactive oxygen species-dependent AKT/mTOR and Mitochondrial apoptotic pathway in neuronal cells. *Bioimed. Environm.Sci.* **29(2)**: 117-126.
- [5] Mohajeri, M., Rezaee, M., & Sahebkar, A. (2017). Cadmium-induced toxicity is rescued by curcumin: a review. *Biofactors*, **43(5)**, 645-661.
- [6] Alaei, S.; Talaiekhosravi, A.; Rezaei, S.; Alaei, K. and Yousefian, E. (2014). Cadmium and male fertility. *J. of Infertility and Reprod. Biology*, **2 (2)**: 62-69.
- [7] El-Feky, A. M., Elbatany, M. M., Naser, A. F. A., & Hamed, M. A. (2018). A therapeutic insight of carbohydrate and fixed oil from *Plantago ovata* L. seeds against ketoprofen-induced hepatorenal toxicity in rats. *Bulletin of the National Research Centre*, **42(1)**, 28.
- [8] Roumani, A., Alamdari, E. G., Biabani, A., Gholizadeh, A., & Karizaki, A. R. (2019). Effects of salicylic acid and spermine foliar application on some morphological and physiological characteristics of isabgol (*Plantago ovata* Forsk) under water stress.
- [9] Nasiadek, M., Danilewicz, M., Klimczak, M., Stragierowicz, J., & Kilanowicz, A. (2019). Subchronic Exposure to Cadmium Causes Persistent Changes in the Reproductive System in Female Wistar Rats. *Oxidative Medicine and Cellular Longevity*, 2019.
- [10] Bruning, J. L., and Kintz, B. L. (1987). Computational handbook of statistics. Scott, Foresman & Co.
- [11] Gomaa, M. D., Motawaa, M. A., Al-Nashar, A. M., & El-Sakka, A. I. (2018). Impact of subinguinal varicocele on serum testosterone to estradiol ratio in male patients with infertility. *Urology*, 117, 70-77.
- [12] Prasad, S. V., Ghongane, B. B., Chourishi, A., Vakade, K., & Kunkulol, R. R. (2018). Role of Antioxidants in Male Reproduction. *International Journal of Current Research in Physiology and Pharmacology (IJCRPP)*, 1-6.
- [13] Abdal Dayem, A. et al. (2017). The role of reactive oxygen species (ROS) in the biological activities of metallic nanoparticles. *International journal of molecular sciences*, **18(1)**, 120.
- [14] López-Doval, S., Salgado, R., & Lafuente, A. (2016). The expression of several reproductive hormone receptors can be modified by perfluorooctane sulfonate (PFOS) in adult male rats. *Chemosphere*, 155, 488-497.
- [15] Fallah, A., Mohammad-Hasani, A., & Colagar, A. H. (2018). Zinc is an essential element for male fertility: a review of Zn roles in men's health, germination, sperm quality, and fertilization. *Journal of reproduction & infertility*, **19(2)**, 69.
- [16] Subramoniam, A. (2016). *Plants with anti-diabetes mellitus properties*. CRC Press.
- [17] Winston, D. (2019). *Adaptogens: herbs for strength, stamina, and stress relief*. Simon and Schuster.
- [18] Gulcin, I. (2011). Antioxidant activity of eugenol: a structure-activity relationship study. *Journal of medicinal food*, **14 (9)**: 975-85.
- [19] Mahdavi, R.; Nikniaz, Z.; Rafraf, M. and Jouyban, A. (2010). Determination and comparison of total Polyphenol and vitamin C content of natural fresh and commercial fruit juices. *Pakistan Journal of Nutrition*. **9(10)**: 968-972.
- [20] Glenville, M. (2008). The nutritional approach to male factor infertility. *Dragons Tale*, 18, 4-5.
- [21] Hussein, Y.M.; Hussein, R.M.; Amin, A.I.; Mohamed, A.S.; Hussein, H.S. (2015). Evaluation of mesenchymal stem cells and vitamin E in treatment of infertile male albino rats. *International J of multidisciplinary and current research*, Vol.3: 942-951.
- [22] AL-Janabi, Q. A. R., Shaban, R. K., & AL-Kraie, N. I. H. (2019). The effectiveness of the protective role of beetroot juice for the male reproductive system of albino rats against the toxicity of cadmium chloride. *Tikrit Journal of Pure Science*, **24(1)**, 43-51.
- [23] Viladomiu, M.; Hontecillas, R.; Lu, P. and Bassaganya-Riera, J. (2013). Preventive and prophylactic mechanisms of action of pomegranate medicine. *Article ID 789764*. 1-18.
- [24] Salas-Huetos, A. et al. (2018). The effect of nutrients and dietary supplements on sperm quality parameters: a systematic review and meta-analysis of randomized clinical trials. *Advances in Nutrition*, **9(6)**, 833-848.

الدور الوقائي للمستخلص الكحولي الخام لبذور نبات *Plantago ovata* مقارنة مع الخارصين ضد
سمية كلوريد الكاديوم لبعض المعايير الكيموحيوية والنسجية في الجهاز التناسلي
الذكوري للجرذان البيض

محمد شويش صالح ، قاسم عزيز رزوقي

قسم علوم الحياة ، كلية التربية للعلوم الصرفة ، جامعة تكريت ، تكريت ، العراق

الملخص

صممت هذه الدراسة لمعرفة الدور الوقائي للمستخلص الكحولي الخام لنبات الزباد مقارنة بالخارصين على بعض المعايير الوظيفية والنسجية في ذكور الجرذان البيض المعاملة بكلوريد الكاديوم. أجريت الدراسة في البيت الحيواني التابع إلى جامعة تكريت / كلية الطب البيطري لمدة 30 يوم ، تم استخدام (35) من الجرذان البيض والتي وزعت عشوائياً إلى مجاميع (5 حيوانات لكل مجموعة). اذ لوحظ أن معاملة الجرذان بـ $CdCl_2$ أدى إلى انخفاض معنوي ($P \leq 0.01$) في الهرمون اللوتيني LH الذي يسمى في الذكور بالهرمون الذي يحفز الخلايا الخالية ICSH Interstitial cell-stimulating hormone والهرمون المحفز للجريبات SSH في الذكور Stimulating Sperms Hormone والشحمون الخصوي مقارنة مع مجموعة السيطرة، بينما أدى تجرع الجرذان المعاملة بكلوريد الكاديوم بالمستخلص الكحولي لبذور الزباد والمكمل الغذائي إلى أحداث ارتفاع معنوي في تركيز هرمونات SSH ، ICSH والشحمون الخصوي مقارنة مع المعاملة بكلوريد الكاديوم ، وكذلك عند تجرع الجرذان السليمة بالمستخلص الإيثانولي لبذور الزباد والخارصين نلاحظ ارتفاع معنوي في هرمونات SSH ، ICSH والشحمون الخصوي بالمقارنة مع السيطرة. وبينت الدراسة أن معاملة الجرذان بكلوريد الكاديوم أدت إلى تغيرات نسجية سلبية واضحة في الخصى تمثلت بتحطم الغشاء القاعدي للنبيبات المنوية وأعداد قليلة من الخلايا المولدة للنطف، أما تجرع الجرذان المعاملة بـ $CdCl_2$ بالمستخلص والخارصين أدى إلى تحسن نسجي واضح.