



## Effect of Cadmium chloride on the Liver, kidney and heart tissues and the protective role of pomegranate seed oil in male Albino rats.

Rashid Khamees Shaban , Mohammed Khalil Ibrahim , Qasim Azeez Razooqi

College of Education for Pure Sciences , Tikrit University , Tikrit , Iraq

<https://doi.org/10.25130/tjps.v25i5.284>

### ARTICLE INFO.

#### Article history:

-Received: 6 / 6 / 2020

-Accepted: 22 / 6 / 2020

-Available online: / / 2020

**Keywords:** pomegranate seed oil, Cadmium chloride, histopathological lesions, fibrosis, necrosis.

#### Corresponding Author:

**Name:** Rashid Khamees Shaban

#### E-mail:

[rashid.khamees@tu.edu.iq](mailto:rashid.khamees@tu.edu.iq)

#### Tel:

### ABSTRACT

This experiment was designed to identify the protective role of pomegranate seed oil against the toxicity of Cadmium chloride on the tissues of the liver, kidneys and heart, as it distributed 24 male rats to four groups. The results of microscopic examination of the target organs tissues many of histological lesions after treating animals with Cadmium chloride represented by necrosis, fatty degeneration and fibrosis around the central vein in the liver tissue, swelling of the glomeruli, necrosis of kidney tissue, necrosis within the myocardial fibers and hemorrhage within heart tissue .

Mention the present result shown the results of the group treated with pomegranate seed oil with Cadmium chloride have been shown, returned of most tissues to the semi-normal state, with some negative effects of Cadmium chloride remaining

### Introduction

Cadmium (Cd) is a soft, bluish-white heavy metal; present naturally in the environment and has the symbol Cd. There is about 25000 tons of it in the earth crust, and are naturally released into the environment [1]. Cd is a ubiquitous environmental pollutant owing to its widespread use in industry throughout the world. It is a nonessential heavy metal with teratogenicity carcinogenic and mutagenic effects as a pollutant [2]. It can cause severe toxicity in various organs - mainly the kidney, liver, Heart, - which leads to urinary, digestive and circulatory system dysfunction and human health hazards, the chronic cadmium poisoning is caused by prolonged cadmium ingestion [3].

Cadmium may induce oxidative damage in different tissues by enhancing peroxidation of membrane lipids in tissues and altering the antioxidant systems of the cells [4]. Increased emissions of metals in the environment and their non-biodegradability have increased the risk of human exposure. The main routes of Cd exposure are ingestion and inhalation due to its presence in food, air, and tobacco leaves [5]. Cd is a heavy metal environmental contaminant in soil often associated with zinc, lead or copper, this metal can be absorbed through roots of developing vegetables later consumed by humans or animals [6].

There are many studies on the preventive role of many natural anti-oxidants against mineral toxicity, as herbs are generally considered safe and have proven effective against various human diseases and their medicinal uses have increased gradually in most countries, Natural antioxidants strengthen the endogenous antioxidants defenses from reactive oxygen species and restore the optimal balance by neutralizing the reactive species [7].

Pomegranate, *Punica granatum* L., is an ancient medicinal food plant which natively grows from the Himalayas in northern India to Middle East, but has also been cultivated and naturalized in many other regions including Mediterranean, Southeast Asia, tropical Africa, and American Southwest[8]. Pomegranate (*Punica granatum*) is a fruit belonging to the Punicaceae family [9]. It is broadly implanted in the Middle East, many tropical and subtropical countries [10]. Pomegranate seeds are rich in sugar, polyunsaturated fatty acids, vitamins, polysaccharides, polyphenols and minerals [11]. In particular, pomegranate seed oil contains high levels of phenolic compounds which is punicic acid, punicalagins (PNG), as well as important fatty acids such as linoleic acid, gallic acid and elagic acid [12] Ellagic acid is a polyphenol compound with antioxidant and anti-proliferative properties that also

exists in many other fruits and plants such as raspberries, pecan nuts and strawberries components demonstrate anti-inflammatory and antioxidant by inhibiting the expression of pro-inflammatory enzymes [13]. anti-carcinogenic, antioxidant [14].

### Material and Methods

#### (1) Animals

24 adult male rats weighting 180-200 gm. were used for this study. The animals were obtained from animal house unit in the College of Veterinary Medicine, Tikrit University. The animals were housed in a room under standard conditions of ventilation, temperature ( $25 \pm 2$ )°C, humidity (60-70)% and light/dark condition (12/12). The animals were provided with tap water ad libitum and fed with the standard commercial chow.

#### (2) Experimental Design

The animals were randomly distributed into four groups:

Group 1- Animals were given distilled water and kept as control.

Group 2- Animals were given Pomegranate seeds oil (0.8) ml/ kg BW for 30 days [15].

Group 3- Animals were treated at a dose of Cadmium chloride (5) mg/kg BW for 30 days, [16].

Group 4 – Animals were given Pomegranate seeds oil (0.8) ml/ kg BW with Cadmium chloride (5) mg/kg BW for 30 days.

All experiment animals were orally administered.

#### (3) Histological study

Liver, kidney and heart tissue samples were fixed in 10% formalin for 24 hours, then washed by water and were dehydrated by ethyl alcohol in increasing concentrations (70, 80, 95, 100 and 100)%, clearing with xylene and then embedded with paraffin all paraffin embedded tissue was sectioned at 5  $\mu$ m, and stained with Hematoxylin and eosin. These specimens were examined under a light microscope at 400X magnification power. Corresponding digital images were captured for later analysis [17].

### Results

The results of histological examination for the group treated with Cadmium chloride showed the presence of fatty degeneration with fibrosis around the central vein and the presence of congestion in the central vein (Figures 2,3) as well as the presence of Hemorrhage instead of bleeding in the tissues of the kidneys within glomeruli and infiltration of inflammatory cells (Figure 7). Myocardial degeneration instead of myocardial fibers (Figure 11) compared to the control group (Figures 1,6,10).

While it was observed in the group treated with pomegranate seed oil, most of the liver, kidney and heart tissues presence normal state (Figures 5,8,13).

The group of treated Cadmium chloride and pomegranate seed oil, most of the liver, kidney and heart tissues presence returned to normal state, with some residual effects in the tissues of these organs (Figures 4,9,12).

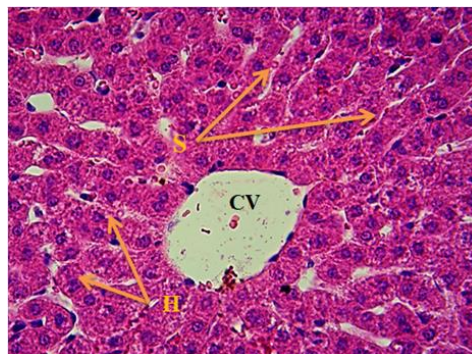


Fig. 1: liver section of the control group showing the central vein (CV) and hepatocytes (HC) arranged around it in the form of cell cords and sinusoids (S). H&E 400X

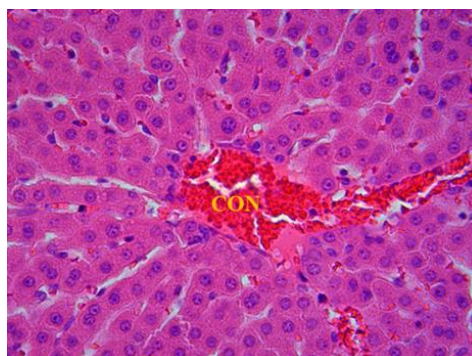


Fig. 2: liver section of the group treated with Cadmium chloride showing clear congestion in the central vein (CON). H&E 400X

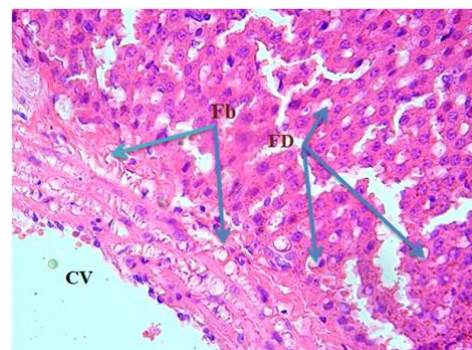


Fig. 3: Liver section of the group treated with Cadmium chloride showing fatty degeneration (FD) in hepatic cells and fibrosis (Fb) around the central vein (CV). H&E 400X

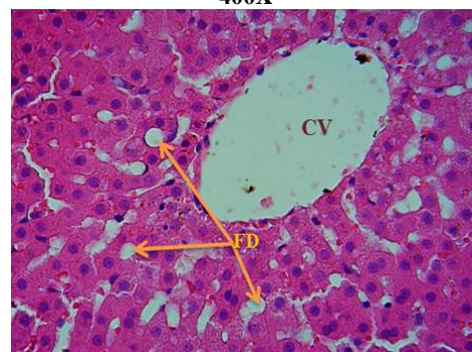


Fig. 4: liver section of the group treated with Cadmium chloride and pomegranate seed oil showing fatty degeneration (FD) and central vein (CV) normal state. H&E 400X



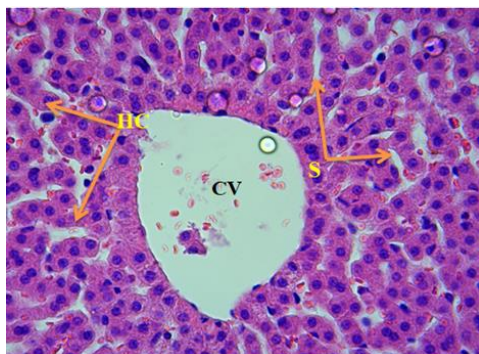


Fig. 5: Liver section of the group treated with pomegranate seed oil showing the central vein (CV), hepatocyte (HC) and sinusoidal (S) normal state. H&E 400X

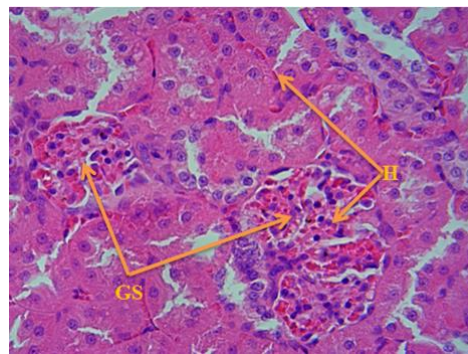


Fig. 9: kidney section of the group treated with Cadmium chloride and pomegranate seed oil showing swelling of the renal glomerulus (GS) with hemorrhage (H) within the kidney tissue and renal glomerulus. H&E 400X

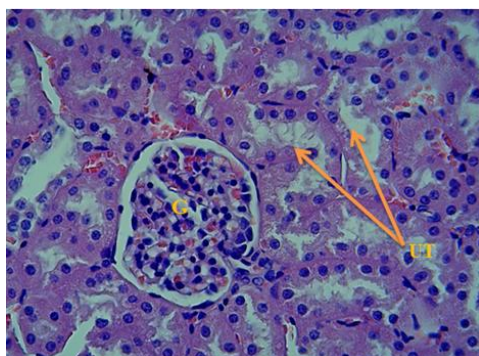


Fig. 6: Kidney section of the control group showing renal glomerulus (G) and proximal convoluted tubules (PCT) and distal tubules (DCT). H&E 400X

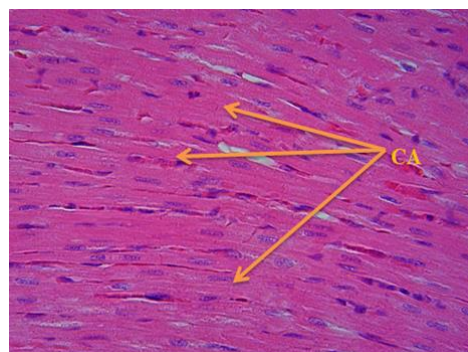


Fig. 10: Heart section of the control group showing normal myocardial fibers (CA). H&E 400X

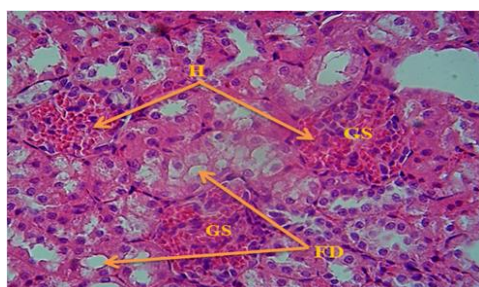


Fig. 7: kidney section of the group treated with Cadmium chloride showing the glomerulus swelling (GS) with fatty degeneration (FD) within the urinary tubules and hemorrhage (H) in the glomeruli. H&E 400X

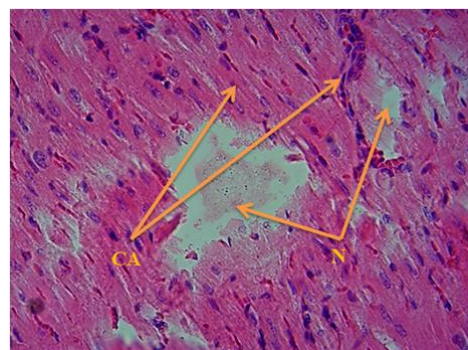


Fig. 11: Heart section of the group treated with Cadmium chloride showing necrosis of cardiac muscle fibers (N) and irregular myocardial fibers (CA). H&E 400X

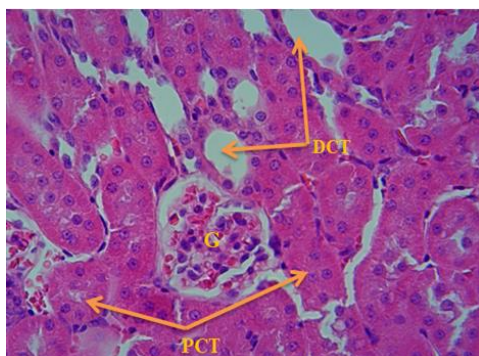


Fig. 8: kidney section of the group treated with pomegranate seed oil showing renal glomerulus (G) and urinary tubules (PCT) (DCT) as normal. H&E 400X

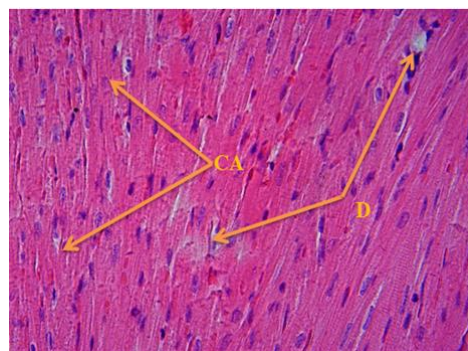
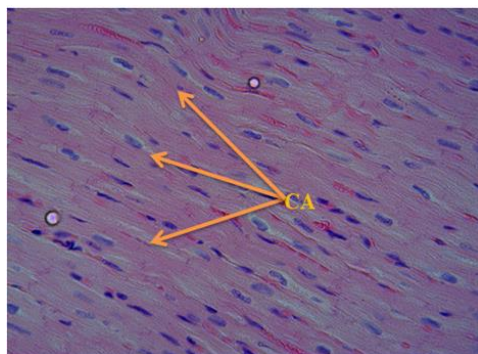


Fig. 12: Heart section of the group treated with Cadmium chloride and pomegranate seed oil showing the regularity of myocardial fibers (CA) with the degeneration (D) in some fibers. H&E 400X



**Fig. 13: Heart section of the group treated with pomegranate seed oil showing the myocardial fibers (CA) with normal state. H&E 400X**

### Discussion

The results of the current study showed that animals treated with Cadmium chloride at a dose of 5 mg / kg of body weight, tissue lesions in the liver were represented of fatty degeneration with fibrosis around the central vein and the presence of congestion in the blood vessels of the liver, kidney and coronary blood vessels of heart, effect of oral Cadmium chloride on glutathione, Cadmium can induce severe changes in tissues due to lipid peroxidation and free radical generation. [18], [19]. Cadmium chloride (25) mg/l given 45 days in drinking water reduced glutathione in liver, brain and kidney tissue of rabbits. This finding is confirmed by study which showed similar results in adult rabbits given 200ppm Cadmium chloride in drinking water[20]. Others reported, similar results in liver and kidney of rats [21]. The reduction may have been caused the mechanism by which Cd is absorbed, transported and taken up by cells is still not fully understood. As a toxic metal, there is unlikely to be specific transport proteins for Cd. Rather, because Cd has similar chemical and physical properties to essential metals such as iron (Fe), zinc (Zn) or calcium (Ca), it can be transported and taken up into the cells by a process referred to as "ionic and molecular mimicry" [22].

It has been proposed that acute hepatotoxicity injury, involves a direct toxic effect of the metal, ischemia due to endothelial cell injury, and the latter inflammatory injury, in which Kupffer cell activation and neutrophil infiltration play a major role through a cascade of inflammatory mediators [23]. Some histopathological changes such as loss of normal architecture of the parenchymatous tissue, cytoplasmic vacuolization, cellular degeneration and necrosis, congested blood vessels, destructed mitochondria cristae, fat globules, severe glycogen depletion, lipofuscin pigments, and collagenous fibers formation are observed in liver tissue from rats exposed to Cd for 22 days [24].

These cellular changes may result in both apoptosis and necrosis. the changes that indicate toxic cardiomyopathy in myocardial tissue were verified. A cross-striated banding pattern of cardiac cells was ruined. Prominent atrophy and hydropic degeneration

of subendo - cardial localized cardiac cells with focal myo-cytolysis was found in the experimental group myocardium, even in the seventies, it was observed that cells exposed to cadmium showed significant changes in the cell organelles such as ribosomes disintegration, Endoplasmic reticulum (EPR) destruction and mitochondrial swelling [25]. Later findings established that Cd in mammalian cells directly inhibits or stimulates the activity of different enzymes [26], disrupts the proper formation of membrane proteins and secreting proteins [27] and inhibits the activity of antioxidant enzymes directing cytoplasmic redox potential toward oxidation, with increased reactive oxygen species (ROS) and reactive nitrate compounds [28].

The result in selective changes in cell signaling mechanisms as well as enhancing protein and DNA damage, and promote cytotoxicity. Elevated levels of lipid peroxides and aldehydes have been observed in atherosclerosis, ischemia-reperfusion, heart failure, Alzheimer's disease, rheumatic arthritis, cancer, and other immunological disorders, ROS cause damage to cellular proteins, nucleic acid, and lipids, leading to cell membrane damage and cellular dysfunction, This may be due to hepatocellular necrosis, which causes the release of these enzymes into the blood circulation after cellular damage and rupture of the plasma membrane [29].

As for the group that was treated with Cadmium chloride and pomegranate seed oil (PSO) most of the tissues returned to normal. It may be due to the prevention of the leakage of intracellular enzymes by its membrane stabilizing activity. In several studies, PSO administration led to significant reduction of Malondialdehyde (MDA) concentration in tissue homogenate samples [30],[31]. Low dose PSO application reduced significantly oxidative stress and NADPH oxidase activity in both ischemic at the same time, low-dose PSO extract reduced TNF- $\alpha$  levels and significantly increased antioxidant activity [32]. In previously, It is demonstrated that anti-apoptotic effect of PSO on brain hypoxic ischemia through inhibition of caspase 3 [33]. Study showed that pomegranate seed oil clearly attenuated Hexachlorobutadiene (HCB) induced nephrotoxicity, PSO may decrease HCB-induced nephrotoxicity by quenching these toxic metabolites [34]. Other possibilities are the inhibitory effects of PSO on enzymes involved in the bioactivation of HCB such as glutathione-S-transferase (GST) or cysteine-S-conjugate b-lyase. Recently, decreased GST activity and transcription were observed in mice that ingested pomegranate. The authors claimed that GST inhibition could reflect the decrease in protein damage, which will, most likely, translate into less GST activity [35].

The inhibitory effects of plant polyphenol on GST(s) has also been shown in vitro, experimental studies have also demonstrated that inhibitors of ysteine-S-



conjugate b-lyase (such as aminooxyacetic acid) reduced HCBd induced nephrotoxicity [36].

### Conclusion

The results of the study showed that cadmium chloride led to tissue lesions in the liver, kidney and

heart tissues represented by degeneration, necrosis and fibrosis in some organs, while pomegranate seed oil showed a protective role against the toxicity of Cadmium chloride and the return of most of the tissues under study to the semi-normal state.

### References

- [1] Nazima, B. and Manoharan, V. (2014). Cadmium toxicity: oxidative stress and organ dysfunction. *Journal of Toxicology*, **4**(2):14–31.
- [2] Burger, J. (2008). Assessment and management of risk to wildlife from cadmium. *Science Total Environments*. **389**(1): 37-45.
- [3] Takaki, A. et al. (2004). Long-term cadmium exposure accelerates age-related mitochondrial changes in renal epithelial cells. *Toxicology* **203**(1): 145-154.
- [4] Renugadevi, J. and Prabu, S.M. (2010). Cadmium-induced hepatotoxicity in rats and the protective effect of naringenin. *Experiments Toxicology and Pathology*, **62**(2): 171-181
- [5] Tchounwou, P.B.; Yedjou, C.G.; Patlolla, A.K. and Sutton, D.J. (2012). Heavy metal toxicity and the environment. *Experientia Supplementum*, **101**(1):133–164.
- [6] Ikediobi, C. (2014). Response of antioxidant enzyme and redox metabolites to cadmium induced oxidative stress in CRL-1439 normal rat liver cells. *International Journal of Molecular and Medicine*, **14** (1): 87-92.
- [7] Heeba, G. and Abd-Elghany, M. (2010). Effect of combined administration of ginger (*Zingiber officinale roscoe*) and atorvastatin on the liver of rats. *Phytomedicine* ,**17**(14):1076-1081.
- [8] Jurenka, J. (2008). Therapeutic applications of pomegranate (*Punica granatum L.*). *Alternative Medicine Review* **13**(2):128–144.
- [9] Elfalleh, W. et al. (2009). Physico-chemical properties and DPPH-ABTS scavenging activity of some local pomegranate (*Punica granatum*) ecotypes. *International Journal of Food and Nutritional Sciences*. **60** (2):197–210.
- [10] Jurenka, J. (2000). Therapeutic applications of pomegranate (*Punica granatum L.*) a review. *Alternative Medicine Review*. **13**(2):128–44.
- [11] Afaq, F.; Saleem, M.; Krueger, C.; Reed, J. and Mukhtar, H. (2005). Anthocyanin and hydrolyzable tannin-rich pomegranate fruit extract modulates MAPK and NF-kappaB pathways and inhibits skin tumorigenesis in CD-1 mice. *International Journal of Cancer*. **113**(3):423-433.
- [12] Xu, J. et al.(2005). Intervention of antioxidant system function of aged rats by giving fruit juices with different antioxidant capacities. *Zhonghua Yu Fang Yi Xue Za Zhi*. **39**(2):80-83.
- [13] Rasheed, Z. et al.(2009). Polyphenol-rich pomegranate fruit extract (POMx) suppresses PMACI-induced expression of proinflammatory cytokines by inhibiting the activation of MAP kinases and NF-kappa B in human KU812 cells. *Journal of Inflammation*. **6**(1): 1–30.
- [14] Bouroshaki, M.; Sadeghnia, H.R.; Banihasan, M. and Yavari, S. (2010). Protective effect of pomegranate seed oil on hexachlorobutadiene induced nephrotoxicity in rat kidneys. *Renal Failure*. **32**(5): 612-617.
- [15] Mohammad, T.; Azar, H.; Karim, D. ; Hamid, M. and Arezoo, R. (2016). Protective Effect of Pomegranate Seed Oil against Mercuric Chloride-Induced Hepatotoxicity in rat. *Acta Poloniae Pharmaceutica* . **73** ( 4 ): 991-997.
- [16] Adnaik, R.S.; Gavarkar, P.S. and Mohite, S.K.(2015). Evaluation of antioxidant effect of *Citrullus vulgaris* against cadmium-induced neurotoxicity in Mice brain . *International Journal of Pharmaceutical Science and Research*. **6**(10): 4316-4323.
- [17] Elbandy M.A., Ashoush I.S. (2012). Phytochemicals in Pomegranate Seeds and Their Effect as Hypolipidemic Agent in Hypercholesterolemic Rats *World Journal of Dairy and Food Sciences*. **7**(1): 85-92.
- [18] Khalid, A. H.; Wasan, S. O. and Dakheel, H. H. (2018). Effect of oral Cadmium chloride on glutathione and malondialdehyde in kidney, liver and brain tissues of young female albino rabbits. *Online Journal of Veterinary Research* **22**(9):847-850.
- [19] Sarkar, S. (2005). Cadmium-induced lipid peroxidation and the status antioxidant system in rat tissue. *Journal of Trace Element Medicine and Biology*. **9**(3): 144-149.
- [20] Beytut, E. and Aksakal, M. (2012). The effect of long-term supplemental dietary cadmium on lipid peroxidation and the antioxidant system in the liver and kidneys of rabbits. *Turkish Journal of Veterinary and Animal. Science*. **26**(1). 1055-1060.
- [21] Chan, H.M. (2006). Ontogenic change in hepatic metallothionein isoform in prenatal and newborn rats. *Biochemical and Cellular Biology*. **71**(3): 133-140
- [22] Vesey, D.A. (2010). Transport pathways for cadmium in the intestine and kidney proximal tubule: Focus on the interaction with essential metals. *Toxicology Letters*. **198**(1): 13-19.
- [23] Yamano, T.; DeCicco, L.A. and Rikans, L.E. (2000). Attenuation of cadmium-induced liver injury in senescent male fischer 344 rats: role of Kupffer cells and inflammatory cytokines. *Toxicology and Applied Pharmacology* .**162**(1): 68-75.
- [24] El-Sokkary, G.; Nafady, A. and Shabash, E.H. (2010). Melatonin administration ameliorates cadmium-induced oxidative stress and morphological changes in the liver of rat. *Ecotoxicology and Environmental Safety* **73**(3): 456-463.
- [25] Kawahara, H.; Takashima, Y.; Nakamura, M. and Yamagami, A. (1975). Electron microscopic

- study of the cytotoxicity of cadmium and mercury in vitro. *Journal of Dental Research*. **54(1)**: 125-130.
- [26] Puri VN, Saha S.(2003) Comparison of acute cardio vascular effects of cadmium and captopril in relation to oxidant and angiotensin converting enzyme activity in rats. *Drug and Chemical Toxicology*. **26(3)**: 213-218.
- [27] Huang, Q.Y.; Fang, C.W. and Huang, H.Q. (2011). Alteration of heart tissue protein profiles in acute cadmium-treated scallops *Patinopecten yessoensis*. *Archives of Environmental Contamination and Toxicology*. **60(1)**: 90-98.
- [28] Liu, J.; Qu, W. and Kadiiska, M.B. (2009). Role of oxidative stress in cadmium toxicity and carcinogenesis. *Toxicology and Applied Pharmacology*. **238(3)**: 209–214.
- [29] Ramana, K.V.; Srivastava. S. and Singhal, S.S.(2013). Lipid peroxidation products in human health and disease. *Oxidative Medicine and Cellular Longevity*. **201(1)**:5834-5838.
- [30] Bialek, A.; Stawarska, A.; Bodecka, J.; Bialek, M. and Tokarz, A. (2017). Pomegranate seed oil influences the fatty acids profile and reduces the activity of desaturases in livers of Sprague Dawley rats. *Prostaglandins and Others Lipid Mediator*. **131(2)**: 9-16.
- [31] Boroushaki, M.T. et al. (2014). Protective effect of pomegranate seed oil against mercuric chloride-induced nephrotoxicity in rat. *Renal. Failure*. **36(10)**: 1581-1586.
- [32] Yayla, M.; Cetin, D.; Adali, Y.; Kilicle, P. A. and Toktay, E.(2014). Potential therapeutic effect of pomegranate seed oil on ovarian ischemia/reperfusion injury in rats. *Iranian Journal of Basic Medical Sciences*. **21(12)**:1262-1268.
- [33] Shaban, N.Z.; El-Kersh, M.A.; El-Rashidy, F.H. and Habashy, N. (2013). Protective role of Punica granatum (pomegranate) peel and seed oil extracts on diethylnitrosamine and phenobarbital-induced hepatic injury in male rats. *Food Chemistry*. **141(3)**:1587-1596.
- [34] Bouroshaki, M. T.; Sadeghnia, H. R.; Banihasan, M. and Yavari, S. (2010). Protective effect of pomegranate seed oil on hexachlorobutadiene-induced nephrotoxicity in rat. *Renal Failure*. **32(5)**: 612-617.
- [35] Faria, A.; Monteiro, R.; Mateus, N.; Azevedo, I. and Calhau, C. (2007). Effect of pomegranate (*Punica granatum*) juice intake on hepatic oxidative stress. *European Journal Nutrition*. **46(5)**:271–278.
- [36] de Ceaurriz, J. and Ban. M. (1990). Role of gamma-glutamyltranspeptidase and beta-lyase in the nephrotoxicity of hexachloro-1,3-butadiene and methyl mercury in mice. *Toxicology Letters*. **50(3)**:249–256.

## تأثير كلوريد الكاديوم على أنسجة الكبد والكلية والقلب والدور الوقائي لزيت بذور الرمان

### في ذكور الجرذان البيض

راشد خميس شعبان ، محمد خليل ابراهيم ، قاسم عزيز رزوقي

كلية التربية للعلوم الصرفة ، جامعة تكريت ، تكريت ، العراق

### الملخص

صممت هذه التجربة لتحديد الدور الوقائي لزيت بذور الرمان ضد سمية كلوريد الكاديوم على أنسجة الكبد والكلية والقلب في ذكور الجرذان البيض، حيث وزعت 24 ذكر من الجرذان البيض على أربع مجاميع بواقع ستة جرذان لكل مجموعة، وقد اظهرت نتائج الفحص المجهرى لأنسجة الأعضاء المستهدفة العديد من الآفات النسيجية بعد معاملة الحيوانات بكلوريد الكاديوم تمثلت في حدوث نخر نسجي وتتكس دهني وتليف حول الوريد المركزي في أنسجة الكبد ، وتورم الكبيبات الكلوية ونخر في أنسجة الكلية ، ونخر ضمن الاليف القلبية ونزيف داخل أنسجة القلب. في حين أظهرت نتائج المجموعة المعاملة بزيت بذور الرمان مع كلوريد الكاديوم ، عودة معظم الأنسجة إلى الحالة شبه الطبيعية ، مع بقاء بعض التأثيرات السلبية لكلوريد الكاديوم .