

Effects of *Glycyrrhiza glabra* Root extract On Some Physiological Parameters in albino male rats treatment with lead acetate

Rasha Shamil Hussein¹, Sura Saad AbulAzeez²

¹ Dept. of biology, College of Education, Univ. of Tikrit, Tikrit, Iraq

² Dept. of Basic Nursing sciences, College of Nursing, Univ. of Tikrit, Tikrit, Iraq

Abstract

The present study used 20 albino rats that distributed randomly to five groups (each group contain 4 rats), the first group was control group administrated only normal diet and water, the second group administrated with lead-acetate for four weeks, the third group administrated with lead-acetate for six weeks, the fourth group administrated with lead-acetate for four weeks and then, treated with 1ml root extract for 15 days, the fifth group administrated with lead-acetate for six weeks and then, treated with 1ml root extract for 15 days. The ALT, AST, ALP, bilirubin and creatinine levels were increased while albumin levels were decreased and showed high significant changes ($P < 0.01$) in groups that administrated with lead-acetate compared with control group, but the levels of all parameters back to normal when the groups that administrated with lead-acetate treated with *Glycyrrhiza glabra* root extract. It was concluded from this study that roots extract has amply good effect on liver and kidneys enzymes.

Introduction

Glycyrrhiza glabra (Licorice) is a ligneous perennial shrub growing in Mediterranean region and Asia widespread in Turkey, Italy, Spain, Russia, Syria, Iran, China, and Israel. (1&2). The plant, having multi-year production-cycle, has blue, violet flowers[1].

The licorice shrub is a member of the pea family and grows in subtropical climates in rich soil to a height of four or five feet.

It has oval leaflet white to purplish flower clusters, and flat pods.

Below ground, the licorice plant has an extensive root system with a main taproot and numerous runners.

The main taproot, which is harvested for medicinal use, is soft, fibrous, and has a bright yellow interior[3].

Glycyrrhiza is derived from the ancient Greek term *glykos*, meaning sweet, and *rhiza*, meaning root.

Licorice extracts have been used for more than 60 years in Japan to treat chronic hepatitis, and also have the therapeutic benefit against other viruses, including human immunodeficiency virus (HIV), cytomegalovirus (CMV), and Herpes simplex. Deglycyrrhizinated licorice (DGL) preparations are useful in treating various types of ulcers, while topical licorice preparations have been used to soothe and heal skin eruptions, such as psoriasis[4], and also Licorice extracts have been used to treat the cough suppression [5], treatment of early Addison disease [6, 7] and the Glycyrrhizin, a triterpenoid compound, accounts for the sweet taste of licorice root. This compound represents a mixture of potassium-calcium-magnesium salts of glycyrrhizic acid. Research shows that on being broken down in the gut, glycyrrhizin exerts an anti-inflammatory action similar to hydrocortisone and other corticosteroid hormones [8]. Lead (Pb) is a heavy soft metal occurs in nature as oxide or salts, it is one of the most hazardous and cumulative environmental pollutants. Lead poisoning causes disorders in haemopoietic system, gastrointestinal and muscular weakness [9].

Also, Lead has been associated with various forms of cancer, nephrotoxicity, central nervous system effects and cardiovascular diseases in human [10]. Therefore, the present study designed to show the protective effects of *Glycyrrhiza* root extract against lead-acetate toxicity in the liver and kidneys.

Kingdom: Plantae

Division: Angiospermae

Class: Dicotyledoneae

Order: Rosales

Family: Leguminosae

Genus: *Glycyrrhiza*

Species: *glabra* Linn [11].

Materials & methods

Animal model

Twenty adult male albino rats, (wt225-250 g) age (4-6 months) obtained from the Public company of medicines manufacture and requirements medicals - Samara, Iraq, and kept on standard pellet diet and water.

Glycyrrhiza glabra root extract

Licorice root was prepared from Kirkuk market. Licorice roots were dried and grinded into powder. The powder was used for extraction. Four grams of dried powder was suspended in 100mL sterile distilled water and kept in 37°C for 24 hours and then incubated for eight hours in room temperature while being mixed by magnetic mixer. In the next step, the suspension was kept 18 hours at room temperature. The final mixture was passed through 0.45 µL filter and preserved at 4°C until the time of use [12].

Chemicals

Lead-acetate ((CH₃COO)₂Pb · 3H₂O) was dissolved in distilled water. Treated rats were received distilled water rich in lead acetate (2 g for each liter), the administrated occur as open dose [9&10].

Experimental design

In this study 20 albino rat were used and distributed for five groups (each group consist four rats) as follow:

1. Group A: control group administrated with normal saline only for seven days, then killed all were euthanized at eighth day.

2. Group B: administrated with lead-acetate for four weeks, then killed.

3. Group C: administrated with lead-acetate for six weeks, then killed.

4. Group D: administrated with lead-acetate for four weeks. After that, treated with 1ml root extract for 15 days, and then killed all were euthanized at sixteenth day after treatment.

5. Group E: administrated with lead-acetate for six weeks. After that, treated with 1ml root extract for 15 days, and then killed all were euthanized at sixteenth day after treatment.

Prepare of blood solution

Subjected rats under anesthesia then later took heart blood and put in test tubes that contain EDTA. This solution was mixed with phosphate buffer, centrifugation 2000 cycle/min for 10 min. Supernatant was taken and 1 ml distal water added for it. Serum concentration of aspartate amino transferase (AST), alanine amino transferase (ALT), alkaline phosphatase (ALP), albumin, bilirubin and creatinine were measured by using of kits of Rondax company, UK in spectrophotometer.

Statistical analysis

Data were analyzed statistically using a statistical Minitab program under SPSS and Microsoft Excel XP system. Means of data were compared using Duncan's Multiple Range test. Probability levels of more than 0.01 were regarded as statistically non-significant, whereas values less than 0.01 were considered as significant as follows: ($P < 0.01$) highly significant *[13].

Results

AST tests

The results of the present study showed significant changes ($P < 0.01$) in level of AST between groups. As shown in figure (1), the groups that administrated lead-acetate for four weeks and for six weeks showed significant increase compared with control group, but in the groups D and E, (groups that administrated with lead-acetate and treated roots extract), showed non-significant changes compared with control group.

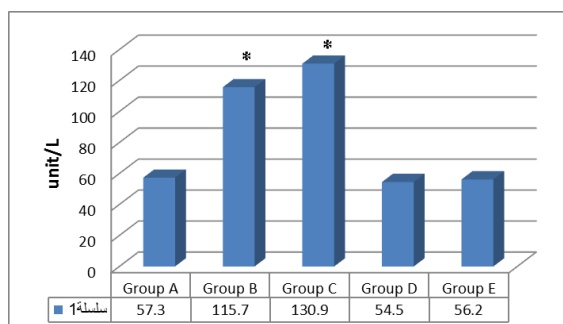


Figure (1): AST Levels

ALT tests

The results of the present study showed significant changes ($P < 0.01$) in level of ALT between groups. As shown in figure (2), the groups that administrated lead-acetate for four weeks and for six weeks showed significant increase compared with control group, but in the groups D and E, (groups that administrated with lead-acetate and treated roots extract), showed non-significant changes compared with control group.

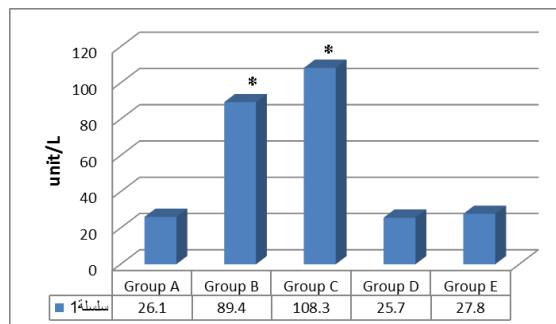


Figure (2): ALT Levels

Alkaline phosphatase tests

The results of the present study showed significant changes ($P < 0.01$) in level of alkaline phosphatase between groups. As shown in figure (3), the groups that administrated lead-acetate for four weeks and for six weeks showed significant increase compared with control group, but in the groups D and E, (groups that administrated with lead-acetate and treated roots extract), showed non-significant changes compared with control group.

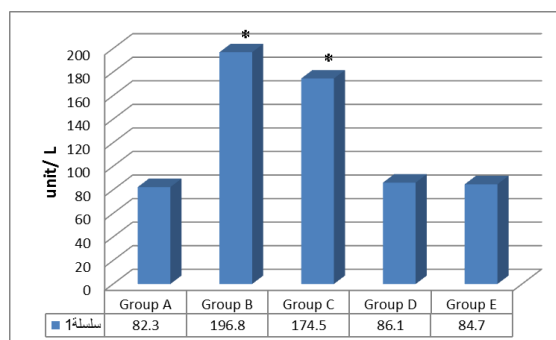


Figure (3): Alkaline phosphatase levels

Bilirubin tests

The results of the present study showed significant changes ($P < 0.01$) in level of bilirubin between groups. As shown in figure (4), the groups that administrated lead-acetate for four weeks and for six weeks showed significant increase compared with control group, but in the groups D and E, (groups that administrated with lead-acetate and treated roots extract), showed non-significant changes compared with control group.

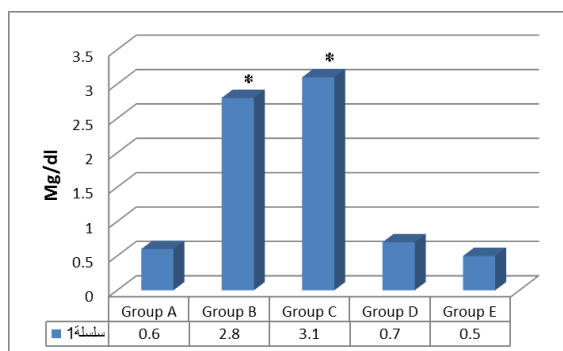


Figure (4): Bilirubin level

Albumin tests

The results of the present study showed significant changes ($P < 0.01$) in level of albumin between groups. As shown in figure (5), the groups that administrated lead-acetate for four weeks and for six weeks showed significant decrease compared with control group, but in the groups D and E, (groups that administrated with lead-acetate and treated roots extract), showed non-significant changes compared with control group.

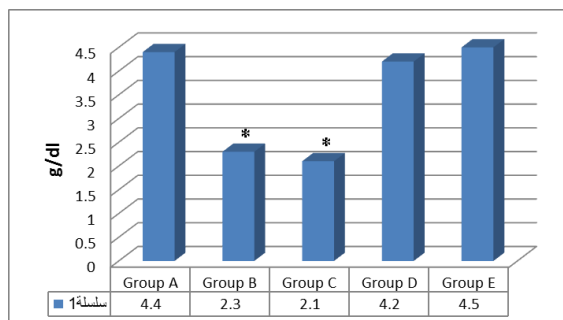


Figure (5): Albumin level

Creatinine tests

The results of the present study showed significant changes ($P < 0.01$) in level of creatinine between groups. As shown in figure (6), the groups that administrated lead-acetate for four weeks and for six weeks showed significant change compared with control group, but in the groups D and E, (groups that administrated with lead-acetate and treated roots extract), showed non-significant changes compared with control group.

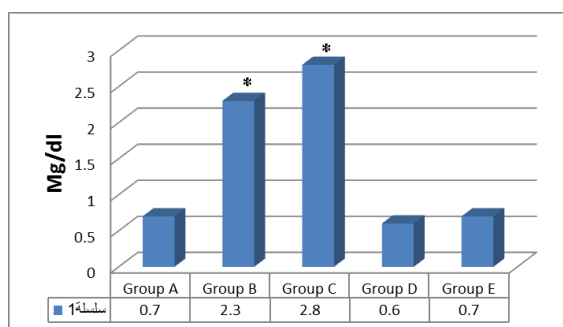


Figure (6): Creatinine level

Discussion

Liver enzymes (AST, ALT, ALP, bilirubin and albumin) are considered as an important biomarker for the detection of lead hepatotoxicity. According to our results, lead caused a significant increase in AST, ALT, ALP and bilirubin levels and decreased in the albumin levels versus the control group. Azoz & Riham (2012) referred that the lead-acetate lead to elevate the levels of serum AST, ALT, ALP and bilirubin in albino rats. On the other hand, Haouas et al (2014) referred that the lead-acetate lead to elevate the levels of serum AST and ALT in albino rats. Ibrahim et al (2012) state that the lead-acetate lead to elevate the levels of serum AST and ALT and decreased in the albumin levels in albino rats, that is in agreement with the results of the present study. Also, in study carried by Saleem et al. (2011) to show the protective effect of Glycyrrhizin on the liver and kidneys functions in mice. They found that the Glycyrrhizin lead to enhancement the levels of AST, ALT, ALP, albumin, bilirubin and creatinine.

Renal creatinine is considered as an important biomarker for the detection of lead renal toxicity. According to the results, lead caused a significant increase in creatinine levels versus the control group. Ashour et al (2007) referred that the lead-acetate lead to elevate the levels of serum creatinine in albino rats, that is in agreement with the results of the present study.

Glycyrrhiza glabra extract has amply good effect on liver and kidneys parameters as many researches were referred. Where, EL-Kenawy & El-Sahra (2009) state that the *Glycyrrhiza glabra* extract has Protective effect on liver enzymes (AST, ALT and ALP) and tissue when its administrated to mice treated with metiram fungicide. Also, Hamza (2007) state that the *Glycyrrhiza glabra* extract lead to recovering the liver tissue and ALT levels back to normal ranges in rats administrated with Diclofenac which lead to Hepatotoxicity. In study carried by Amin & Mohamed (2009) to show the protective effect of *Glycyrrhiza glabra* extract against high fat diet. They found that the high fat diet in rats lead to significant increase in the levels of enzymes AST, ALT and creatinine in the obese compared with normal rats. The finding in different studies, that used different factors to induce lesions in liver and kidneys and treated the animals with *Glycyrrhiza glabra* extract to show the protective effect of this plant, it's the same results of this present study about the protective effect of *Glycyrrhiza glabra* extract.

Reference

1. Asada, Y., Li, W., & Yoshikawa, T. (2000). Biosynthesis of the dimethylallyl moiety of glabrol in *Glycyrrhiza glabra* hairy root cultures via a non-mevalonate pathway. *Phytochemistry*, 55, 323–326.
2. Casulli, F., Ippolito, A. (1995). Observations on liquorice rust (*Uromycesglycyrrhizae*) in southern Italy. *Informatore-Fitopatologico*, 45, 27-30.
3. Olukoga A, Donaldson D. Historical perspectives on health. The history of liquorice: the plant, its extract, cultivation, and commercialisation and etymology. *J R Soc Health* 1998;118:300-304.
4. Lakshmi T. and Geetha R.V. (2011). *Glycyrrhizaglabralinn* commonly known as licorice: a therapeutic review. *J. Pharm. Pharm. Sci.* 3 (4):20-25.
5. Anderson DM, Smith WG. The antitussive activity of glycyrrhetic acid and its derivatives. *J. Pharm. Pharmacol.* Jul 1961;13:396-404
6. 6 Cooper H, Bhattacharya B, Verma V, McCulloch AJ, Smellie WS, Heald AH. Liquorice and soy sauce, a life-saving concoction in a patient with Addison's disease. *Ann ClinBiochem.* Jul 2007;44(4):397-9.
7. Ross EJ. Liquorice and Addison's disease. *Br Med J.* Jun 20 1970;2(5711):733
8. Sharma, V. and R. C. Agrawal. (2013). *Glycyrrhizaglabra*- a plant for the future. *J. Pharm. Med. Scien.* 2(3): 15-20.
9. Hanan, A. A. and Riham, M. R. (2012). Effect of Lead Toxicity on Cytogenicity, Biochemical Constituents and Tissue Residue with Protective Role of Activated Charcoal and Casein in Male Rats. *J. Bas. Appl. Scien.*, 6(7): 497-509.
10. Ibrahim, N. M., Esam A E., Hossam S. and Yasmin E. (2012). Effect of lead acetate toxicity on experimental male albino rat. *J. Trop Biomed*; 2(1): 41-46.
11. Damle, M. (2014). *Glycyrrhizaglabra* (Liquorice) - a potent medicinal herb. *J. Herbal Med.* 2(2): 132-136.
12. Haji Mahdipour H, Amanzadeh Y, Hasanlou T, Shekarchi M, Abedi Z, PiraliHamedani M. (2008). Investigating on the Quality of Wild Licorice Roots Collected from Different Regions of Iran. *J Med Plants*.7: 101-106.
13. Beth, D.; Robert, G. and Trapp. (2004). Basic and clinical biostatistics, 4th ed. Lange Medical Books/McGraw-Hill Medical Publishing Division. New York. PP: 83-154.
14. Azoz, H. A. and Riham, M. R. (2012). Effect of lead toxicity on cytogenicity, biochemical constituents and tissue residue with protective role of activated charcoal and casein in male rats. *J. Bas. App. Scien.*, 6(7): 497-509.
15. Haouas, Z., Sallem A., Zidi I., Hichri H., Mzali I. and Mehdi M. (2014). Hepatotoxic effects of lead acetate in rats: histopathological and cytotoxic studies. *J CytolHistol*, 5 (5): 256-262.
16. Saleem, M. M., Arieg A. W. M., Jazaer A. and Ghassan M. S. (2011). Biological study of the effect of licorice roots extract on serum lipid profile, liver enzymes and kidney function tests in albino mice. *J. Biotech.* 10(59):12702-12706.
17. Ashour, A.A., Maged M. Y., Nahed M. A. and Rokaya M. A. (2007). Blood, serum glucose and renal parameters in lead-loaded albino rats and treatment with some chelating agents and natural oils. *Turk J Biol.* 31 :25-34.
18. EL-Kenawy, S.S., A and El-Sahra, D. (2009). Protective effect of licorice on metiram fungicide induced liver injury in mice. 3 (2): 787-793.
19. Hamza, A. A. (2007). *Curcuma longa*, *Glycyrrhizaglabra* and *Moringaoleifera* Ameliorate Diclofenac-induced Hepatotoxicity in Rats. *J. Pharma. Toxicol.* 2 (2): 80-88.
20. Amin, K. A. and Mohamed A. N. (2009). Effect of Carnitine and herbal mixture extract on obesity induced by high fat diet in rats. *J. Diabetol.&Metab. Synd.* 1 (17): 1-14.

تأثير مستخلص جذور نبات عرق السوس في بعض التأثيرات الفسلجية لذكور الجرذان البيض المعاملة بخلات الرصاص

رشا شامل حسين محمد¹ ، سري سعد عبد العزيز علي²

¹قسم علوم الحياة ، كلية التربية للعلوم الصرفة ، جامعة تكريت ، تكريت ، العراق

²قسم علوم التمريض الاساسية ، كلية التمريض ، جامعة تكريت ، تكريت ، العراق

الملخص

استخدمت الدراسة الحالية 20 من الجرذ الابيض والتوزيع كان عشوائي إلى خمسة مجاميع (كل مجموعة تتكون من 4 جرذان) ، المجموعة الأولى هي مجموعة السيطرة والتي اعطيت الماء والغذاء بشكل اعتيادي ، المجموعة الثانية والتي جرعت بخلات الرصاص لمدة 4 اسابيع، المجموعة الثالثة والتي جرعت بخلات الرصاص لمدة 6 اسابيع ، المجموعة الرابعة والتي جرعت بخلات الرصاص لمدة 4 اسابيع وتم معالجتها بمستخلص الجذور بجرعة (1 مل) لمدة 15 يوم ، المجموعة الخامسة والتي جرعت بخلات الرصاص لمدة 6 اسابيع وتم معالجتها بمستخلص الجذور بجرعة (1 مل) لمدة 15 يوم. اظهرت النتائج ارتفاع فعالية AST ، ALT ، ALP ، البليروبين والكرياتنين وانخفاض مستوى الالبومين وكانت ذات تغييرات عالية المعنوية ($P < 0.01$) في المجاميع المجرعة بجرعة خلات الرصاص مقارنة مع مجموعة السيطرة ولكن عادت مستويات AST ، ALT ، ALP ، البليروبين ، الكرياتنين والالبومين الى المستويات الطبيعية عندما تم معالجة المجاميع المعاملة بخلات الرصاص بمستخلص جذور نبات عرق السوس. يستنتج من هذه الدراسة أن مستخلص جذور نبات عرق السوس له تأثير جيد في معالجة التأثيرات الضارة لخلات الرصاص.