

Histopathological effects resulting from infection stray cats by intestinal parasites in Saladin province

Ashraf Jamal Mahmoud Zangana

Department of Biology , College of Education for Women , Tikrit University , Tikrit , Iraq

Abstract

In this, study 89 stray cats were examined in Saladin province, of both sexes and various ages, which included 82 stray cats and 7 cats as a group control. Showed the infected cats number" of clinical examination and stood infection rate of intestinal parasites 41.46%, was diagnosed with worms *Toxocara cati* by 8.53%, *Toxascaris leonine* by 13.41%, and *Taenia* spp. by 31.70%, and *Dipylidium caninum* by 15.85%, and *Diphyllbothrium* sp. by 7.31% and eggs bags each of *Isoospora* spp. by 20.73%, and *Giardia* spp. 6.09% and *Toxoplasma gondii* by 10.97%. Histopathological examination of the intestines, showed degeneration of columnar epithelial cells and necrosis of some of them and also alienations, the villi in the intestinal cavity, with the presence of large numbers of inflammatory white blood cells within the core of the villi, and the muscular wall of the intestines contained inflammatory cells severe macular disintegration with severe degeneration in many fiber other muscle, as large vacuole appeared in the cytoplasm of the muscle fibers.

Key words: intestinal worms, intestinal protozoan, zoonosis, stray cats.

Introduction

The Cats of widespread animals in human societies, and who live in different environmental conditions, and this is what makes it a direct and indirect contact with human life and other animals. The parasite does not work and cannot complete its life cycle based on potential alone, but succeed if there is its own factors and factors related to the host, as well as environmental factors, which is dominated by the hosts (1). Cats and other felines can act as reservoirs, carriers, transmitters and definitive hosts for many intestinal parasites. These animals play an important role in parasite transmission to human and other animals by shedding parasitic eggs, larvae, cyst or oocyst in there feces (2,3). Furthermore, cats have significant role in contamination of environment with discharge helminthes eggs and protozoan cysts in to the public environments (4,5). *Toxoplasma gondii* and *Toxocara cati* are the most important zoonotic feline gastrointestinal parasites which can be transmitted to human without the involvement of vectors or intermediate hosts. Therefore, humans are directly infected by contact with sporulated oocyst of *T. gondii* and embryonated egg of *Toxocara* spp. (6,7,8). The most common way for human toxoplasmosis is through accidentally ingesting oocyst-contaminated soil shed by infected cats or by ingesting tissue cysts present in undercooked meat (4). According to previous reports, zoonotic nematodes such as *T. cati* and *Ancylostoma tubaeform* are the most common intestinal helminthes parasites of cats worldwide (4). Furthermore other parasitic infections including *Giardia duodenalis*, *Cryptosporidium* spp., *Sarcocystis* spp., *Blastocystis* spp., *Microsporidia* spp., *Echinococcus multilocularis*, *Ancylostoma* spp. And *Strongyloides* spp. have zoonotic potential importance in felines (3,5,9,10).the current study aimed to investigate the prevalence of parasites in stray cats in Salah-aladin province with it s histopathological effects.

Materials and methods

This study was conducted on 82 stray cats of both sexes and different ages for the period from July 2012 - July 2013 and 7 clinically were healthy cats " considered as control group, which were recorded clinical signs observed on infected cats.

Fishing cats mediated gunshot which anatomy field, and isolated from small and large intestine and examined its contents, then the worms from infected animals were collected and washed with a solution of physiological salt (PH = 7) and kept in small bottles contain NaCl 0.85 % solution and placed in the refrigerator degree 4C until its need, after a diagnosis of worms by phenotypic traits depending on (11,12). Eggs and cysts with some internal parasites forms were isolated for each stray cat feces by flotation method (13), followed the method (14) in a stain of worms and diagnosed according to the specifications and measurements mentioned in the (12,14,15).

Selected histopathological section from the affected organs included parts of the lesion area with proper part was the section length and width of about 1 cm. The fixation samples was by formalin [10%] and chipping histologically by (13), and followed the method (14).

Statistical analysis was performed by T-test in the significance level of $P > 0.05$ (16).

Results:

Clinical examination of infected cats showed presence of clinical signs represented the loss of appetite with wasting and diarrhea. The samples of the intestines of stray cats contents showed the rate of infection with worms and pMsrotozoan intestinal accounted for 41.46% (Table 1).

Table (1): the ratio of infection by diagnosed intestinal parasites in stray cats in Salahaldin province

Cats groups	Number of Sample examined	Number of sample infected	Percentage %
Stray cats	82	34	41.46
Control group	7	0	0
total	89		

An examination of the stray cats feces samples and intestinal contents that the percentage of infection worms of *Taenia* sp. The highest rate reached 31.70%, followed by infection with all of the *T. cati* and *Toxascaris leonine* and *Dipylidium caninum* and *Diphyllobothrium* sp. cysts of *Giardia* spp. and *Isospora* spp. and *Toxoplasma gondii*, by 15.85% ,13.41% , 8.53% , 7.31% , 20.73% , 10.97% , 6.09% respectively (Table 2).

Table (2) : types of worms and internal parasites cysts diagnosed in stray cats in Salahaldin province

types	Number of samples examined	Percentage %
<i>Toxocara cati</i>	7	8.53
<i>Toxascaris leonine</i>	11	13.41
<i>Taenia</i> spp.	26	31.70
<i>Dipylidium caninum</i>	13	15.85
<i>Diphyllobothrium</i> sp.	6	7.31
<i>Giardia</i> spp.	5	6.09
<i>Isospora</i> spp.	17	20.73
<i>Toxoplasma gondii</i>	9	10.97

Table (3) shows The common pattern of infection by more than two different worms and internal parasites cysts in stray cats had appeared where the highest proportion reached 67.64% .

Table (3): pattern of infection in various internal parasitic infections diagnosed in stray cats in Salahaldin province .

Infection pattern	Number of infected samples	Percentage %
Co-infection with more than two	23*	67.64
Double infection	7	20.58
Single infection	4	11.76
total	34	99.98

the histopathological effects has appeared on the intestinal villi that many columnar epithelial cells were degenerated and Necrosis of some of them and also intestinal glands generally where in many areas appeared free of the natural structure of the cells (figure 1) with the presence of large numbers of white blood cells inflammatory within the core of the villi and the epithelial cells lining the villi were present in the intestinal lumen as shedded in large cells of intestinal glands in the cavities that the villi were surrounded by infiltration of the numbers of lymphocytes, also featured the blood vessels free of blood (figure 2) and the basis of the villi and the rest of the core plate infiltrated with inflammatory cells and lymphocytes (figure3). Submucosal layer

infiltrated of some inflammatory cells and muscular wall of the intestine were atrophied and disintegration of smooth muscle fiber with severe degeneration in many muscle fibers as other featured large gaps in the cytoplasm of muscle fiber also (figure 4,3).

Discussion: infected stray cats showed a number of clinical signs include diarrhea, loss of appetite and wasting, and due to the diagnosis of infection with all of *Toxocara cati* and *Toxascaris leonine* cysts parasite of *Toxoplasma gondii* and *Isospora* spp. and *Giardia* spp. . The infection rate appeared in various internal parasites high in stray cats, which may be the reason for stray cats spread in different regions and lack of attention with unhealthy culture conditions, which increases the chances of exposure to the various parasitic infections and other diseases.

The prevalence of gastrointestinal parasites in cats vary and it may be due to geographical region (temperature and humidity), season, behaviors and habits of the local animal populations and the type of population of cat (stray, feral, shelter, household) (17). Other investigations on the prevalence of intestinal parasites in cats of Ebro Valley, Spain and Rio de janeiro indicated that 90% of cats from both areas were infected with parasites (18,19). In the present study, the most frequent species of parasites was *Taenia* spp. 31.70% which was similar to the prevalence of *T. cati* infection in stray cats recorded in other regent in Iraq . Zibaei *et al.*, reported that 42.6% of stray cats in shiraz were infected with *T. cati* (20) . but 28.8% , 13.3% and 8% of stray cats in Mashhad, Kashan and Zanzan were infected had toxocariasis, respectively (21,22). In this present research was lower than those of Iran and Ehypt 6.09% (23,17). And in cats in Italy with IFA and polymerase chain reaction (PCR) techniques and findings 4.4% of cats were infected with *G. duodenalis* (24). Our suggestion that control programs including education for people about zoonotic parasites , preventing free entrance of stray cats and dogs in public places and collection and hygienic disposal of stray cats and dogs feces by municipal workers every day should be developed by mass media, health service centers and veterinarians.

The emergence of degeneration markers in columnar epithelial cells in the intestine has detected, and the presence of inflammatory white blood cells within the core of the villi, as well as the presence of lymphocytes in the basic plate is an indication of a parasitic infection, it was stated by (25) and (12) that worms causes the hosts inflammatory bowel up to the outer layer, and was characterized by the appearance of inflammatory cells chronic (lymphocytes, plasma cells, macrophages) in different proportions in the intestinal layers, and that is incidence of degeneration, due to the presence of the parasite which were fragmented cells showed corroded any had lost of its original features (26) that the infiltration of inflammatory cells defense is a defense of the body against foreign objects.

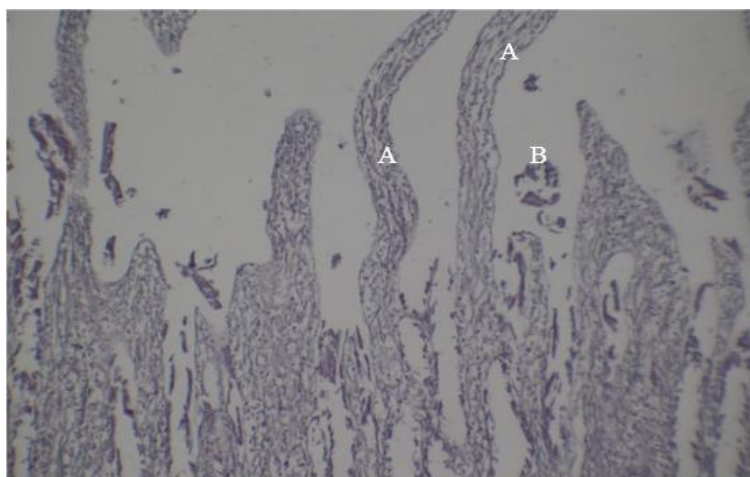


Figure 1: Section in small intestine showed: A: Necrosis of intestinal villi and epithelial cells were degenerated or sloughed B: alienation intestinal villi in intestine cavity (100X ;H&E).

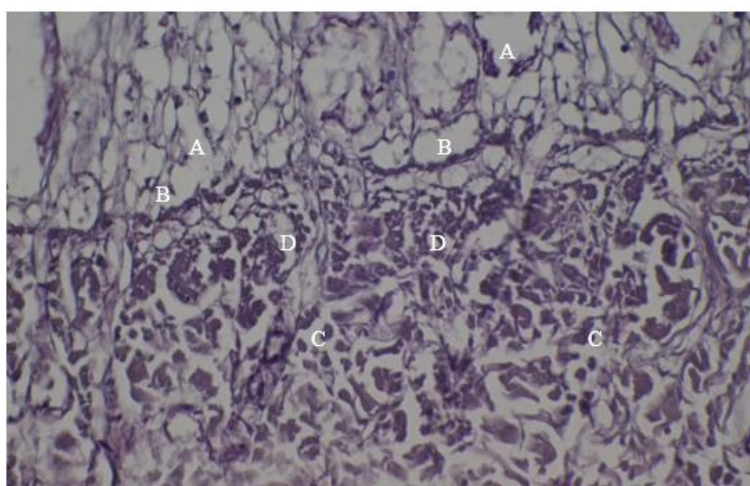


Figure 2: Section in small intestine showed: A:Necrosis in cells of intestine gland B: lymphocytes infiltration around the intestinal glands C:atrophy of smooth muscle fiber D: Degeneration of smooth muscle fiber (200X ; H&E).

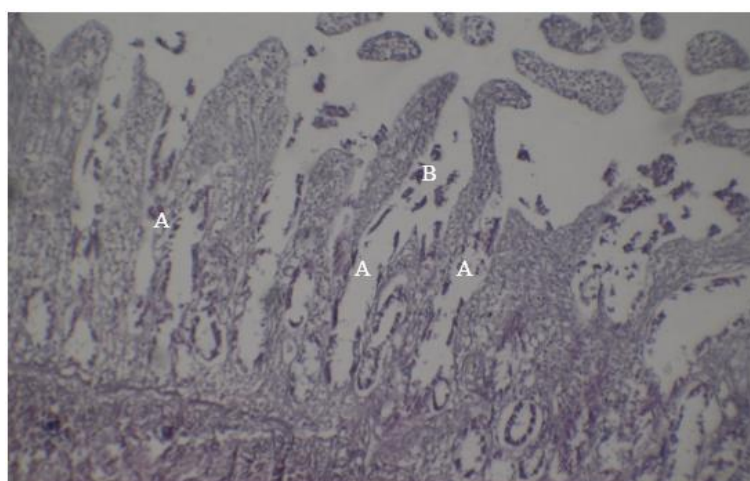


Figure 3: Section in small intestine showed:A: disintegration and Necrosis of villi with degenerated of its epithelial cells B: alienation of epithelial cells (100X;H&E).

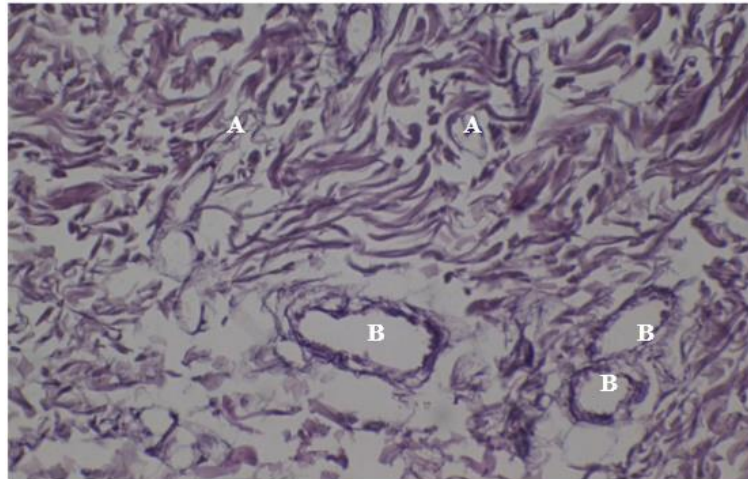


Figure 4: Section in intestine showed: A: degenerated atrophy of smooth muscle fibers B: blood vessels free of blood (200X ;H&E)

References:

- 1- Vashetko, E. V. and Siddikov, B. H. (1999). The effect of the ecology of toads on the distribution of helminthes . Turkey, J. Zool., 23: 107 – 110 .
- 2-Alves, J.M.; Magalhaes, V.; Matos, M.A.(2010). Toxoplasmic retinochoroiditis in patients with AIDS and neurotoxoplasmosis . Arq Bras Oftalmol., 73(2): 150-154.
- 3-Mircean, V.; Titilincu, A.; Vasile, C. (2010). Prevalence of endoparasites in household cats (felis catus) populations from Transylvania (Romania) and association with risk factors. Vet. Parasitol. 171(1-2): m163-169.
- 4-Sowemimo, O.A. (2012) . Prevalence and intensity of gastrointestinal parasites of domestic cats in Ode-Irele and Oyo communities, Southwest Nigeria. J. Parasitol. Vector. Biol. , 4(1): 7-13.
- 5-Jamshidi, S.; Tabrizi, A.S.; Bahrami, M.; Momtaz, A. (2012). Microsporidia in household dogs and cats in Iran; azoonotic concern.185(2-4): 121-124.
- 6-Durate, A.; Gastro, I.; Pereira, D.; Faonseca, I.M.; Almeida, V.; Madeira, D.; Carvalho, L. M.:(2010). Survey of infections and parasitic diseases I stray cats at the Lisbon metropolitan area, portugal. J. feline med. Surg., 12(6): 441-447.
- 7-Dabritz, H. A.& Conrad, P. A. (2010) . cats and toxoplasma : implications for public health. Zoonoses public health. 57(1): 34-52.
- 8-Kulasena, V.A.; Rajapakse, R.P.; Dubey, J.N.; Premawansa, S. (2011). Seroprevalence of Toxoplasma gondii in cats from Colombo , Sri Lanka. J. Parasitol. , 97(1): 152.
- 9-Awadallah, M.A. (2010). Endoparasites of zoonotic importance. Msc. Thesis, Coll. Vet. Med. Univ. Tikrit.
- 10-Vassalos, C.M.; Papadopoulou, C.; Vakalis, N.C.(2008). Blastocystosis: an emerging or re-emerging potential zoonosis? Vet. Ital., 44(4): 679-684.
- 11- Yamaguti, S. (1961). Systema Helminthum. Ist ed ., chancery lane , London : 679 pp .
- 12-Soulsby, E.J.L. (1982). Helminths Arthropods and Protozoa of domesticated animals. 7th ed. London, Bailliere, Tindall. 155-464.
- 13- Bancroft, J. D. & Stevens, A. (1982). Theory and practice of Histological Techniques. zed. Churchill Livingstone, Inc., New York, pp: 662.
- 14- Humason, G. L.(1967). Animal tissue techniques. Zed. W. H Freeman comp. Sanfrancesco. pp : 427 .
- 15-Petrie,A. & Watson, P. (1999). Statistics for veterinary and animal science. Black well . 79-113.
- 16-Grimason, M.H.V.; F.W.; Parker, M.H.; Jackson, P.G.; Smith, P.G. & Girdwood, R.W.A. (1993). Occurrence of *Giardia* spp. Cysts and *Cryptosporidium* spp. Oocysts in faeces from public parks in the west of Scotland. Epidemiol Infect. 110: 641-645.
- 17-Kalafalla, R.E. (2011). Asurvey study on gastrointestinal parasites of cats in northern region of Nile delta, Egypt. plos one. 6(7).
- 18-Labarthe, N.; Serrao, M. L.; Ferreira, A.M.; Almeida, N.K.; Guerrero, J. (2004). Asurvey of gastrointestinal helminthes in cats of the metropolitan region of Rio de janeiro, brazil, vet. Parasitol. 123(1-2):133-139.
- 19- Serra, C.M.; Uchoa, C.M.; Coimbra, R.A. [Parsitological study with faecal samples of stray and domiciliated cats (felis catus domesticus) from the metropolitan area of rio de janeiro, Brazil]. Rev. Soc. Bras. Med. Trop.,36(3): 331-334.
- 20-Zibaei, M.; Sadjjadi, S.M.;Sarkari, B.(2007). Prevalence of Toxocara cati and other intestinal helminthes in stray cats in Shiraz, Iran. Trop. Biomed. , 24(2): 39-43.
- 21-Mohsen, A.; Hossein, H. (2009). Gastrointestinal parasites of stray cats in Kashan, Iran. Trop. Biomed., 26(1): 16-22.
- 22-Esmaeilzadeh, M.; Shamsfard, M.; Kazemi, A.; Khalafi, S.A.; Altome, S. A. (2009). Prevalence of protozoa and gastrointestinal helminthes in stray cats

in Zanjan province, north –west of Iran. Iranian j. parasitol., 4(3):71-76.
23-Shahram, K.; Rahman, A.; Fakher, R.; Mahamoud, H.; Mohammad, G.; Mahdi, T. (2014). Stray cats gastrointestinal parasites and its association with public health in ahvaz city, south western of Iran. Jundishapur j. microbial., 7(8):79.
24-Paoletti, B.; Otranto, D.; Weij, S.; Giangaspero, A.; Di cesar, A.; Traversa, D. (2011). Prevalence and genetic characterization of Giardia and

Cryptosporidium in cats from Italy. Res. Vet. Sci., 91(3):397-399.
25- Mustafa, F. A. (1999). Pathological effects of *Paradilepis delachauxi* (Fuhrman, 1909) (Cestode: Dilepididae) in alimantry canal of the *Phalacrocorax pygmaeus* in Basrah , Iraq . J. Basrah Researches, 20 (part 1) : 23-26.
26-Yacob , H. T.; Avele, T.; Fikru , R. & Basu , A. K. (2007). Gastrointestinal nematodes in digs from deber zeit, Ethiopia. Vet. Parasitol., 148(2): 144-148.

التأثيرات النسجية المرضية الناتجة من خمج القطط السائبة بالطفيليات المعوية في محافظة صلاح الدين

أشرف جمال محمود زنكنة

قسم علوم الحياة ، كلية التربية للبنات ، جامعة تكريت ، تكريت ، العراق

الملخص

شملت الدراسة فحص 89 قطة "سائبة" في محافظة صلاح الدين، من كلا الجنسين وبأعمار مختلفة ، تضمنت 82 قطة "سائبة" و 7 قطط سليمة سريريا" اعتبرت كمجموعة سيطرة. اظهر الفحص السريري للقطط المصابة عدداً من العلامات السريرية وبلغت نسبة الخمج بالطفيليات المعوية 41.46 % ، تم تشخيص الديدان *Toxocara cati* بنسبة 8.53 % ، *Toxascaris leonine* بنسبة 13.41 %، و *Taenia* spp. بنسبة 31.70 %، و *Dipylidium caninum* بنسبة 15.85 % ، و *Diphyllobothrium* sp. بنسبة 7.31 % وأكياس بيض كل من *Isospora* spp. بنسبة 20.73 %، و *Giardia* spp. بنسبة 6.09 % و *Toxoplasma gondii* بنسبة 10.97 % . وظهر الفحص النسيجي للأمعاء تنكس الخلايا الظهارية العمودية وبعضها ظهر عليها التخر وأيضاً انسلاخ الزغابات داخل تجويف الأمعاء، مع وجود أعداد هائلة من كريات الدم البيضاء الالتهاابية داخل لب الزغابات، والجدار العضلي للأمعاء احتوى على ألياف عضلية لمساء شديدة الضمور والتفكك مع تنكس شديد في العديد من الألياف العضلية الأخرى، كما وظهرت كتيرة في سايبتوبلازم الألياف العضلية.

الكلمات الدالة: الديدان المعوية، الاوالي المعوية، الامراض المشتركة، القطط السائبة.