



Detection of infection with hydatid cysts in abattoirs animals at Kirkuk governorate, Iraq

Raid Sabah Radhwan , Fatima Shihab Al-Nasiri

Department of Biology, College of Science, University of Tikrit, Tikrit, Iraq

DOI: <http://dx.doi.org/10.25130/tjps.26.2021.060>

ARTICLE INFO.

Article history:

-Received: 13 / 6 / 2021

-Accepted: 29 / 6 / 2021

-Available online: / / 2021

Keywords: hydatid cysts, abattoir animals, Iraq.

Corresponding Author:

Name: Raid Sabah Radhwan

E-mail:

raidsabahradhwan@gmail.com

Tel:

ABSTRACT

During the period from September 2020 to February 2021, the current study was conducted to determine the total prevalence of infection with hydatid cysts disease in the various organs (especially liver, lung, spleen, kidney, heart, and mesentery) of abattoirs animals (sheep, cattle, goats and buffaloes) in Kirkuk governorate and its suburbs. Visual examination and hand-feeling were used to detect and identify the site of infection with hydatid cysts, as well as a microscopic examination was used to determine the fertility of hydatid cysts.

A total of 4122 abattoirs animals were examined, including: 1860 sheep, 1550 cattle, 680 goats and 32 buffaloes. The hydatid cysts was found in 133 animal samples (42 sheep, 83 cattle, 6 goats and 2 buffaloes), the total prevalence of infection was 2.25%, 5.35%, 0.88%, 6.25% in sheep, cattle, goats and buffaloes, respectively. The prevalence of infection in females of abattoirs animals was more than in males, which was 0.48%, 1.77% in sheep; 1.48%, 3.87% in cattle; 0.29%, 0.58% in goats, for male and female respectively. While, the prevalence of infection was 6.25% in females of buffaloes compared with their males which didn't infected.

The results showed that the liver is the most organ of the animal's body to be infected with hydatid cyst, the prevalence of infection in the liver of males and females was 63.63%, 44.44% in sheep, 46.66%, 65.21% in cattle, 50.00%, 50.00% in goats and 0.00%, 50.00% in buffaloes, respectively.

The infection with fertile hydatid cysts in sheep, especially in livers of females (80.95%) is higher compared with other infections of abattoirs animals, while it was noticed that the highest prevalence of sterile hydatid cysts in the lungs of females cattle (93.33%). In addition, the most cases of calcified hydatid cysts were observed in the lungs of females sheep (50.00%) and livers of females cattle (32.14%).

Introduction

Hydatid cystic disease (hydatidosis) is one of the most important zoonotic disease, it caused by the larval stage of tapeworm *Echinococcus granulosus*. The cystic larval stage of *E. granulosus* is found in intermediate hosts (sheep, cattle, goats, etc.) as a result of ingestion of the parasite eggs which shed in the feces of definitive hosts (dogs, wolf, jackal, etc.), and the definitive host is infected by ingesting intermediate hosts harboring *E. granulosus* metacestodes (hydatid cysts) [1]. The growth of hydatid cyst is slow, its growth rate depends on several factors, including the type and strain of the parasite and host [2], as well as the effects of other

factors such as age, sex and immune status of the host [3]. The hydatid cyst need to fully grow from six months to several years, it was either fertile cysts contain protoscoleces and brood capsules, or sterile cysts without protoscoleces [4]. Hydatid cysts disease is considered one of the ancient and common parasitic diseases, it was spreading in all countries of the world, and it is more prevalent in temperate regions such as South America, the Mediterranean countries of the Eastern Europe, North Africa, and Central Asian countries [5]. It is a major public health and economic problems in developing countries including Iraq, especially in rural areas [6, 7].

Hydatidosis are association with economic losses in livestock production include direct costs due to condemnation of infected viscera, and indirect costs due to decreased productivity of infected animals [8]. It infect any part of herbivores intermediate host and human except hairs and nails [9].

This study aimed to determine the percentage of infection with hydatid cysts in different random samples of abattoirs animals (sheep, cattle, goats and buffalo) in the city of Kirkuk, and its suburbs. As well as identifying the structurally different types of hydatid cysts formed in these different animals.

Materials and Methods

The present study was conducted from September 2020 to February 2021, in Kirkuk governorate. A total of 4122 abattoirs animals (1860 sheep, 1550 cattle, 680 goats and 32 buffalo) were examined to detect the infection with hydatid cysts in visceral organs (liver and lung).

Post-mortem examination were carried out to identified the infection with hydatid cysts in different organs (liver and lung) of each studied animals. Sex of each animal was recorded.

Post-mortem examination of different organs were carried out for each slaughtered animals, especially liver, lung, spleen, kidney, heart, and mesentery. Macroscopic examination of each organ was done by visual inspection or by palpation, and where-necessary some incision were made to identified and

discover a small hydatid cysts. Each hydatid cysts were removed carefully and separated from its organ. Each sample of hydatid cysts was collected separately in containers to examined it, [10, 11] for additional cystic characteristics (as fertility and structural types). For positive animals, the infected organs were collected and the total number of cysts were counted per each infected organs.

The hydatid cysts were classified either fertile or sterile (infertile) according to presence or absent the protoscolecies, respectively. Also, hydatid cysts were further divided as hyaline, fibrous and calcified after it's incision and examined it microscopically [11].

Results

In the current study, a total of 133 animals out of 4122 animals were infected with hydatid cyst in some of slaughters of Kirkuk governorate and these infections were distributed as follows: 42 in sheep, 83 cattle, 6 goats and 2 buffaloes.

In the present study (Table 1), the total prevalence of infection with hydatid cysts was 2.25%, 5.35%, 0.88%, 6.25% in sheep, cattle, goats and buffaloes, respectively. The prevalence of infection with hydatid cysts in females was higher than rate in males. The prevalence of infection for male and female were 0.48%, 1.77% in sheep, 1.48%, 3.87% in cattle, 0.29%, 0.58% in goats and 0.00%, 6.25% in buffalo, respectively.

Table 1: The prevalence of infection with hydatid cysts in male and female of abattoirs animals.

Animals	No. of examined animals	Male		Female		Total	
		No. of infected animals	Prevalence %	No. of infected animals	Prevalence %	No. of infected animals	Prevalence %
Sheep	1860	9	0.48	33	1.77	42	2.25
Cattle	1550	23	1.48	60	3.87	83	5.35
Goats	680	2	0.29	4	0.58	6	0.88
Buffalo	32	0	0.00	2	6.25	2	6.25

Table (2) showed that the prevalence of hepatic infections was higher than the prevalence of pulmonary infections. The most infected organs in abattoirs animals were the liver. The highest percentage of infection with hydatid cysts in the livers was in cattle males (65.21%), followed by sheep females (63.63%). While the highest

prevalence of pulmonary infections was found in males and females of cattle (26.08%, 25.00%, respectively), and the highest prevalence of infection with hydatid cysts was found in multiple sites of infection (liver and lung together), it was found in males of sheep (55.56%).

Table 2: The prevalence of infection with hydatid cysts in abattoirs animals according to the site of infection.

Animals		Sheep (1860)		Cattle (1550)		Goats (680)		Buffalo (32)	
		Male (1174)	Female (686)	Male (1065)	Female (485)	Male (393)	Female (287)	Male (19)	Female (13)
Hepatic infections	No. of infected animals	4	21	15	28	1	2	0	1
	Prevalence %	44.44	63.63	65.21	46.66	50.00	50.00	0.00	50.00
Pulmonary infections	No. of infected animals	0	2	6	15	0	1	0	0
	Prevalence %	0.00	6.06	26.08	25.00	0.00	25.00	0.00	0.00
Hepatic and Pulmonary infections	No. of infected animals	5	10	2	17	1	1	0	1
	Prevalence %	55.56	30.30	8.69	28.33	50.00	25.00	0.00	50.00

The results of current study (Table 3) showed that the highest prevalence of liver infection with fertile hydatid cysts was 80.95% in female sheep, while for lung infections with fertile cysts reached to 50.00% in sheep females. For the highest percentage of fertile cysts in the multiple site of infection (liver and lung together), it was recorded at 100% in females for each of goats and buffaloes, followed by hepatic infection of sheep (80.95%). As for sterile hydatid cysts, it was recorded at 100% in the livers of both males and females goats and buffaloes. While the highest percentage of lung infections was recorded with sterile hydatid cysts in the lungs of female cattle (93.33%).

The current results (Table 4) showed that the hydatid cysts infect sheep, cattle, goats, buffaloes, with hydatid cysts which classified as hyaline, fibrous and calcified according to its structure. The prevalence 100% was recorded for hyaline cyst in goats, buffaloes, male of sheep, multiple-site infection of cattle and lung infections of cattle females. While the fibrous cysts were found in multi-site infection at female sheep (20.00%), followed by 16.66% in lungs of males cattle. The highest prevalence of infection with calcified hydatid cysts were found in the lungs of females sheep (50.00%), followed by 32.14% in livers of females cattle.

Table 3: The prevalence of infection with hydatid cysts in abattoirs animals according to the fertility.

Location of infection (No. of infected animals)			Fertile cysts		Sterile cysts	
			No. of infection	Prevalence %	No. of infection	Prevalence %
Sheep (42)	Male (9)	Hepatic (4)	3	75.00	1	25.00
		Pulmonary (0)	0	0.00	0	0.00
		Hepatic and Pulmonary (5)	3	60.00	2	40.00
	Female (33)	Hepatic (21)	17	80.95	1	4.76
		Pulmonary (2)	1	50.00	1	50.00
Cattle (83)	Male (23)	Hepatic (5)	0	0.00	11	73.33
		Pulmonary (6)	1	16.16	4	66.66
		Hepatic and Pulmonary (2)	1	50.00	1	50.00
	Female (60)	Hepatic (28)	6	21.42	10	35.71
		Pulmonary (15)	1	6.66	14	93.33
Goats (6)	Male (2)	Hepatic (1)	0	0.00	1	100
		Pulmonary (0)	0	0.00	0	0.00
		Hepatic and Pulmonary (1)	0	0.00	1	100
	Female (4)	Hepatic (2)	0	0.00	2	100
		Pulmonary (1)	0	0.00	1	100
Buffalo (2)	Male (0)	Hepatic (0)	0	0.00	0	0.00
		Pulmonary (0)	0	0.00	0	0.00
		Hepatic and Pulmonary (0)	0	0.00	0	0.00
	Female (2)	Hepatic (1)	0	0.00	1	100
		Pulmonary (0)	0	0.00	0	0.00
		Hepatic and Pulmonary (1)	1	100	0	0.00

Table 4: The prevalence of infection in abattoirs animals according to types of hydatid cysts.

Location of infection (No. of infected animals)			Hyaline cysts		Fibrous cysts		Calcified cysts	
			No. of infection	Prevalence %	No. of infection	Prevalence %	No. of infection	Prevalence %
Sheep (42)	Male (9)	Hepatic (4)	4	100	0	0.00	0	0.00
		Pulmonary (0)	0	0.00	0	0.00	0	0.00
		Hepatic and Pulmonary (5)	5	100	0	0.00	0	0.00
	Female (33)	Hepatic (21)	18	85.71	2	9.52	1	4.76
		Pulmonary (2)	1	50.00	0	0.00	1	50.00
		Hepatic and Pulmonary (10)	8	80.00	2	20.00	0	0.00
Cattle (83)	Male (23)	Hepatic (5)	11	73.33	2	13.33	2	13.33
		Pulmonary (6)	5	83.33	1	16.66	0	0.00
		Hepatic and Pulmonary (2)	2	100	0	0.00	0	0.00
	Female (60)	Hepatic (28)	16	57.14	3	10.71	9	32.14
		Pulmonary (15)	15	100	0	0.00	0	0.00
		Hepatic and Pulmonary (17)	17	100	0	0.00	0	0.00
Goats (6)	Male (2)	Hepatic (1)	1	100	0	0.00	0	0.00
		Pulmonary (0)	0	0.00	0	0.00	0	0.00
		Hepatic and Pulmonary (1)	1	100	0	0.00	0	0.00
	Female (4)	Hepatic (2)	2	100	0	0.00	0	0.00
		Pulmonary (1)	1	100	0	0.00	0	0.00
		Hepatic and Pulmonary (1)	1	100	0	0.00	0	0.00
Buffalo (2)	Male (0)	Hepatic (0)	0	0.00	0	0.00	0	0.00
		Pulmonary (0)	0	0.00	0	0.00	0	0.00
		Hepatic and Pulmonary (0)	0	0.00	0	0.00	0	0.00
	Female (2)	Hepatic (1)	1	100	0	0.00	0	0.00
		Pulmonary (0)	0	0.00	0	0.00	0	0.00
		Hepatic and Pulmonary (1)	1	100	0	0.00	0	0.00

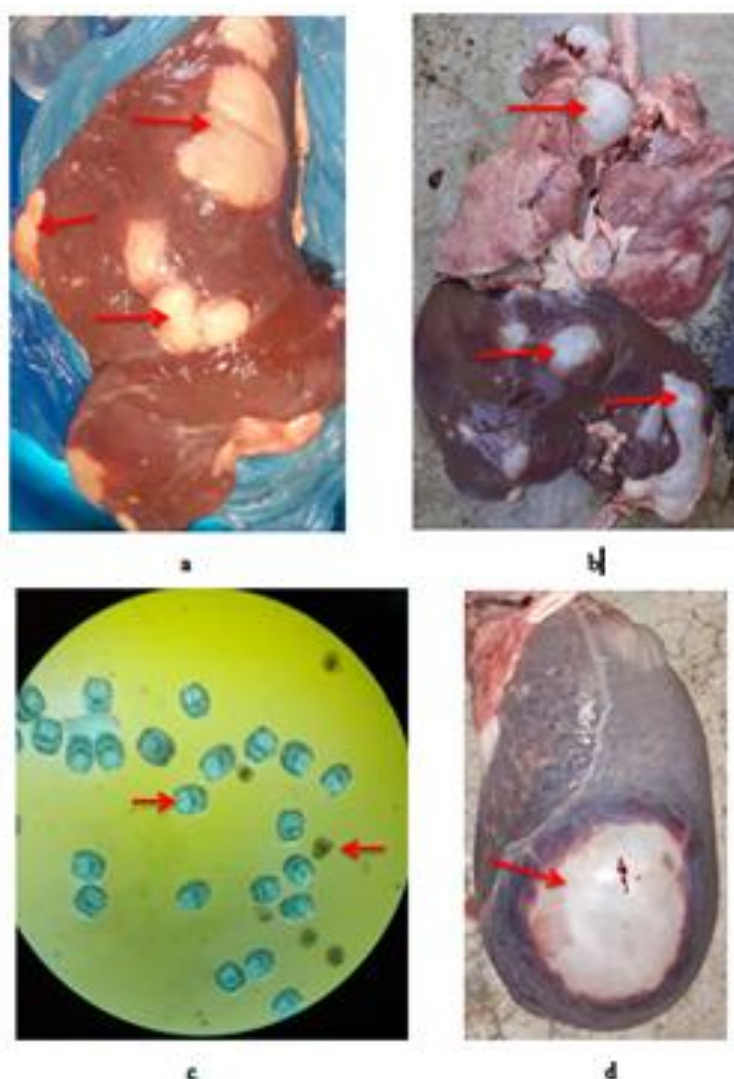


Fig. 1: a- Liver of cattle infected with calcified cysts.

b- Liver and lung of sheep infected with hyaline cysts.

c- Live (green) and dead (red) protoscoleces from sheep's origin.

d- Spleen of sheep infected with hydatid cyst.

Discussion

Hydatid cysts were collected from different hosts (sheep, cattle, goats, buffalo), and from different organs (livers, lungs and spleen) which naturally infected with hydatid cysts in Kirkuk governorate.

The prevalence of infection with hydatid cysts is highly associated with the method of slaughter the animals, common customs and harmful practices in rural areas, such as feeding the dog onto the animal residues which infected with hydatid cysts or throwing dead animals onto the roadside, which makes it easier to be eaten by dogs, as well as the production of *Echinococcus* worm for large numbers of eggs [12]. In regard of having almost no knowledge about the mode of transmission of hydatidosis, the majority of villagers give raw visceral organs to dogs, these organs may carry infective stage of parasite [20].

In the present study, three types of hydatid cysts were found, which included hyaline, fibrous and calcified

cysts. Generally, the hydatid cysts take different shapes depending on the parasite's strain, host type and parasitism site [13]. The results of the current study came according to mentioned about the occurrence of hydatid cysts in different shapes and types. Moreover, it was noticed that the hydatid cysts were found in the lumen and the mesentery of the intestine were thin-walled and transparent, as a results to decrease the immune responses in this sites, it is indistinguishable the inner layer of the cysts wall [11,14].

In the present study, different prevalence of infection with hydatid cysts were recorded in males and females of the abattoirs animals. The prevalence of hydatid cysts were increased in female animals compared with their males. This is due to several reasons, as males animals are usually slaughtered at young ages, and the advanced age of animal provides more opportunity for infection compared with younger animals, as well as animal age-rated

immunity, and the hydatid cysts needs a long time to grow and develop [15]. The reason for the high rate of infection in females at a higher rate than males can also be attributed to the role of sex hormones to occurrence of this disease, as these hormones affect to the work of Cytokines secreted by T-cells, which are the main axis to regulation of the body immune [16]. Several studies confirmed that female's sheep more affected than its males [17, 18], while other studies [19, 20] indicated that males of sheep had a higher prevalence of infection compared with its females.

As for cattle infections, the current study agrees with many studies [18, 20, 21] revealed that the prevalence infection of females cattle was higher than the males. While some studies [19, 22] indicated that the prevalence infection of male cattle was higher than its females. The current study agrees with some studies [19, 23] which indicated that the prevalence infection in female of goats was higher than its males, while the current study does not agree with other studies [17, 18] which showed that the prevalence infection in males of goats is higher than its females. The current study agrees with [24] which indicate that the prevalence infection in female of buffaloes is higher than the prevalence infection in their males.

The present study, indicated that the liver and lung of abattoirs animals are most organs of the host animal's body harboring the infection with hydatid cysts. The liver has the highest prevalence of lung infections in all abattoir animals (sheep, cattle, goats and buffalo), and this is agreement with most studies of hydatid cysts [25]. The liver in sheep, cattle, goats and buffalo is most commonly infecting with hydatid cysts, because the bile duct in liver receives the blood with oncospheres after the blood has passed the duodenum. The oncosphere penetrating the intestinal mucosa to reach the portal vein and it is carried by blood to all parts of body, due to the size of oncosphere, most of them become settled in the liver of intermediate host. Therefore, the liver acts as the first site for hydatid cyst infection in body of intermediate host. While, some studies mentioned that lungs of intermediate host are considered as predominant site for hydatid cyst infection. That is attributed to the large lymphatic vessels, which provide a chance for the oncosphere to arrive lymphatic lacteal, after that transport through the lymph to the lungs before being translocated in venules to reach the liver [19, 20, 26]. In addition, the lungs are considered the second barrier to the blood stream that contains oncospheres embryos [27].

The present study agrees with many studies [28, 29, 30] that the prevalence infections in sheep's livers is higher than its lungs. While other studies [17, 29, 32] were indicated that the prevalence of infection in sheep's lungs is higher than its livers.

In the cattle, some studies have confirmed that the prevalence of infection in livers of cattle is higher than its lungs [31, 32]. While some other studies [17, 29, 32] indicated that the prevalence of infection in

cattle's lungs is higher than its livers. As for the infection of goats, some studies [19, 29, 30] indicated that the prevalence of livers infection was higher than the prevalence of infection in lungs. While two other studies [17, 32] mentioned that the prevalence of infection in the lungs of goats is higher than the prevalent of infection in their livers. The current study agrees with [34] which mentioned that prevalence of infection in the buffalo liver is higher than prevalence of infection in its lungs. While [24] mentioned that the prevalence of buffalo lungs is higher than their livers.

The present study, confirmed that there are differences in the prevalence of fertile cysts in abattoirs animals according to type of host animal, gender (male and female) and the site of parasitism. The reason for the difference in fertility of hydatid cysts may be due to the different strains of the *E. granulosus* parasite in different hosts that may be appropriate or inappropriate for the growth and development of the hydatid cysts, or as a result of different grazing areas, food type, climatic conditions, host strain, age and immune status [20, 35]. The hydatid cysts may be fail to form the protoscoleces and brood capsules due to calcification, or infection with bacteria, or due to unknown reasons [36]. This fact indicates the high degree of the specificity of the echinococcosis parasite (with its different strains) to the hosts, as the hydatid cysts of sheep's origin are characterized by their high fertility compared to the hydatid cysts of cattle or goat's origin, due to that adaptation can occur in the parasite, and the accompaniment of sheep-dogs in rural and grazing areas [34]. The prevalence of fertility changes according to the age and location of cyst [37].

The calcified cysts are formed as a result of the formation of the thick walls surrounding the hydatid cysts due to the inflammation resulting from the immune rejection of host, this leads to calcified material impedes the entry of food and the excretion of rubbish [38].

In general, the current study showed that the prevalence of fertile cysts in sheep is higher than the prevalence of sterile cysts, this was confirmed by most studies [19, 20]. As for cattle, the current study was indicated that the prevalence of sterile cysts is higher than the fertile cysts, this is agreement with two studies [20, 23]. While other two studies [19, 33] indicated that the prevalence of the fertile cysts in cattle is higher than of the sterile cysts.

Several studies [19, 33] confirmed that the prevalence of goats infected with fertile cysts is higher than the prevalence of sterile cysts. While [39] stated in his study that the prevalence of sterile cysts in goats was higher than the prevalence of fertile cysts. As for buffaloes, [40] indicated that the prevalence of fertile cysts is higher than the sterile cysts.

The present study showed that all the hydatid cysts were found in male of sheep were hyaline cysts, this is attributed by that most of the males were

slaughtered in young aged. While the female of sheep showed three types of hydatid cysts (hyaline, fibrous and calcified) due to the old age of the slaughtered sheep, which gives a greater opportunity for the immune system to make tissues surrounding the hydatid cysts, which prevent fluids and nutrients in its, and this is lead to turn and increase in density of infection. Many studies of hydatid cyst detected that high levels of immunoglobulin G (IgG) occur in the germinal layer of sterile hydatid cysts. This is may be due to the host immune response that might be a reason of destruction of protoscolec production by inducing apoptosis of germinal layer [41]. The liquid inside the hydatid cysts becomes a thick milky liquid, then after a period of time (depending on the degree of immunity of host) it turns into a calcified cysts, as a result to form fibrous capsule surround the cyst [42, 43]. The fibrous capsule events by local inflammation lead to calcification. This calcification will prevent the food to reaching onto the hydatid cysts, which leads to its death and appearance in form calcified and necrosis cyst [15, 44]. The inner layer of hydatid cysts may grow faster than the peripheral cyst layer, which causes the inner layer to become folded, so that becomes far from the nutrient fluid and decomposes into a gelatinous substance called a matrix, sometimes it may have a psuedotumoral form [45]. The calcified cysts appeared in the livers of males and females of the cattle, this may be to the development of their immune system, as the hydatid cysts located in the liver and lumen are stimulated a hormonal

References

- [1] Konyaev, S.V.; Yanagida, T.; Ivanov, M.V.; Ruppel, V.V.; Sako, Y.; Nakao, M. and Ito, A. (2012). The first report on cystic echinococcosis in a cat caused by *Echinococcus granulosus sensu stricto* (G1). *Journal of Helminthology*, 86: 391-394.
- [2] Thompson, R. C. A. (2017). Biology and systematics of *Echinococcus*. In: Rollinson, D.; Stothard, J. R. (eds.), *Advances in parasitology Echinococcus and Echinococcosis, Part A*. Academic Press, UK: 65-109.
- [3] Baban, M. R. (1990). Epidemiology study of on hydatid disease in Al-Tamim, Diahla and Thiqr. M. Sc. Thesis, College of Education, University of Salahaddin.
- [4] Aziz, A.; Zhang, W.; Li, J.; Loukas, A.; McManus, D. P. and Mulvenna, J. (2011). Proteomic characterisation of *Echinococcus granulosus* hydatid cyst fluid from sheep, cattle and humans. *Journal of Proteomics*, 74(9): 1560-1572.
- [5] Sastry, A. S. and Bhat, S. (2014). *Essentials of medical parasitology*. Jaypee Brothers, Medical Publishers Pvt. Limited.
- [6] Moro, P.L. and Schantz, P.M. (2009). Echinococcosis: a review. *International Journal of Infectious Diseases*, 13(2): 125-133.
- [7] Abdulhameed, M. F.; Robertson, I. D.; Al-Azizz, S. A. and Habib, I. (2019). Neglected zoonosis and the missing opportunities for one health education:

immune response stronger than those cysts in the lungs and other organs [46], or as a result of infected with a different strain other than its original strain, this conditions become unsuitable for the growth of that strain [47]. The hydatid cysts which diagnosed in both goats and buffaloes were hyaline cysts, this may be due to the few numbers of samples were diagnosed from these animals. Many studies have confirmed that the prevalence of calcified cysts in sheep livers is higher than the calcified cysts in their lungs [20, 29]. While many studies indicated that the prevalence calcified cysts in sheep lungs is higher than its livers [32, 33].

The present study showed that the prevalence of calcified cysts in cattle's livers is higher than its lungs, this is agrees with some studies [20, 22, 32]. While [48] confirmed that the prevalence of calcified cysts in the lungs of cattle is higher than the calcified cysts in their livers. It was noticed that all the hydatid cysts which found in goats during the current study were hyaline cysts only, this is agrees with [29]. While other studies [31, 32] indicate that the prevalence of calcified cysts in the lungs of goats is higher than the prevalence of calcified cysts in their livers. As for the prevalence of calcified cysts in buffaloes, the current study showed that no calcified cysts were recorded, this result agrees with [29]. While [40] indicated that the prevalence of calcified cysts in the buffalo's lungs is higher than the prevalence of calcified cysts in its livers.

the case of cystic echinococcosis among surgically operated patients in Basrah, Southern Iraq. *Diseases*, 7(4): 1-10.

- [8] Bingham, G. M.; Larrieu, E.; Uchiumi, L.; Mercapide, C.H.; Mujica, G.; Del Carpio, M.; Hererro, E.; Salvitti, J. C.; Norby, B. and Budke, C. M. (2016). The economic impact of cystic echinococcosis in Rio Negro province, Argentina. *American Journal of Tropical Medicine and Hygiene*, 94(3): 615-625.
- [9] Marquardt, W. C.; Demaree, R. S. and Grieve, R. B. (2000). *Parasitology and Vector biology*. Harcourt Acad. Press, New York.
- [10] Parija S. C. (2004). *Textbook of medical parasitology: protozoology and helminthology*, 2nd edn., Publishers and Distributors, New Delhi, India.
- [11] Al-Nasiri, F. Sh. (2006). Biological and immunological study of hydatid cyst formation in albino mice. Ph.D. Thesis, College of Education Ibn Al-Haitham, University of Baghdad. (In arabic)
- [12] Gemmell, M. A.; Roberts, M. G.; Beard, T. C.; Lawson, J. R. (2001). Quantitative epidemiology and transmission biology with specials reference to *Echinococcus granulosus*. In: Eckert, J., Gemmell, M. A., Meslin, F. X., Pawlowski, Z. S. (Eds.), *WHO/OIE Manual on Echinococcosis in Humans and Animals: A Public Health Problem of Global*

- Concern. World Health Organisation for Animal Health, Paris, ISBN 92-9044-522- X: 143-163.
- [13] Torgerson, P. R. and Budke, C. M. (2003). Echinococcosis-an international public health challenge. *Research in Veterinary Science*, 74: 191-202.
- [14] Pawlowski, Z. S.; Eckert, J.; Vuitton, D. A.; Amman, R. W.; Kern, P.; Craig, P. S.; Dar, K. F.; De Rosa, F.; Filice, C.; Gottstein, B.; Grimm, F.; Macpherson, C. N. L.; Sato, N.; Todorov, T.; Uchino, J.; Von Sinner, W. and Wen, H. (2001). Echinococcosis in humans: Clinical aspects, diagnosis and treatment. In: Eckert, J. ; Gemmell, M. A. ; Meslin, F.-X. and Pawlowski, Z. S. (eds.). WHO/OIE manual on echinococcosis in human and animals: a public health problem of global concern. World organization for animal health and world health organization. Paris and Geneva: 20-71.
- [15] Eckert, J.; Deplazes, P.; Craig, P. S.; Gemmell, M. A.; Gottstein, B.; Heath, D. and Lightowers, M. (2001). Echinococcosis in animals: clinical aspects, diagnosis and treatment. WHO/OIE manual on Echinococcosis in humans and animals: a public health problem of global concern. World Organization for Animal Health, Paris : 799 pp.
- [16] Lahita, R. G. (1999). The role of sex hormones in systemic lupus erythromatosus. current opinion in *Journal of Rheumatology*, 11(5): 352-356.
- [17] Azami, M.; Anvarinejad, M.; Ezatpour, B. and Alirezaei, M. (2013). Prevalence of hydatidosis in slaughtered animals in Iran. *Turkiye Parazitol Derg*, 37(2): 102-106.
- [18] Roostaeei, M.; Fallah, M.; Maghsood, A. H.; Saidijam, M.; Matini, M. (2017). Prevalence and fertility survey of hydatid cyst in slaughtered livestock in Hamadan abattoir, Western Iran, 2015-2016. *Avicenna Journal of Clinical Microbiology and Infection*, 4(2): 1-6.
- [19] Mero, W. M. S.; Jubrael, J. M. S. and Hama, A. A. (2013). Prevalence of hydatid disease among slaughtered animals in Slemani province/ Kurdistan-Iraq. *Journal of University of Zakho*, 1 (2): 1-5.
- [20] Elmajdoub, L. O. and Rahman, W. A. (2015). Prevalence of hydatid cysts in slaughtered animals from different areas of Libya. *Open Journal of Veterinary Medicine*, 5:1-10.
- [21] Aziz, F.; Tasawar, Z.; Lashari, M. H. (2020). Seroprevalence of bovine echinococcosis in Pakistan. *Ciência Rural*, Santa Maria, 50(4): 1-6.
- [22] Kumsa, B. (2019). Cystic echinococcosis in slaughtered cattle at Addis Ababa Abattoir enterprise, Ethiopia. *Journal of Veterinary and Animal Sciences*, 7 (1): 1-5.
- [23] Muqbil, N. A.; Al-salami, O. M. and Arabh, H. A. (2012). Prevalence of unilocular hydatidosis in slaughtered animals in Aden Governorate-Yemen. *Jordan Journal of Biological Sciences*, 5 (2): 121-124.
- [24] Beyhan, Y. E. and Umur, S. (2011). Molecular characterization and prevalence of cystic echinococcosis in slaughtered water buffaloes in Turkey. *Journal of Veterinary Parasitology*, 181: 174-179.
- [25] Pakala, T; Molina, M., and Wu, G. Y. (2016). Hepatic echinococcal cysts. *Journal of clinical and translational hematology*, 4(1): 39-48.
- [26] Ioan, L. M.; Mariana, I. M. W.; Gheorghe, S., and Thomas, R. (2012). Cystic Echinococcosis in Romania: an epidemiological survey of livestock demonstrates the persistence of hyperendemicity. *Foodborne Pathogens Disease*, 9 (11): 980-985.
- [27] Ghosh, S. (2013). Paniker's textbook of medical parasitology. 7th edn. Jaypee Brothers Medical Ltd., India.
- [28] Al-Dujaily, A. H. and Al-Mialy, A. J. (2017). Study the rate of hydatid cysts, liver fluke, pneumonia and hepatitis in Al-Najaf Slaughter House, Al-Najaf, Iraq. *Kufa Journal for Veterinary Medical Sciences*, 8 (2): 137-142.
- [29] Hammad, S. J. (2017). Detection of *Echinococcus granulosus* strains using morphological parameters and molecular methods. Ph.D. Thesis, College of Science, University of Tikrit. Iraq. 48-150.
- [30] Jawad R. A., Sulbi I. M., Jameel Y. J. (2018). Epidemiological study of the prevalence of hydatidosis in ruminants at the Holy City of Karbala, Iraq. *Annals of Parasitology*, 64(3): 211-215.
- [31] Moudgil, A. D.; Asrani, R. K. and Agnihotri, R. K. (2021). Hydatidosis in slaughtered sheep and goats in India: prevalence, genotypic characterization and pathological studies. *Journal of Helminthology*, 94 (27): 1-5.
- [32] Gudeto, G. B. (2020). A study on the prevalence, Distribution and Economic Significance of Echinococcosis/ Hydatidosis in Livestock (Cattle, Sheep, Goats and Pigs) Slaughtered at Addis Ababa Abattoir, Ethiopia. *International Journal of Advanced Research in Biological Sciences*, 7 (11): 135-145.
- [33] Toulah, F. H.; El Shafi, A. A.; Alsolami, M. N. and Wakid, M. H. (2017). Hydatidosis among imported animals in Jeddah, Saudi Arabia. *Journal of Liver and Clinical Research*, 4 (1): 1-5.
- [34] Al-Rishawi, Kh. M. A. (2019). Molecular detection of *Echinococcus granulosus* strains causative of human and some farm animals' hydatidosis in Al-Muthana province. M.Sc. Thesis, College of Education, University of Al-Qadisiyah. Iraq: 137pp.
- [35] Eckert, J. and Deplazes, P. (2004). Biological, epidemiological and clinical aspects of echinococcosis a zoonosis of increasing concern. *Clinical Microbiology Review*, 17(1): 107-135.
- [36] Rahman, W. A.; Elmajdoub, L. E.; Noor, S. A. M. and Wajidi, M. F. (2015). Present status on the taxonomy and morphology of *Echinococcus granulosus*: a review. *Austin Journal of Veterinary Science and Animal Husbandry*, 2(2): 2-5.
- [37] Khan, A. H.; El-Buni, A. A. and Ali, M. Y. (2001). Fertility of the cysts of *Echinococcus granulosus* in domestic herbivores from Benghazi, Libya, and the reactivity of antigens produced from

them. Annals of Tropical Medicine and Parasitology, 95(4): 337-342.

[38] Martínez, C.; Paredes, R.; Stock, R. P.; Saralegui, A.; Andreu, M.; Cabezón, C., and Galanti, N. (2005). Cellular organization and appearance of differentiated structures in developing stages of the parasitic Platyhelminthes *Echinococcus granulosus*. Journal of Cellular Biochemistry, 94 (2): 327-335.

[39] Founta, A.; Chliounakis, S.; Antoniadou-Sotiriadou, K.; Koidou, M. and Bampidis, V. A. (2016). Prevalence of hydatidosis and fertility of hydatid cysts in food animals in Northern Greece. Veterinaria Italiana, 52 (2):123-127.

[40] Rahif R. H. and Al-Fetlawi M. A. A. (2005). Biological Characteristics Of Buffaloes Hydatid Cysts. The Iraqi Journal of Veterinary Medicine, 29 (2): 26-34. (In arabic)

[41] Craig, P.S. and Larrieu, E. (2007). Control of cystic echinococcosis / hydatidosis: 1863–2002. In: Molyneux, D.H. (ed.). Advances in parasitology: control of human parasitic diseases, volume 61. 1st edn., Academic Press, UK: 444-496.

[42] Zhang, W.; Li, J. and McManus, D. P. (2003). Concepts in immunology and diagnosis of hydatid disease. Clinical Microbiology Reviews, 16 (1): 18-36.

[43] Theodorides, Y.; Frydas, S.; Rallis, T.; Adamama-Moraitou, K.; Papazahariadou, R.; Batziou, C. and Conti, P. (2001). MCP-1 and MIP-2 levels during *Echinococcus granulosus* infections in mice. Journal of Helminthology, 75: 205- 208.

[44] Vuitton, D.A. (2003). The ambiguous role of immunity in echinococcosis: protection of the host or of the parasite?. Acta Tropica, 85: 119 - 132.

[45] Lewall, D.B. (1998). Hydatid Disease: Biology, Pathology, Imaging and Classification. Clinical Radiology, 52: 863-874.

[46] Kebede N.; Mitiku A. and Tilahun G. (2009). Echinococcosis of slaughtered animals in Bahir Dar Abattoir, Northwestern Ethiopia. Tropical Animal Health and Production, 41: 43-50.

[47] Rosenzvit, M. C.; Zhang, L. H.; Kamenetzky, L.; Canova, S. G.; Guarnera, E. A. and McManus, D. P. (1999). Genetic variation and epidemiology of *Echinococcus granulosus* in Argentina. Journal of Parasitology, 118: 523-530.

[48] Shahnazi, M.; Jafari, A.; Javadi, M. and Saraei, M. (2013). Fertility of Hydatid Cysts and Viability of Protoscoleces in Slaughtered Animals in Qazvin, Iranian Journal of Agriculture Science, 5 (1): 141-146.

الكشف عن الإصابة بداء الاكياس المائية في حيوانات المسالخ في محافظة كركوك، العراق

رائد صباح رضوان ، فاطمة شهاب الناصري

قسم علوم الحياة ، كلية العلوم ، جامعة تكريت ، تكريت ، العراق

الملخص

اجريت الدراسة الحالية خلال المدة من شهر ايلول 2020 ولغاية شهر شباط 2021، لتحديد نسبة الإصابة بداء الاكياس المائية في الاعضاء المختلفة لحيوانات المسالخ (الضأن، الابقار، الماعز، الجاموس) في محافظة كركوك وضواحيها. استخدم الفحص البصري والجس باليد في كشف وتحديد موقع الإصابة بالأكياس المائية، فضلا عن الفحص المجهرى لتحديد خصوبة تلك الاكياس المائية.

تم فحص 4122 عينة من حيوانات المسالخ والتي تضمنت 1860 عينة ضأن، 1550 عينة ابقار، 680 عينة ماعز، و 32 عينة جاموس. شخصت الإصابة بالأكياس المائية في 133 عينة (42 ضأن، 83 ابقار، 6 ماعز، 2 جاموس)، وقد بلغت نسبة الإصابة الكلية 2.25% و 5.35% و 0.88% و 6.25% في الضأن والابقار والماعز والجاموس، على التوالي. لوحظ ارتفاع نسبة الإصابة في اناث حيوانات المسالخ مقارنة مع نسبة الإصابة في ذكورها، حيث كانت الإصابة في الذكور والاناث 0.48%، 1.77% في الضأن؛ 1.48%، 3.87% في الابقار؛ 0.29%، 0.58% في الماعز، على التوالي. بينما سجلت نسبة إصابة مقدارها 6.25% في اناث الجاموس مقارنة مع ذكورها التي لم تسجل فيها اية إصابة.

تشير النتائج الى ان الكبد اكثر اعضاء جسم الحيوان تعرضا للإصابة بالأكياس المائية، اذ سجلت نسب إصابة مقدارها 63.63% و 44.44% في الضأن، 46.66% و 65.21% في الابقار، 50.00% و 50.00% في الماعز، 0.00% و 50.00% في الجاموس ولكل من اكياد الذكور والاناث، على التوالي. وفيما يتعلق بخصوبة الأكياس المائية في حيوانات المسالخ، فان الإصابة بالأكياس المائية الخصبة قد ارتفعت نسبتها في اكياد اناث الضأن (80.95%) مقارنة مع بقية اصابات حيوانات المجازر، بينما لوحظ ان اعلى نسبة إصابة بالأكياس المائية العقيمة في رثات اناث الابقار (93.33%). فضلا عن ذلك، فقد لوحظ ان اغلب حالات الإصابة بالأكياس المائية المتكلسة قد سجلت في رثات اناث الضأن (50.00%)، واكياد اناث الابقار (32.14%).