



## Dioraleze Drug-induced Kidney Injury In Rats

Asraa Abed Thiyab

Department of Biology , College of Education for Pure Sciences , Tikrit University, Tikrit , Iraq

DOI: <http://dx.doi.org/10.25130/tjps.25.2020.063>

### ARTICLE INFO.

#### Article history:

-Received: 5 / 9 / 2019

-Accepted: 3 / 10 / 2019

-Available online: / / 2020

**Keywords:** Interstop, Dioraleze, Anti-Diarrhea.

#### Corresponding Author:

**Name:** Asraa Abed Thiyab

**E-mail:** [esraa.abed@tu.edu.iq](mailto:esraa.abed@tu.edu.iq)

**Tel:**

### ABSTRACT

The present study was designed to find out the effects of Dioraleze administered orally on the kidney.

In this study the experiment was designed using twenty Rats from both sexes and randomly distributed into three main groups as following:

**Group 1 (Control):** Distilled Water was administered orally on a daily basis for three weeks.

**Group 2 (Treatment):** 1mg/kg body weight Dioraleze was administered orally on a daily basis for three weeks.

**Group 3 (Overdose):** orally given 2.5mg/kg body weight Dioraleze daily for three weeks.

At the end of the experimental period Rats were taken out and dissected for histological examination and processing. Kidney tissue was examined for any abnormalities.

Drug-induced kidney disease is usually a result of a drug or metabolites that could affect the cell and tissue biochemistry directly or result in an immune response which was found in this study as the occurrence of several vascular sacs directly attached to the liver in all rats present in group 2 and 3. The sac ranged in size from 0.5 cm-1 cm compared to group 1 which showed the lack of any sacs.

Kidney in both therapeutic and Overdose group illustrated many abnormalities after treatment period when compared to Control. Some of these alterations in tissue and organ such as renal cortex degeneration, atrophy of proximal convoluted tubule that led to necrosis, blood congestion and hypertrophy was also present in the Glomerulus of treated Rats.

Renal medulla, however illustrated atrophy of the proximal convoluted tubules, degeneration of renal tubule epithelial cells and ultimately their shrinkage leading to a small lumen in addition to the pyknosis of nuclei.

Kidney examination revealed Dioraleze's significant impact on the renal cortex and medulla in addition to its effect of other parts of kidney tissue. Thus, it was concluded that Dioraleze caused kidney abnormalities that may lead to kidney dysfunction in the body and may also have great impact on other visceral organs if not taken as per dose.

### Introduction

Dioraleze (Interstop) is a widely used antidiarrheal medication all over the world. Dioraleze action is based on a number of various mechanisms that decrease peristalsis and fluid secretion, eventually leading to a longer gastrointestinal transit time and a higher level of absorption from the gastrointestinal tract.

Dioraleze was made in 1969 but used as a drug in 1976. It is considered as one of the most Essential Medicines. [1].

Dioraleze It is a phenylpiperidine derivative that resembles opiate receptor agonists (diphenoxylate and haloperidol) in their chemical structure. Dioraleze has a low oral absorption and rapid metabolic/diffusion through the blood-brain barrier (CNS), which reduces its negative effect on the

central nervous system if given according to the recommended dose but that does not exclude its abuse. Several research showed that overdose may lead to CNS Toxicity. Common side reactions to Dioraleze include abdominal cramps, nausea, constipation and dizziness [2].

Dioraleze is present as 2 mg capsules with recommended dosage depending on specific condition, age and weight of patient. Dioraleze is broken down by the liver. Various Studies on this drug in illustrated a high affinity for the gut wall with a binding preference to receptors of the longitudinal muscle layer [3].

This study aims to study the effect of Dioraleze (Interstop) administration on kidney when given in different doses.

**Materials and Methods**

**Table 1: Material and Equipment used.**

Materials	Instruments
Ethanol	Different sized Beakers
Chloroform	Microtome
Paraffin Wax	Oven 57° C
D.P.X	Water Bath
H&E Stains	Filter Paper
Xylene	Microscope
Dioraleze capsules	Blocks and Hot Plate
Distilled water & Tab Water	Glasses, Slides
Normal Saline	Microscope Attached Camera
Mayer's glycerol-albumin	Dissecting kit

**Experimental Animals**

Twenty adult rat were obtained from the University of Tikrit Animals House. Rats were put in special cages (3 animal per cage) and fed pellet rodent diet in addition to water. Housing was organized comfortably enough to ensure a fixed night/light timing with ventilation system to ensure the elimination of any environmental stress.

**Groups Organization**

**Group 1 (Control):** 4 Rats orally administered with 1ml distilled water for 3 weeks.

**Group 2 (Therapeutic Dose):** 8 Rats orally administered with 1 mg/kg of Dioraleze for 3 weeks [3].

**Group 3 (Overdose Group):** 8 Rats orally administered with 2.5mg/kg of Dioraleze for 3 weeks.

**Experimental Design**

Rats were divided randomly into three groups, all were given the drug after dissolving it in 1ml distilled water and given orally. Dioraleze was given orally twice a day using insulin needle and melted in distilled water to ensure the drug is taken.

After the experiment period, rats were killed by chloroform put on a cotton ball kept in a closed chamber. Dissecting technique and processed was according to Bancroft& Stevens 1987 as follows:

a) Fixation of the kidney using 10% neutral buffered formalin for about 24 hours at room temperature.

b) Dehydration of organ tissues obtained went through progressive graded concentrations of alcohol baths (30%, 50%, 70%, 80%, 90%, 100%).

c) Clearing using Xylene to ensure that the tissues are transparent enough for staining. Clearing for about 20 minutes twice.

d) Infiltration and Embedding using paraffin wax Melton in special ovens twice (57-58° C) for 25 minutes to ensure the removal of xylene. T shaped containers were used to embed the tissues.

e) Tissue sectioning using Rotary Microtome at 6-7 Mm then we transfer the thin ribbons of thinly cut tissue-wax into a 44° C water bath.

f) Tissue Attachment was by using Mayer's glycerol-albumin mixture that allows the ribbons to attach onto the slide firmly for staining.

g) De-waxing and Hydration which is done by Xylene baths to ensure the removal of excess was then hydration is done by inserting the slides in descending concentration of alcohol baths (100%, 90%, 80%, 70%, 50%, 30%).

h) Staining using regular Heamatoxylin and Eosin (H & E). (Indian)

i) Mounting with D.P.X before Light Microscope examination. Pictures were taken on 40X by Multiple Power Microscope with computer screen. (4)

**Results**

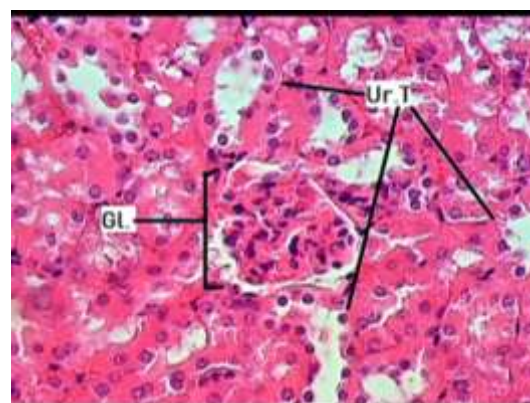
**Gross Pathology**

External Color of some patches on the kidney in groups 2&3 change was observed, it appeared white and rough/thick compared to Group 1. visceral sacs (0.5-1 cm) was found attached to the outer layer of the liver in the Therapeutic/Overdose Group. Kidney seemed to have no change in size compared to the control group.

**Histopathology**

**Group1 : Control**

Figure 1 showing a well-defined Glomerulus with well aligned structure in both Glomerulus and the urinary yubule. Both proximal convoluted tubule and the distal convoluted tubule are well shaped.

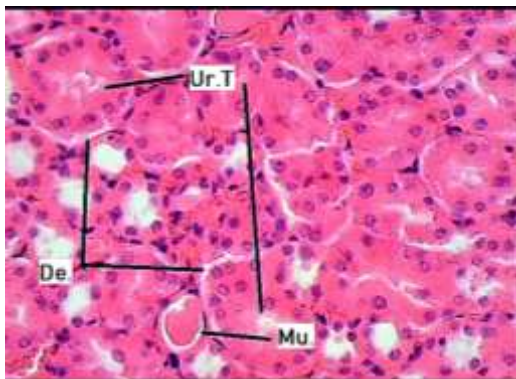


**Fig. 1: Photomicrograph of Normal Kidney showing Urinary Tubule (Ur.T) and Glomerulosa (Gl.). (H&E 40X)**

**Group 2 : Therapeutic Dose:**

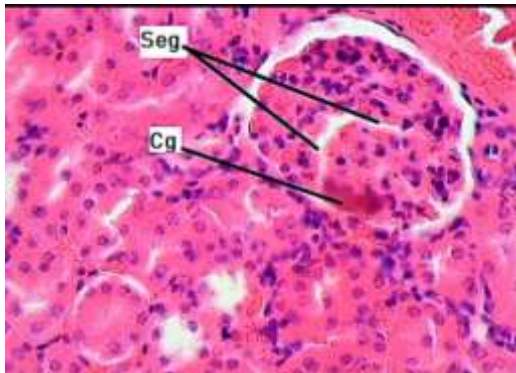
Central Cavity shows enlargement of cells while other parts of the tissue (which includes the urinary

tubules and cells) appear normal in shape and arrangement. However, desquamation in parts of the cells lining the urinary tubules can also be seen in Figure 2.



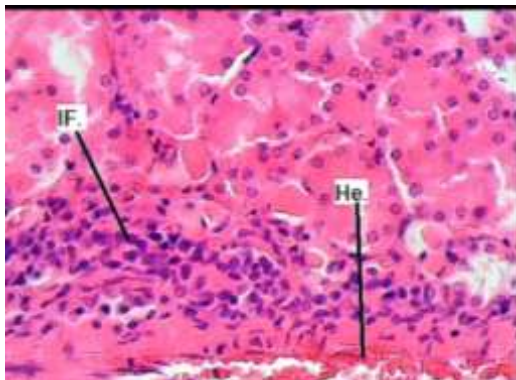
**Fig. 2: Photomicrograph of Therapeutic Kidney showing Urinary Tubule (Ur.T), Presence of Mucous Substance (Mu.) and Desquamation (De.) . (H&E 40X)**

Figure 3 shows congestion near the glomerulus while appearing to be segmented.



**Fig. 3: Photomicrograph of Therapeutic Kidney showing Congestion (Cg), Segmented Glomerulosa (Seg) . (H&E 40X)**

Mild Hemorrhage between urinary tubules is found with the formation of Inflammatory cells in the tissue of Rats treated with therapeutic dose. Figure 4.

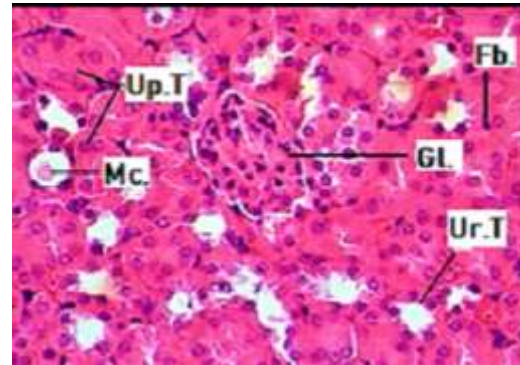


**Figure 4: Photomicrograph of Therapeutic Kidney showing Lymphocyte Infiltration (IF.) and Hemorrhage Congestion (He.) . (H&E 40X)**

**Group 3 : Overdose Group**

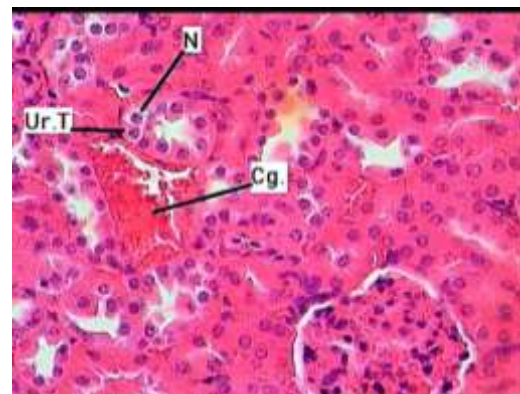
Figure 5 shows the enlargement of cells lining the Urinary tubules which caused the decrease in size of the urinary tubule cavity in some parts and the total

block (closure) of other parts. This figure also shows the massive impact of this drug on urinary cells leading to Cytoplasmic and Nuclei necrosis, enlargement of the nuclei and unclear Chromatin Matter). The Glomerulus also went through atrophy with the presence of congestion between the Urinary Tubules.



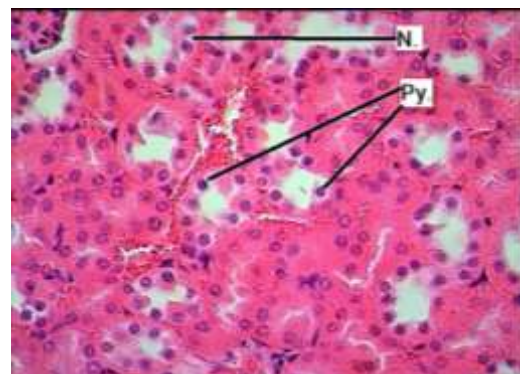
**Figure 5: Photomicrograph of Overdose Kidney showing Glomerulus Atrophy (Gl.), presence of Fibrocyte (Fb.) Mucous Substance (Mc.), Urinary Tract (UT) and Closed Uniphrous Tubule (Up.T). (H&E 40X)**

Urinary Tubule cells underwent partial necrosis showing altered cell form with the formation of blood congestion between Kidney Tubules. Figure 6



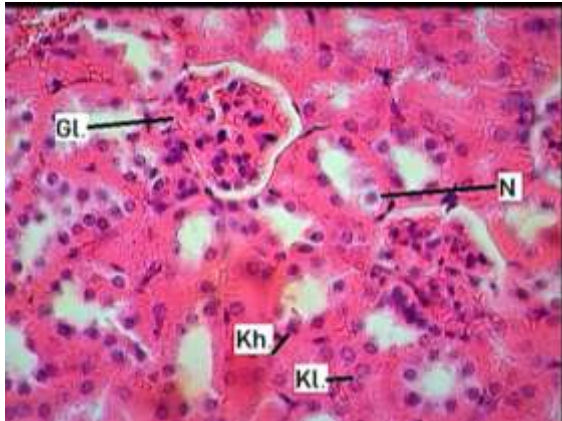
**Fig. 6: Photomicrograph of Overdose Kidney showing Blood Congestion (Cg.), Urinary Tubule Altered Cells (Ut.T), Necrosis of Cells (N) . (H&E 40X)**

Pyknosis of cells is seen in Figure 7 with the signs of Necrosis seen which includes the separation of parts of the cells lining the urinary tubules.



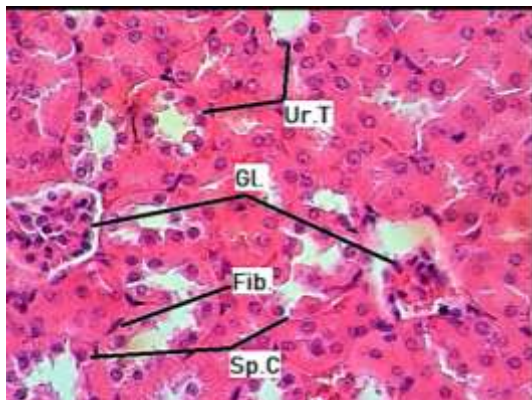
**Fig. 7: Photomicrograph of Overdose Kidney showing Pyknosis of cells (Py.), Necrosis (N.). (H&E 40X)**

Figure 8 shows how the Renal Tubule went through Desquamation and segregation from its basement membrane causing its aggregation in the center of the tubules while Segmentation in parts of the Glomerulus was seen. Karyolysis and Karyorrhexis was also found. These Cells are from different stages of degradation.



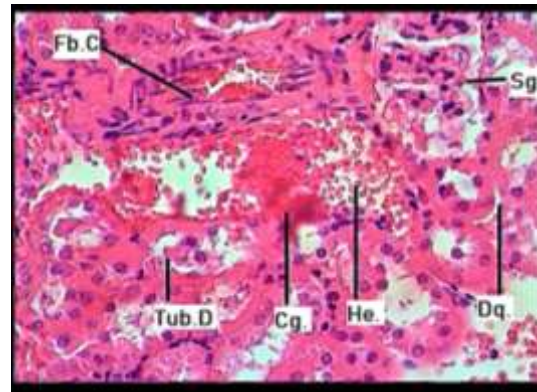
**Fig. 8: Photomicrograph of Overdose Kidney showing atrophy of Glomerulus (Gl.), Necrosis (N), Karyorrhexis (Kh.), Karyolysis (Kl.). (H&E 40X)**

Figure 9 shows Complete Cellular Necrosis of the Renal Tubules cells in and the atrophy of the Glomerulus leading to the formation of blood congestion.



**Fig. 9: Photomicrograph of Overdose Kidney showing atrophy of Glomerulus (Gl.), Urinary Tubule (Ur.T), Separated Cells (Sp.C) and Fibrocyte (Fib.). (H&E 40X)**

Figure 10 demonstrated how sever the Hemorrhage in between Urinary Tubules was due to high dose of the drug given to the mouse with the Red Blood Cell lysis leading to Congestion.



**Fig. 10: Photomicrograph of Overdose Kidney showing Fibrocyte (Fb.C), Desquamation (Dq.), Segmented glomerulus (Sg), Blood Congestion (Cg.), Hemorrhage (He.), Damaged Tubule (Tub.D). (H&E 40X)**

**Discussion**

Dioraleze is a medication used to decrease diarrhea in the body, most frequently used in gastroenteritis, inflammatory bowel disease, and short bowel syndrome.

In rare cases this drug may cause side effects that include toxic megacolon, paralytic ileus, angioedema, anaphylaxis/allergic reactions, toxic epidermal necrolysis, Stevens-Johnson syndrome, erythema multiform, urinary retention, and heart stroke. while High doses may result in heart problems such as abnormal heart rhythms [5]. The various effects that is caused due to this drug helps understand how sever and broad effect this drug has on multiple organs.

General observations on the studied rats includes change behavior such as withdrawal activity, depressed and less active behavior when compared to rats in the control group with increase in overall breathing of group3 given Overdose Group. These observations were in agreement with (McNeil.2016), Regarding patients drug abuse resulting in sudden death, ventricular arrhythmias and cardiac arrest, illustrating its various negative effects on the cardiac tissue. This study also reports severe cases of cardiac arrest and respiratory depression in younger patients under 3 years old. (Julia, 2015) also shows similar reports regarding a 25 year old women complaining from abdominal pain, sinus rhythm, intra-ventricular conduction defect and acute respiratory failure for many weeks and claims she has no drug abuse of any kind. After several tests and toxicology close study the findings showed elevated blood Dioraleze (similar component) level of 32 ng/mL and drug abuse [6,7]. Other reports by the (CNITV) on the Toxic effect of Extra-theraoetic Dose of similar substance such as Dioraleze that was in agreement with this study done by (Hugnet *et al.*, 1996) showing 13episodes of canine poisoning in dogs by Diorlaleze similar substance (Loperamise) out of 30. the average dose was 0.9 mg/kg. all dogs were treated but some went through severe coma and respiratory distress naloxone [8].

Very few research was found on the effect of Dioraleze on Kidney. However, overall observations

found in this for Rats treated with Overdose group resulted in the death of 1 rat after two weeks of oral dosage concluding it's lethal effect when given higher doses. We can conclude the drugs effect causing an endo-toxic effect that led to necrosis of cells in the Tissues and organs effecting its overall activity and function. **Conclusion:**

#### References

- [1] Baker, D.E. (2007). Loperamide: a pharmacological review. Rev Gastroenterol Disord.  
 [2] Hughes A., Chai-Chi Chan B., Valento M., 2018. Severe loperamide toxicity associated with the use of cimetidine to potentiate the "high". Volume 36, Issue 8, Pages 1527.e3–1527.e5, The American Journal of Emergency Medicine  
 [3] Riviere J., Papich M., Adams H., (2011). Veterinary Pharmacology and Therapeutics. (9<sup>th</sup> ed.) WILEY-BLACK WELL, A John Wiley & Sons, Inc., Publication. USA.  
 [4] J. D. Bancroft, (1990). Theory and practice of histological techniques, 3rd ed. A. Stevens (Eds). Churchill Livingstone, Edinburgh, European Journal of Pharmaceutical Sciences, Volume 20, Issue 3, Pages 357-363

Interstop (Dioraleze) is an over-the-counter capsule that is seen as a safe drug with no fatal side effects. However after several research this drug should be taken with caution according to age and condition of treatment. Further study on its lethal effect is encouraged due to the lack of histopathological research found so far.

- [5] Florey, Klaus (1991). Profiles of Drug Substances, Excipients and Related Methodology, Volume 19. Academic Press. p. 342. ISBN 9780080861142.  
 [6] Use Immodium, (2016). Johnson & Johnson Consumer Inc. McNeil Consumer Healthcare Division Rx, USA U.S. 3, 714,159  
 [7] Julia H, Evbu O, Irbaz B., Fashad M., Yuval Raz, (2015). The Long Q Teaser: Loperamide Abuse. University of Arizona. The American Journal of Medicine.  
 [8] Loperamide Poisoning in The Dog. (1996). C hugnet, JL Cadore, T Mathete. Toxicology Veterinary Centre. France.

## تسمم وتضرر خلايا الكلى نتيجة استعمال دواء الانترستوب (Dioreleze) في الجرذان

اسراء عبد ذياب جزاع

قسم علوم الحياة ، كلية التربية للعلوم الصرفة ، جامعة تكريت ، تكريت ، العراق

#### الملخص

تم تصميم هذه الدراسة لمعرفة تأثير دواء الديوراليز كدواء مضاد للإسهال على الكلية حيث تم استخدام عشرون جرذاً من كلا الجنسين حيث تم تصنيفهم عشوائياً إلى ثلاث مجاميع رئيسية كالآتي:  
**مجموعة 1 (مجموعة السيطرة):** تم إعطاء الجرذ الماء عن طريق الفم يومياً لمدة 3 أسابيع.  
**مجموعة 2 (الجرعة العلاجية):** تم إعطاء الجرذ 1 مغ/كغ من الدواء عن طريق الفم يومياً لمدة 3 أسابيع.  
**مجموعة 3 (الجرعة العلاجية الزائدة):** تم إعطاء الجرذ 2.5 مغ/كغ من الدواء عن طريق الفم يومياً لمدة 3 أسابيع.  
 في نهاية المدة المحددة للتجربة تم تشريح الجرذان مباشرة لاستئصال الكلية من أجل دراستها نسيجياً لأي اختلافات وتغييرات نسيجية. أظهرت نتائج الدراسة علي تغييرات كبيرة في نسيج الكلية في كل من المجموعة العلاجية والعلاجية الزائدة حيث تم ملاحظة تحلل لخلايا النبيبات بالإضافة إلى موت الخلايا وتحللها، وجود ارتشاح في الخلايا اللمفاوية، احتقان وتخر في العديد من الخلايا.  
 نستنتج هنا أن دواء الديوراليز له تأثير سلبي كبير علي القشرة الخارجية والداخلية للكلية بالإضافة إلي أجزاء أخرى من الكلية مما أدى إلي حدوث تغييرات غير طبيعية في العضو مما يظهر لنا ما قد ينتج عن استخدام هذا الدواء من غير رقابة ومعاينة طبية.